



Treatment of subtrochanteric nonunion of the femur: whether to leave or to exchange the previous hardware

Soo Hwan KANG, Suk Ku HAN, Yong Sik KIM, Myung Jin KIM

Department of Orthopedic Surgery, St. Paul's Hospital, College of Medicine, The Catholic University of Korea, Seoul, South Korea

Objective: Our aim was to compare the clinical results of two different methods for treatment of subtrochanteric nonunion: an additional fixation to the previous hardware, and exchange of previous hardware.

Methods: We retrospectively analyzed 19 cases of subtrochanteric nonunion, and compared clinical results from 10 cases (Group 1) with exchange of the previous hardware, and 9 cases (Group 2) with retained previous hardware and an additional fixation. Autogenous bone grafting were performed for all cases. The mean age of the patients was 49.1 years in Group 1, and 48.2 years in Group 2. The mean follow-up period was 19.3 months.

Results: The union rate was 100% in Group 1, and 77.8% in Group 2 ($p < 0.05$). The average time of union was 7.6 months in Group 1, and 6.9 months in Group 2. The mean preoperative leg length discrepancy (LLD) was 8.3 mm in Group 1, 10.0 mm in Group 2; and the mean final LLD was 13.9 mm in Group 1, and 11.2 mm in Group 2. The mean length of hospital stay was 23.8 ± 3.3 days in Group 1, and 18.2 ± 2.7 days in Group 2; the mean amount of blood transfusion was 960 ml in Group 1, and 647 ml in Group 2; and the mean operative time was 3.7 ± 0.8 hrs in Group 1, and 2.7 ± 0.6 hrs in Group 2 ($p < 0.05$).

Conclusion: The union rate in patients with exchange of the previous hardware was better than in those with retained hardware in the treatment of subtrochanteric nonunion by complete removal of the interposed fibrous tissue and meticulous bone grafting leading to a biological environment to achieve bony union.

Key words: Femur; previous hardware; subtrochanteric nonunion.

Subtrochanteric fractures of the femur are defined as a fracture with extension into the region between the inferior border of the lesser trochanter and a line 5 cm distal to it. These fractures tend to be associated with high-energy trauma in younger patients, and poor bone stock due to metastatic or osteoporotic conditions in the elderly. Anatomically, the subtrochanteric region of the femur is composed of a hard cortical bone with scarce blood supply, which requires long time for

bony union. Biomechanically, the varus stress is exerted to the fracture site during weight bearing, and the medial cortical bone is vulnerable to comminuted fracture. The fracture is excessively displaced by powerful adjacent muscles, making the reduction and maintenance difficult to achieve.^[1,2] Therefore, problems such as varus deformity, delayed union or nonunion, metallic failure or shortening of the lower limb occur more prevalently in subtrochanteric fracture of the femur.^[3-7]

Correspondence: Soo Hwan Kang, MD. Department of Orthopedic Surgery, St. Paul's Hospital College of Medicine, The Catholic University of Korea, Seoul, South Korea.

Tel: 82-2-965-1456 e-mail: gamjang@medimail.co.kr

Submitted: April 13, 2012 **Accepted:** October 10, 2012

©2013 Turkish Association of Orthopaedics and Traumatology

Available online at
www.aott.org.tr
doi:10.3944/AOTT.2013.2887
QR (Quick Response) Code:



There are several factors responsible for subtrochanteric nonunion of the femur following fracture surgery; loss of initial fixation, deformity, infection, breakage of the implant and bone loss. The incidence of subtrochanteric nonunion varies with type of the internal fixation device.^[4,5,8] The type of nonunion, site of fracture, size and location of bony fragments, severity of bone defect and bone quality can affect the choice of internal fixation hardware.^[9] In the treatment of subtrochanteric nonunion, a variety of implants have been used with variable success, including intramedullary nailing (gamma nail,^[10] reconstruction nail^[11] or interlocking nail^[12]) and plating (dynamic condylar screw, 95° blade plate^[7,13]). In addition, bone grafting with autogenous or allogenic bone is also used selectively to treat patients.^[14,15]

When treating subtrochanteric nonunions, it is widely known that previous hardware removal, complete decortication and removal of the fibrotic tissue from the nonunion site should be done with selective bone grafting. It should also be accompanied by correction of the deformity using the internal fixation device to achieve rigid fixation.^[10-14] However, we questioned whether re-fixation with a new device could increase stability of the fracture compared to retaining the previous hardware plus an additional fixation, considering the anatomical characteristics of the subtrochanteric region. In addition, if the previous hardware could be replaced with a new one, there would be several problems such as a longer operation time, chances of secondary infection and a high cost-effectiveness. We retrospectively compared the clinical results of two different methods for treatment of subtrochanteric nonunion where one had a new internal fixation device inserted following removal of the previous hardware, and the other had an additional fixation, retaining the previous hardware.

Patients and methods

From February 2005 to December 2009, 21 patients with subtrochanteric nonunion were surgically treated at our medical institution, and 19 patients with follow-up for at least one year were enrolled in the study. Nonunion was defined as the absence of radiographic improvement of bony union more than six months postoperatively. We excluded all cases of nonunion due to pathological fracture, periprosthetic fracture or infections, but we included two patients with a prior history of infection. In all cases, the causes of nonunion included a bone loss due to comminuted fracture or infection and an inadequate bony contact. In ten out of 19 (Group 1), when there was a failure in the previous retaining surgery, reduction loss or metallic failure, significant

shortening or large bone defects, we performed plating or intramedullary nailing after removal of the previous hardware with autogenous bone graft. In nine cases (Group 2), when there was a small bony defect or none of the above mentioned indications, additional fixation of the plate or wiring was done with autogenous bone graft by retaining the previous hardware. All surgical procedures were performed by a single operator (SKH). The previous hardwares included the interlocking intramedullary nail (four cases), cephalomedullary nail (one case), reconstruction nail (three cases), compression hip screw (one case) and blade plate (one case) in Group 1, and the intramedullary nail (four cases), reconstruction nail (three cases) and compression hip screw (two cases) in Group 2.

Patients' data are given in Table 1. The mean age of the patients was 49.1 (range: 33-78) years in the Group 1 and 48.2 years (range: 26-70) in the Group 2. Male patients were predominant in both groups (8 in Group 1, and 8 in Group 2). The mean postoperative follow-up period was 19.3 (range: 14 to 37) months. According to the Seinsheimer's classification of subtrochanteric fractures, there were 3 Type IIa, 2 Type IIb, 2 Type IIc, 2 Type IIIa and 1 Type IV fractures in Group I while in Group II, there were 2 Type IIa, 2 Type IIb, 3 Type IIc, 1 Type IIIa and 1 Type IV fractures. The average time between the last operation and the injury was 12.8 months in Group 1, and 10.9 months in Group 2. Besides, surgery was performed at a mean frequency of 1.9 times in Group 1 and 1.8 times in Group 2. In Group 1, the previous hardware was removed, and a new device was used for fixation (interlocking intramedullary nail in three cases, cephalomedullary nail in two, compression hip screw in two and double plate in three). In Group 2 with retained hardware, either a wire (three cases) or plate (four cases) was used for additional fixation or only autogenous bone grafting (two cases) was performed.

All surgical procedures were performed under general anesthesia, and autogenous bone grafting was performed after fibrotic tissue was removed as maximally as possible. The timing of weight bearing was 5.4 weeks in Group 1 and 4.7 weeks in Group 2.

Results

Bone union was achieved in ten patients (100%) in Group 1 in which a nail or plate were refixed with the autogenous bone graft after removal of the previous hardware (Fig. 1), and seven patients (77.87%) in Group 2 in which an additional fixation with a plate or wire was performed together with autogenous bone grafting by retaining the previous hardware ($p < 0.05$).

Bone union was achieved during a mean period of 7.6 months in Group 1 and 6.9 months in Group 2. In two patients who had failure in bone union (Fig. 2), a dynamic compression hip screw and double plates were fixed again following removal of the previous hardware, respectively. There were no patients who developed secondary infection or nerve palsy. The mean preoperative leg length discrepancy was 8.3 (range: 3 to 18) mm in Group 1 and 10.0 (range: 2 to 17) mm in Group 2 while the mean final leg length discrepancy (LLD) was 13.9 (range: 4 to 28) mm in Group 1 and 11.2 (range: 4 to 18) mm in Group 2. The mean length of hospital stay was 23.8±3.3 days in Group 1 and 18.2±2.7 days in Group 2 (p<0.05). The mean amount of blood transfusion was 960 (range: 0 to 2240) ml in Group 1 and 647 (range: 0 to 1920) ml in Group 2 (p<0.05). The mean operative time was 3.7±0.8 hrs in Group 1 and 2.7±0.6 hrs in Group 2 (p<0.05).

Discussion

The incidence of subtrochanteric nonunion has been reported to be approximately 4-20%, varying by types of internal fixation device and treatment method.^[1,4,5] The causes of nonunion include interfragmentary motion due to failure of rigid fixation, interposition of the fibrous tissue at the fracture site, and malposition of bony fragments by inappropriate reduction or comminution.^[3,13,16] Despite these difficulties, a variety of implants have been used with variable success including intramedullary nailing and plating system. Revision internal fixation and selected bone grafting for subtrochanteric nonunion led to a high rate of union, and intramedullary devices with fixation into the femoral head and neck and fixed angled devices were effective in achieving stable fixation of the proximal bony fragment.^[14]

For treatment of subtrochanteric nonunion, treatment principles are previous hardware removal, complete decortication, removal of the fibrotic tissue from the nonunion site, selective bone graft and stable fixation with a new plate or nail. However, we questioned whether the previous hardware should be removed. Since there was no established criteria as to whether to maintain or remove the previous hardware as far as we know, we retrospectively compared the clinical results of two different methods where one had a new internal fixation device inserted following removal of the previous hardware (Group 1), and the other had an additional fixation, retaining the previous hardware (Group 2).

In our series, we decided whether to leave or exchange the previous implant, and what implant

Table 1. Data for individual patients.

Case No.	Group	Age/Sex	OTA classification 32	Nonunion type	Previous operation times	Previously inserted implant	Authors' treatment	Time to injury (months)	Time to union (months)	Final LLD (mm)
1	1	49/M	B3	A	2*	Blade plate	Dual plating + AIBG	17	10	28
2	1	44/M	A2	A	1	DCHS	Cephalomedullary nailing + AIBG	11	7	6
3	1	33/M	C3	A	3	Reconstruction nail	Dual plating + AIBG	26	9	18
4	1	55/F	A2	A	2	IL nail	Exchange nailing + AIBG	9	6	4
5	1	46/M	A3	A	2	Reconstruction nail	Exchange nailing + AIBG	7	8	12
6	1	78/M	C3	A	1	Cephalomedullary nail	Dual plating + AIBG	7	8	8
7	1	44/M	A3	A	2	Reconstruction nail	DCHS + AIBG	11	5	16
8	1	56/F	A3	H	1	IL nail	Exchange nailing + AIBG	8	6	12
9	1	39/M	C3	A	3	IL nail	Cephalomedullary nailing + AIBG	19	9	15
10	1	47/M	A3	A	2	IL nail	DCHS + AIBG	13	8	20
11	2	26/M	A3	A	2	IL nail	Additional plating + AIBG	6	7	7
12	2	29/M	C3	A	1	IL nail	Wiring + AIBG	6	6	6
13	2	48/F	A2	A	2	IL nail	Additional plating + AIBG	14	7	18
14	2	32/M	A2	A	2	Reconstruction nail	Additional plating + AIBG	8	nonunion	17
15	2	56/M	A3	A	1	DCHS	AIBG	7	6	4
16	2	70/M	B3	A	1	Reconstruction nail	Wiring + AIBG	6	nonunion	6
17	2	55/M	A2	A	3*	IL nail	Wiring + AIBG	24	10	18
18	2	61/M	A2	A	2	DCHS	AIBG	12	5	14
19	2	57/M	A3	A	2	Reconstruction nail	Additional plating + AIBG	15	7	11

*Previous infection, A: atrophic, AIBG: autogenous iliac bone graft, DCHS: dynamic compression hip screw, Dual plating: DCS + LCDPCP (limited contact dynamic compression plate) or 2 LCDPCP, H: hypertrophic, IL: nail: interlocking nail, LLD: leg length discrepancy

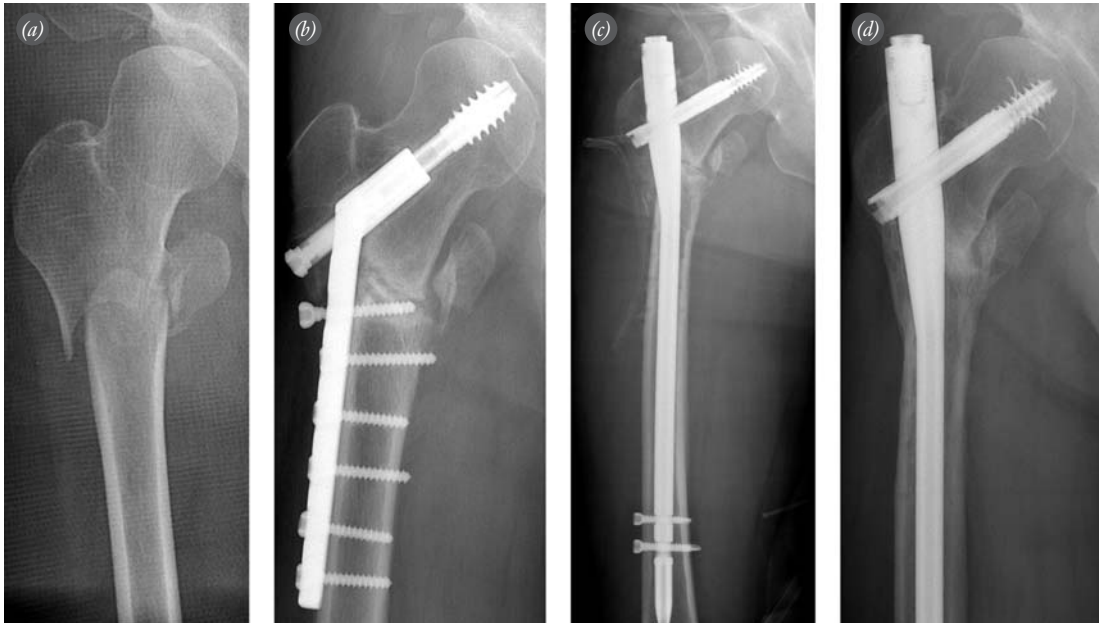

Fig. 1. Antero-posterior view of a subtrochanteric fracture **(a)** in a 44-year-old male patient involved in a traffic-accident. Antero-posterior radiograph **(b)** shows atrophic nonunion 11 months after internal fixation with a CHS. **(c)** CHS was removed and a cephalomedullary nail was applied with autogenous bone graft. **(d)** Radiograph shows a union 6 months after the revision.

would be exchanged in treatment of subtrochanteric nonunion by our criteria. In case of failure in the previous retaining surgery, reduction loss of metallic failure, significant shortening or large bone defect, we exchanged the previous hardware. On the other hand, when the bony defect was small or there were none of the above mentioned indications, we tried to retain the implant. As already known, the most optimal device for treatment of subtrochanteric nonunion has not been defined yet. We decided the type of implant to be used

in revision surgery of the exchange group as follows: First, when the intramedullary nail could not fill the canal, we exchanged it to a larger sized nail after additional reaming. Second, in case of any failure in the surgery with previous hardware, we exchanged the implant to plate system. In case of reduction loss or broken nail, the choice of nail system was preferred. Also, when the fracture site was proximal, a single or double plating was chosen for secure fixation rather than nailing.

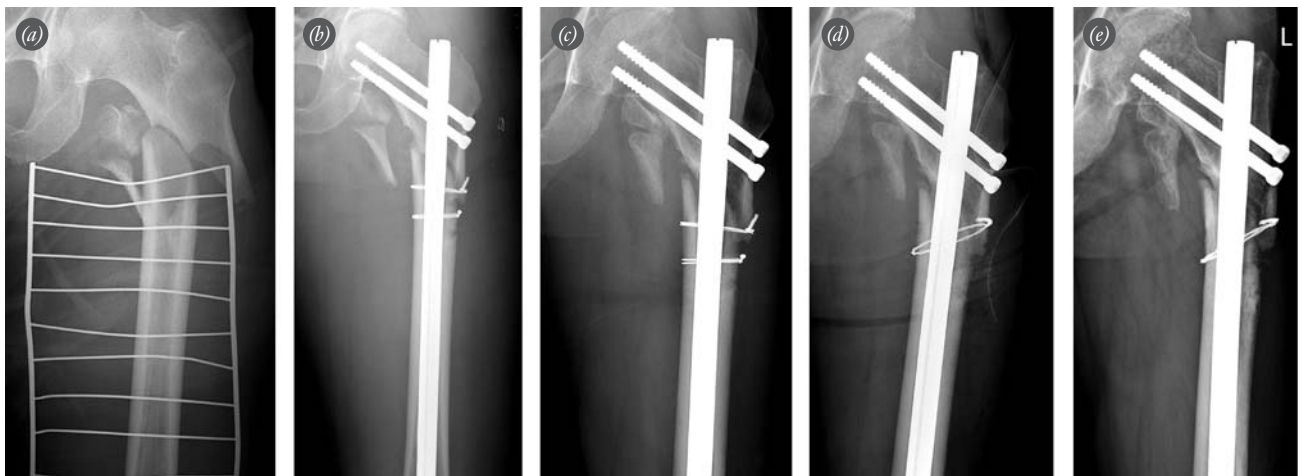


Fig. 2. Antero-posterior view of a subtrochanteric fracture **(a)** in a 70-year-old male patient who fell down the stairs. **(b)** Open reduction using a reconstruction nail & wire. Radiograph shows an atrophic nonunion **(c)** six months after the operation. **(d)** Autogenous bone graft and wiring retaining reconstruction nail. Final radiograph shows a nonunion **(e)** 8 months after the revision surgery.

Our results showed that the union rate was statistically higher in Group 1 than in Group 2. The removal of previous hardware can be achieved by complete removal of the interposed fibrotic tissue, more intimate apposition of bony ends and meticulous bone grafting, which can increase fracture stability. Two cases of nonunion occurred after revision surgery in Group 2. Bony union was not achieved after additional plating or wiring with bone grafting. After all, bony union was achieved with dynamic compression hip screw (1 case) and dual plate (1 case) by re-revision.

There were significant differences in the length of hospital stay, operative time and amount of blood transfusion between the two groups ($p < 0.05$). The mean length of hospital stay was 23.8 ± 3.3 days in Group 1, and 18.2 ± 2.7 days in Group 2; the mean amount of blood transfusion was 960 (range: 0 to 2240) ml in Group 1, and 647 (range: 0 to 1920) ml in Group 2, and the mean operative time was 3.7 ± 0.8 hrs in Group 1, and 2.7 ± 0.6 hrs in Group 2. Retaining the previous hardware has advantages such as less invasive surgery, faster recovery and better economic benefits.

Shortening of a long bone may occur in the treatment of nonunion by various causes such as comminution, infection or surgical techniques. Also efforts to compress the fracture sites to achieve an adequate bony contact would increase shortening of the long bones. Wu et al.^[12] lengthened the fracture site in the subtrochanteric nonunion with shortening by a locked nailing technique, and obtained good outcomes. In our series, the mean preoperative leg length discrepancy was 8.3 (range: 3 to 18) mm in Group 1, 10.0 (range: 2 to 17) mm in Group 2, and the mean final LLD was 13.9 (range: 4 to 28) mm in Group 1, and 11.2 (range: 4 to 18) mm in Group 2. There was no significant difference in LLD between the two groups during the last follow up. Limb length was slightly decreased after revision in Group 1 due to the causes listed above, but it was changed little in Group 2. The preoperative limb shortening in our study was less than in other studies because of the efforts to maintain the limb length in the initial operation. The limitations of this study included the retrospective methodology, small number of series, short follow-up period and a poor standardization by different treatment modalities. Further prospective, large-scale, randomized trials are needed in the future for the treatment of subtrochanteric nonunion.

In conclusion, exchanging the previous hardware might be more useful in achieving the bony union as

compared to the additional fixation by retaining the previous hardware for treatment of subtrochanteric nonunion.

Conflicts of Interest: No conflicts declared.

References

1. Kulkarni SS, Moran CG. Results of dynamic condylar screw for subtrochanteric fractures. *Injury* 2003;34:117-22.
2. Tencer AF, Johnson KD, Johnston DW, Gill K. A biomechanical comparison of various methods of stabilization of subtrochanteric fractures of the femur. *J Orthop Res* 1984;2: 297-305.
3. Bredbenner TL, Snyder SA, Mazloomi FR, Le T, Wilber RG. Subtrochanteric fixation stability depends on discrete fracture surface points. *Clin Orthop Relat Res* 2005;(432): 217-25.
4. Kuzyk PR, Bhadari M, McKee MD, Russell TA, Schemitsch EH. Intramedullary versus extramedullary fixation for subtrochanteric femur fractures. *J Orthop Trauma* 2009;23: 465-70.
5. Parker MJ, Dutta BK, Sivaji C, Pryor GA. Subtrochanteric fractures of the femur. *Injury* 1997;28:91-5.
6. Reynders PA, Stuyck J, Rogers RK, Broos PL. Subtrochanteric fractures of the femur treated with the Zickel nail. *Injury* 1993;24:93-6.
7. Siebenrock KA, Müller U, Ganz R. Indirect reduction with a condylar blade plate for osteosynthesis of subtrochanteric femoral fractures. *Injury* 1998;29:240-6.
8. Craig NJ, Sivaji C, Maffulli N. Subtrochanteric fractures. A review of treatment options. *Bull Hosp Jt Dis* 2001;60:35-46.
9. Rodriguez-Merchan EC, Gomez-Castresana F. Internal fixation of nonunions. *Clin Orthop Relat Res* 2004;(419):13-20.
10. Barquet A, Mayora G, Fregeiro J, López L, Rienzi D, Francescoli L. The treatment of subtrochanteric nonunions with the long gamma nail: twenty-six patients with a minimum 2-year follow-up. *J Orthop Trauma* 2004;18:346-53.
11. Charnely GJ, Ward AJ. Reconstruction femoral nailing for nonunion of subtrochanteric fracture: a revision technique following dynamic condylar screw failure. *Int Orthop* 1996; 20:55-7.
12. Wu CC. Locked nailing for shortened subtrochanteric nonunions. A one-stage treatment. *Clin Orthop Relat Res* 2009;467:254-9.
13. De Vries JS, Kloen P, Borens O, Marti RK, Helfet DL. Treatment of subtrochanteric nonunions. *Injury* 2006;37: 203-11.
14. Haidukewych GJ, Berry DJ. Nonunion of fractures of the subtrochanteric region of the femur. *Clin Orthop Relat Res* 2004;(419):185-8.
15. Park J, Kim SG, Yoon HK, Yang KH. The treatment of non-isthmal femoral shaft nonunions with im nail exchange versus augmentation plating. *J Orthop Trauma* 2010;24:89-94.
16. Rodriguez-Merchan EC, Forriol F. Nonunion: general principles and experimental data. *Clin Orthop Relat Res* 2004; (419):4-12.