



Effect of 900 MHz electromagnetic fields emitted from cellular phones on fracture healing: an experimental study on rats

Ahmet ASLAN¹, Tolga ATAY², Kanat GÜLLE³, Vecihi KIRDEMİR², Ahmet ÖZDEN⁴, Selçuk ÇÖMLEKÇİ⁵, Nevres Hürriyet AYDOĞAN⁶

¹Department of Orthopedics and Traumatology, Afyonkarahisar State Hospital, Afyonkarahisar, Turkey;

²Department of Orthopedics and Traumatology, Faculty of Medicine, Süleyman Demirel University, Isparta, Turkey;

³Department of Histology and Embryology, Faculty of Medicine, Bülent Ecevit University, Zonguldak, Turkey;

⁴Department of Radiology, Private Anadolu Hospital, Kastamonu, Turkey;

⁵Department of Electronics and Communication Engineering, Faculty of Engineering, Süleyman Demirel University, Isparta, Turkey;

⁶Department of Orthopedics and Traumatology, Ankara Training and Research Hospital, Ankara, Turkey

Objective: The aim of this study was to investigate the effect of electromagnetic fields (EMFs) at 900 MHz frequencies on bone fracture healing.

Methods: The study included 30 adult male Wistar albino rats (average weight: 256 g) divided into two equal groups. Transverse fracture was created manually by pressing a finger on the right tibias of all rats and fractures were fixed intramedullary using a K-wire. Rats in Group 1 were exposed to EMF at 900 MHz frequency 30 minutes a day, 5 days a week for 8 weeks. Group 2, the control group, was kept under the same experimental conditions without EMF exposure. Radiological, mechanical and histological examination of tibial fracture healing was performed.

Results: There was a significant difference between radiological, histological and manual biomechanical scores of the study and control groups ($p=0.020$, $p=0.006$ and $p=0.032$, respectively). All scores were lower in the study group than the control group.

Conclusion: Results of this study demonstrate that EMF at 900 MHz of frequency emitted from cellular phones has a significantly negative effect on bone fracture healing in a rat tibia model.

Key words: Electromagnetic field; fracture healing; mobile phone.

Fracture healing and bone formation are complex metabolic events which depend on various systemic/local regulators and involve reciprocal interaction of the cellular structures. The pathophysiological background and healing stages of this process have been well defined although many points have yet to be described. To date,

some ongoing studies regarding the pathophysiological aspect and factors affecting and stimulating the healing process have been performed.^[1-4]

Some negative outcomes on human health and the endocrine and nervous systems in particular have been reported as a result of the interaction between biologi-

Correspondence: Ahmet Aslan, MD. Afyonkarahisar Devlet Hastanesi, Ortopedi ve Travmatoloji Kliniği, Ali Çetinkaya Mah., 03030 Afyonkarahisar, Turkey.

Tel: +90 505 - 646 24 11 e-mail: draaslan@mynet.com

Submitted: March 6, 2012 **Accepted:** January 21, 2013

©2013 Turkish Association of Orthopaedics and Traumatology

Available online at
www.aott.org.tr
doi:10.3944/AOTT.2013.2854
QR (Quick Response) Code:



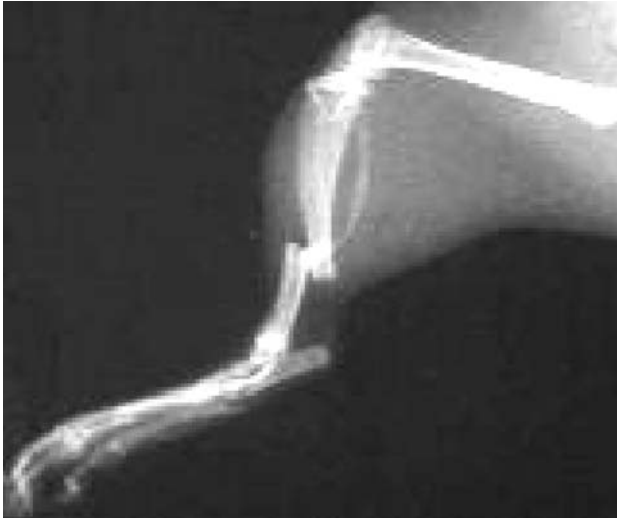

Fig. 1. View of the created fracture.

cal living structures and electromagnetic fields (EMFs) emitting from cellular phones and base stations and classified as high frequency band radiofrequency (RF) area resource in the electromagnetic spectrum.^[4-5] While low frequency EMF is currently used in medical practice, it has been hypothesized that high frequency EMF may have deleterious effects on human health.^[4-7] High frequency EMF emitting from cellular phones and base stations may have some negative effects on biological tissues and bone formation/healing can be affected from these peripheral resources.

In this study, we aimed to investigate the effect of high frequency EMF at 900 MHz emitting from cellular phones on fracture healing.

Materials and methods

A total of 30 adult Wistar albino male rats, aged 5 (range: 4 to 6) months and weighing an average of 256 ± 20 grams, were included in this study. Written consent of approval was granted from the local Ethical Committee of Süleyman Demirel University (SDU) Medical Faculty. Rats were equally and randomly divided into two groups of 15 rats. Group 1 (mean weight: 255 ± 21 grams) was exposed to 900 MHz EMF and Group 2 (mean weight: 259 ± 19 grams) served as the control. Animals were fed ad libitum with standard pellets (rat diet) and activity and/or loading-stress was not restricted during the study period.

Cefazolin sodium (Sefazol®; 15 mg/kg) was administered via intramuscular injection for prophylactic purpose two hours before the surgical intervention. Ketamine HCl (Ketalar®; Eczacıbaşı, İstanbul, Turkey [10 mg/100 mg body-weight]) and xylazine HCl (Alfazyne®; Ege Vet Hayvan. Tic. Ltd. Şti, İzmir,

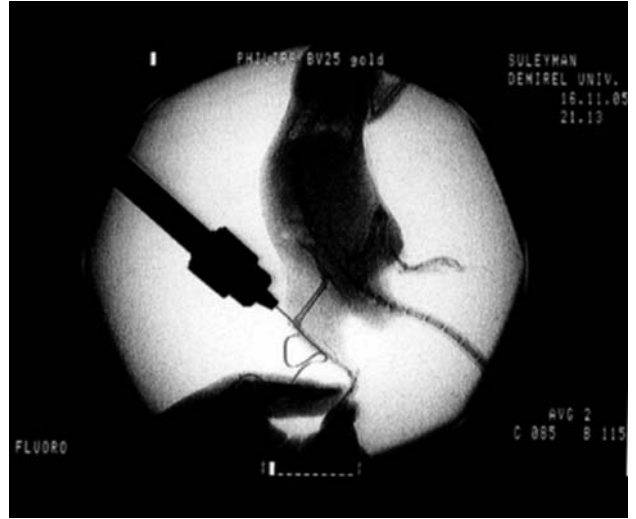


Fig. 2. Intramedullary fixation.

Turkey [0.25 mg/100 mg body-weight]) were intraperitoneally injected for general anesthesia. Manual-induced fracture and intramedullary fixation methods were applied as described by Orhan et al.^[8] Right tibial bones of the rats were transversely broken with finger pressure according to three-point principal (Fig. 1).

After this procedure, the right posterior region of the legs were cleaned with antiseptic solution, covered with sterile dressings and prepared for surgery. An incision of 1.5 cm length was cut on the anterior right knee. Under fluoroscopic control, the fracture line was stabilized with intramedullary fixation method using a K-wire of 0.5-mm thickness inserted from the proximal tibia and passed through intramedullary canal (Fig. 2). The incision site was closed using 4/0 Prolene sutures. The fractures were classified according to appearance



Fig. 3. Rat in the plastic tube and the dipole antenna. [Color figure can be viewed in the online issue, which is available at www.aott.org.tr]

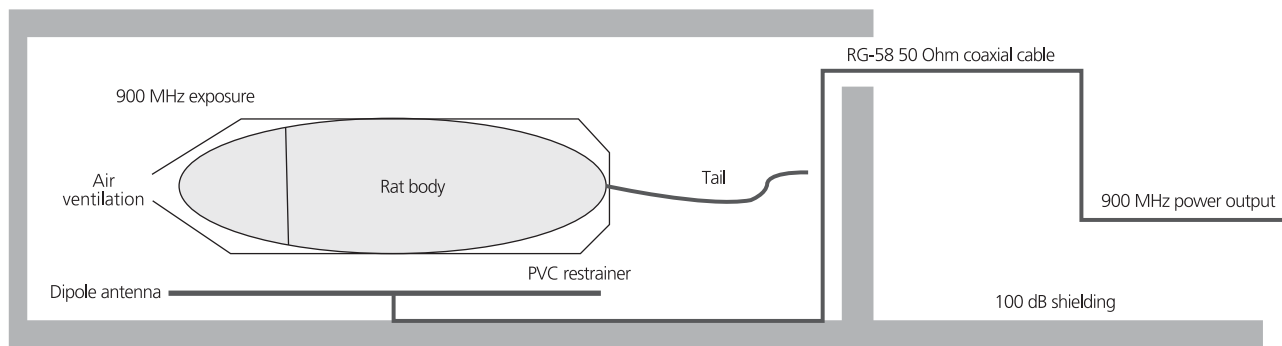


Fig. 4. A schematic view of the EMF application.

using the modified Leisner et al.’s method.^[9] An ideal condition was defined as one fracture line located at the proximal 1/3-distal 2/3 site and a bad condition was defined as partial, comminuted, segmental or intra-articular. Fractures defined as good (n=26) were included in this study and bad fractures (n=4) were excluded.

An electromagnetic energy generator (900/1800 Lab. Test Transmitter, Model GHZ2005X; Set Elec. Co., Istanbul, Turkey) giving outputs between 0 and 4 Watts at 900 MHz was used to produce signals at the frequency of cellular phones. The setup was tested in the Electromagnetic Compatibility Laboratory of the Department of Electronics and Communication Engineering of SDU. Generator emission was checked

by a spectrum analyzer (Promax AE-566; Promax Electronica SL., L’Hospitalet de Llobregat, Spain) and verified by the satellite level meter (Promax MC-877C; Promax Electronica SL., L’Hospitalet de Llobregat, Spain). All exposure measurements were carried out using the Portable RF Survey System (Holaday HI-4417; Holaday Industries, Inc., MN, USA) with its standard probe. The theoretical analysis of the local or whole body specific absorption rates (SAR) are from the study by Gajsek et al.^[10,11] The SAR value of the rats was theoretically calculated as 0.008 W/kg. Rats near the dipole antenna were exposed to EMR at 1.04 mW/cm² power intensity rate. During exposure, each rat was placed in a special plastic holder and the exposure sys-

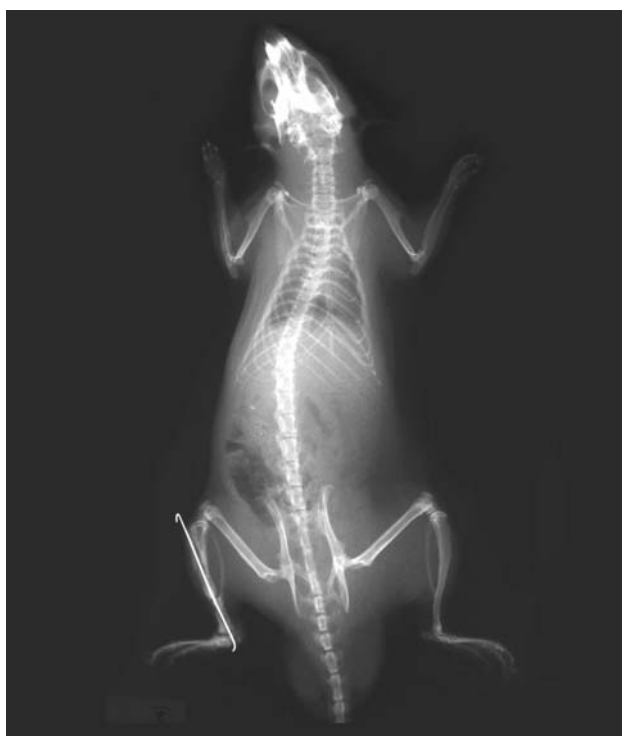

Fig. 5. Postoperative 8th week view of a rat from Group 1.

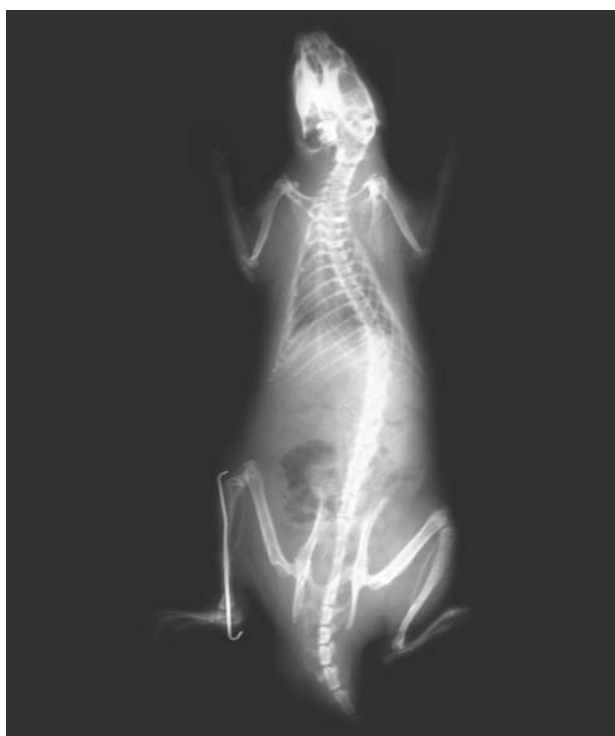

Fig. 6. Postoperative 8th week view of a rat from Group 2.

Table 1. Radiological evaluation scoring system.

Score	Fracture healing findings
Periosteal reaction (callus formation)	
3	Full (across the defect)
2	Moderate
1	Mild
0	None
Bone union	
3	Union
2	Moderate (>50% bridging)
1	Mild (<50% bridging)
0	Nonunion
Remodeling	
3	Full remodeling of the cortex
2	Gross remodeling of the cortex
1	Remodeling of the intramedullary canal
0	No remodeling
9	Maximal total score

tem's dipole antenna was placed under the plastic holder at a distance of 5 mm (Fig. 3). The quality of the transmitted signal was checked using Promax AE-566 spectrum analyzer with its appropriate near-field probes. The power density measurements were made with an EMF survey meter (Holaday Industries, Inc., Eden Prairie, MN, USA). Rats in the study group were exposed to 900 MHz EMF for 30 min/day, 5 days/week for a duration of 8 weeks. The unexposed control group was kept in the same laboratory conditions. In the experimental setup procedure and application, the method described by Chou et al.^[12] was used. EMF application is shown schematically in Fig. 4.

Following the administration of sevoflurane (Sevorane®) to rats via inhalation, direct control radiographs were taken one day after the operation to

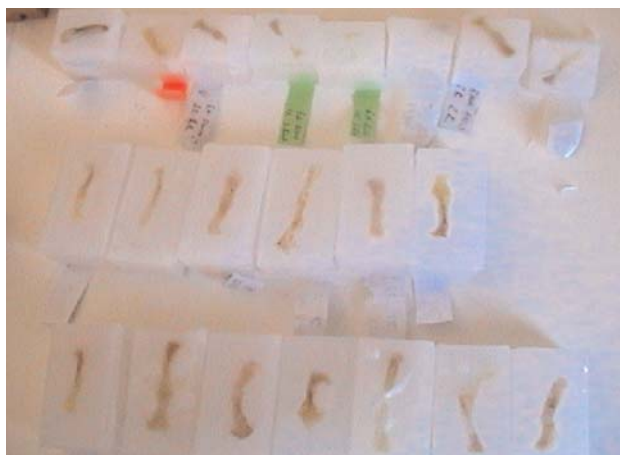

Fig. 7. Sections of paraffin-embedded blocks. [Color figure can be viewed in the online issue, which is available at www.aott.org.tr]

check the fracture and stabilization condition. The formation of callus tissue was followed on subsequent direct radiographs on the 2nd, 4th, 6th and 8th week postoperative weeks (Figs. 5 and 6). At the end of the study, radiographs were evaluated according to the modified radiographic scoring system (Table 1) by one radiologist blind to the results.^[13]

The right tibial bones of the rats were excised with callus tissues and the surrounding soft tissues were separated. All tissues were fixated with neutral buffered formalin solution (10%). Routine histological follow-up procedure was performed after decalcification process using nitric acid (10%). Tissues were embedded in paraffin (Fig. 7), longitudinally cut at 6 µm thickness by centering the fracture line, stained with hematoxylin-eosin dye and examined under the light microscope (Figs. 8 and 9). The stained slides were evaluated by one histologists blinded to the study according to the method described by Huo et al. (Table 2).^[14] The protocol described by Deibert et al.^[15] was used as the histopathological evaluation method.

Mechanical evaluation was performed according to the method described by Şener et al. (Table 3).^[16] The fracture was evaluated on two planes with respect to motility. One orthopaedic surgeon blinded to the groups macroscopically evaluated the union tissues in tibial fracture sites in two planes.

SPSS 11.0 for Windows statistical calculation software was used for statistical analysis. The Mann-Whitney U test was used for group comparison and p values less than 0.05 were considered significant. Results were given as mean±standard deviation.

Results

Four rats (two from Group 1 and two from Group 2) with fractures classified as 'bad' were excluded at the beginning of the study. Three rats in Group 1 and one rat in Group 2 died during the course of the study. In addition, one rat from Group 1 and three rats from Group 2 were excluded as the obtained histological slides could not be clearly examined. There was no sign of wound infection or osteomyelitis in the animals.

A total of 22 direct radiographs (10 from the EMF and 12 from the control group) were evaluated. The mean and standard deviation values are given in Table 4. Results in the EMF group were significantly worse than the control group ($p=0.020$) (Tables 4 and 5, Fig. 10).

Nine slides each from the EMF and control groups were histopathologically examined. Mean and standard deviation of the scores are given in Table 4. The EMF group results were significantly worse than those of the control group ($p=0.006$) (Tables 4 and 5, Fig. 11).

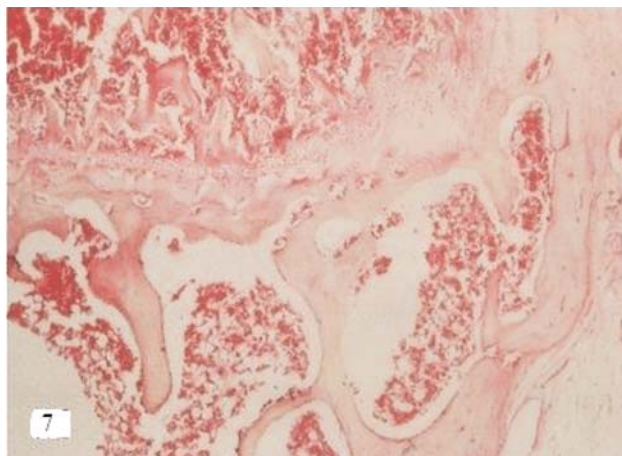


Fig. 8. The presence of osteocytes in lacunas showing live bone tissue in a sample from the control group (H&E x4). [Color figure can be viewed in the online issue, which is available at www.aott.org.tr]

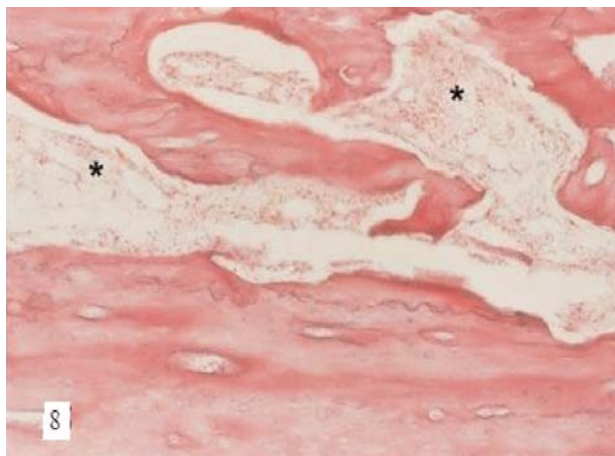


Fig. 9. Bone marrow cells (stars) are seen but live cell areas are not observed in this sample from the EMF group (H&E x4). [Color figure can be viewed in the online issue, which is available at www.aott.org.tr]

A total of 22 tibial bones (10 from the EMF group and 12 from the control group) were mechanically evaluated. The EMF group scores were statistically lower than the control group ($p=0.032$) (Tables 4 and 5, Fig. 12).

Discussion

Numerous studies regarding the positive or negative effects of local and systemic factors on fracture healing exist in the literature. Several experimental and clinical studies are available regarding the effect of drugs, physical agents, diverse energy types, osteoinductive agents and others on fracture healing.^[2-4,8,17] Notable studies include the report by Friedenberg and Brighton^[18] that bone growth and healing have electrical activity and the report by Bassett et al.^[19] on increased bone formation with low frequency pulsed electromagnetic field (LFPEF). Following these studies, various studies on the effect of EMF applications on fracture healing have been performed such as those reporting that pulsed electromagnetic fields (PEF) have positive,^[19-22] negative^[23,24] or no effect^[25,26] on bone fracture healing. Favorable outcome rates ranging between 64 and 85 percent have been reported by previous clinical studies conducted on delayed union and

Table 2. Histological evaluation scoring system.

Score	Category of histological findings
1	Fibrous tissue
2	Mainly fibrous tissue
3	Equal amounts of fibrous and cartilaginous tissue
4	Mainly cartilage and little fibrous tissue
5	Cartilage tissue
6	Mainly cartilage and little immature bone tissue
7	Equal amounts of cartilage and immature bone tissue
8	Mainly immature bone and little cartilage tissue
9	Immature bone fracture healing
10	Mature bone fracture healing

Table 3. Mechanical evaluation system.

Score	Clinical findings in the fracture site
0	Nonunion (motility on two planes)
1	Moderate union (motility on one plane)
2	Complete union (lack of motility)

nonunion, along with the experimental studies conducted via using low frequency PEF. However, there is still no clear data on whether this approach is effective

Table 4. Distribution of radiological, histological and mechanical scores (mean±SD).

Groups	Radiological score			Histological score			Mechanical score		
	n	Mean	±SD	n	Mean	±SD	n	Mean	±SD
Group 1 (900 MHz)	10	6.6000	1.34990	9	8.1111	.33333	10	1.2000	.63246
Group 2 (control)	12	7.9167	1.08362	9	8.8889	.60093	12	1.7500	.45227

SD: standard deviation

Table 5. Intergroup comparisons of histological, radiological and mechanical scores.*

	Group 1	Group 2	p value
Radiological score (mean±SD)	6.6000±1.34990	7.9167±1.08362	0.020
Histological score (mean±SD)	8.1111±0.33333	8.8889±0.60093	0.006
Mechanical score (mean±SD)	1.2000±0.63246	1.7500±0.45227	0.032

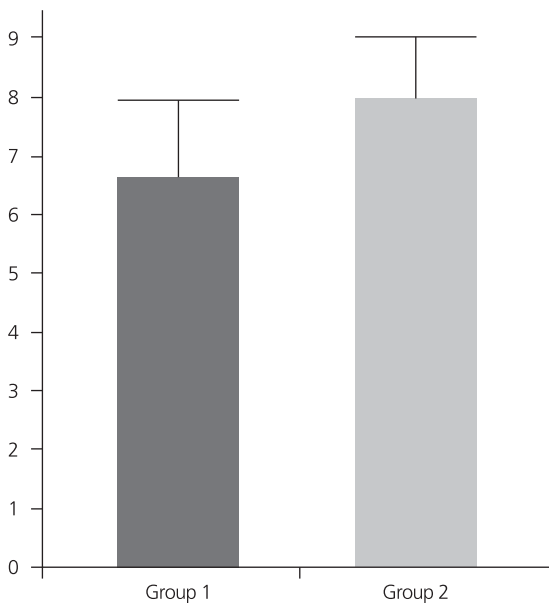
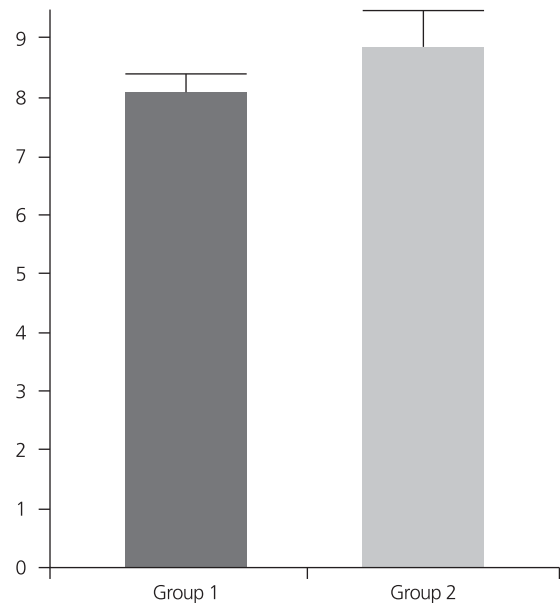
*Mann-Whitney U test. SD: standard deviation.

in treatment of fresh fractures.^[27] The majority of these studies used low frequency PEF.

Negative effects on biological tissues of EMF originating from 900 MHz frequency have been reported in epidemiological, clinical and experimental studies conducted to reveal the effect of RF electromagnetic waves emitting from cellular phones operating at high frequency band field.^[28-32] However, other studies have reported that EMR emitting from cellular phones has no serious effect on health.^[33,34] The effect of high frequency EMF on fracture healing is still unknown. Additionally, there are few studies regarding the effects of RF EMF emitting from cellular phones on bone tissue.^[35-40] A study by Yıldız et al., in which EMF at 1 ± 0.4 mW/cm² power was applied for 30 minutes a day, 5 days a week for a total of 4 weeks reported that the mean femoral and vertebral bone mass density (BMD) values of the rats exposed to 900 and 1800 MHz RF EMF were less than the controls, although the difference was not statistically significant.^[35] In some experimental studies investigating the effect of RF EMF at 900 and 1800 MHz emitting from cellular phones and

other sources on bone tissue, minimal changes have been observed.^[36] Çiçek et al. reported a decrease in breaking power, bending resistance and total breaking energy in bone tissues of rats exposed to RF EMF at 1800 MHz frequency.^[37] Atay et al. mentioned a decrease in the mean BMD of pelvic ring bone tissues of individuals carrying cellular phones at their belt.^[38] Aslan et al. reported that short- or long-term exposure to EMF at 900 MHz frequency (power: 1.04 mW/cm², SAR value: 0.008 W/kg) had no significant effect on bone tissues of rats.^[39] In the present study, significantly lower radiological, histological and manual mechanical impact scores were found in the study group exposed to EMF at 900 MHz than the control group. This, in turn, suggests that high frequency EMF at 900 MHz emitting from cellular phones negatively affects the fracture healing process (Table 5).

On the other hand, it can be postulated that this study is in accordance with those in the literature emphasizing the negative effects of EMF at 900 MHz on bone fracture healing, when taking into consideration other studies reporting the unfavorable effect of LFPEF on frac-

**Fig. 10.** Radiological evaluation results.**Fig. 11.** Histopathological evaluation results.

ture healing^[23,24,27] and various research papers reporting the deleterious effects of EMF emitting from cellular phones on other tissues.^[28-32] However, our study differs from other LFPEF studies by means of the materials used, experimental animal model, applied methodology, EMF type, frequency, power fidelity and exposure duration/dose. It also exhibits some differentiations from other studies in which cellular phone signal-based high frequency EMF were used with respect to similar parameters given above. In addition, it is usual that various studies conducted by different frequency ranges and diverse methods can yield different results. Furthermore, there is no consensus in the literature on which EMF at which frequency, duration and dose has a negative or therapeutic effect when setting aside the results established from studies performed using low and high frequencies and the effects of EMF on bone and other tissues.^[4,41,42]

It has been previously reported that high frequency EMF leads to damage on biological tissues by affecting the biochemical mechanisms or by inducing heat.^[43,44] A limitation of our study was that we were unable to make a more objective commentary on heat effect as we did not measure the temperature systemically nor from the local fracture sites for both groups. More detailed information about the effect of EMF on stages of bone fracture healing and callus tissue formation could be gathered via scintigraphic and quantitative tomographic imaging, and bone turnover markers determined by biochemical analysis would contribute to our study.

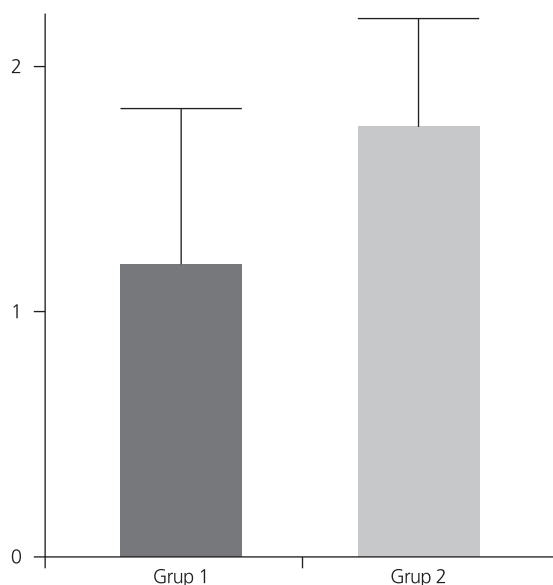


Fig. 12. Mechanical evaluation results.

In conclusion, RF EMF at 900 MHz emitting from cellular phones has a prominent negative effect on bone fracture healing in a rat tibia fracture model. Thermal and non-thermal mechanisms may play a cooperative role in the deleterious effect of cellular phone-induced high frequency EMF on fracture healing. Further comprehensive studies are required in this field to reveal the underlying effective mechanisms and possible effects of cellular phone usage.

Acknowledgement

We thank the SDU Medical Faculty, Department of Physiology and Pathology for their contributions. This study is supported by the SDU Research Projects Management Unit (Project No: 1141-TU-05). The results of this study were presented in summary at the 22nd The Turkish National Congress of Orthopaedics and Traumatology in 2011.

Conflicts of Interest: No conflicts declared.

References

1. Einhorn TA. The science of fracture healing. *J Orthop Trauma* 2005;19:S4-6.
2. Einhorn TA. New technologies for the enhancement of skeletal repair: Challenges and opportunities. *Indian J Orthop* 2011;45:489-91.
3. Baldık Y, Talu U, Altınel L, Bilge H, Toker GA. Radiographic evaluation of the effect of nitric oxide on bone healing: an experimental study. [Article in Turkish] *Acta Orthop Traumatol Turc* 2000;34:190-7.
4. Aslan A. The effects of low and high frequency electromagnetic fields on fracture healing. Review. [Article in Turkish] *Kafkas Journal of Medical Sciences* 2012;2:34-42.
5. Ocaktan ME, Akdur R. Cellular phone technology and health: Review. [Article in Turkish] *Turkiye Klinikleri J Med Sci* 2008;28:58-65.
6. Chalidis B, Sachinis N, Assiotis A, Maccauro G. Stimulation of bone formation and fracture healing with pulsed electromagnetic fields: biologic responses and clinical implications. *Int J Immunopathol Pharmacol* 2011;24:17-20.
7. Bachl N, Ruoff G, Wessner B, Tschan H. Electromagnetic interventions in musculoskeletal disorders. *Clin Sports Med* 2008;27:87-105.
8. Orhan Z, Alper M, Senel F, Yılmaz N, Sayar U. The effect of extracorporeal shockwave treatment on the healing of experimental rat tibial fractures. [Article in Turkish] *Acta Orthop Traumatol Turc* 2001;35:351-7.
9. Leisner S, Shahar R, Aizenberg I, Lichovsky D, Levin-Harrus T. The effect of short-duration, high-intensity electromagnetic pulses on fresh ulnar fractures in rats. *J Vet Med A Physiol Pathol Clin Med* 2002 ;49:33-7.
10. Gajsek P, Walters TJ, Hurt WD, Ziriak JM, Nelson DA, Mason PA. Empirical validation of SAR values predicted by FDTD modeling. *Bioelectromagnetics* 2002;23:37-48.
11. Gajsek P, Ziriak JM, Hurt WD, Walters TJ, Mason PA. Predicted SAR in Sprague-Dawley rat as a function of permittivity values. *Bioelectromagnetics* 2001;22:384-400.

12. Chou CK, Chan KW, McDougall JA, Guy AW. Development of a rat head exposure system for simulating human exposure to RF fields from handheld wireless telephones. *Bioelectromagnetics* 1999; Suppl 4:75-92.
13. An YH, Friedman RJ, Draughn RA. Animal models of bone fracture or osteotomy. In: An YH, Friedman RJ, editors. *Animal models in orthopaedic research*. Boca Raton, FL: CRC Press; 1999. p. 197-217.
14. Huo MH, Troiano NW, Pelker RR, Gundberg CM, Friedlaender GE. The influence of ibuprofen on fracture repair: biomechanical, biochemical, histologic, and histomorphometric parameters in rats. *J Orthop Res* 1991;9:383-90.
15. Deibert MC, Mcleod BR, Smith SD, Liboff AR. Ion resonance electromagnetic field stimulation of fracture healing in rabbits with a fibular osteotomy. *J Orthop Res* 1994;12:878-85.
16. Şener N, Akman Ş, Göğüş A, Bilgiç B. The effect of calcium sulfate on fracture healing in rat tibial fractures. [Article in Turkish] *Acta Orthop Traumatol Turc* 2001;35:431-7.
17. Aydin K, Sahin V, Gürsu S, Mercan AS, Demir B, Yildirim T. Effect of pentoxifylline on fracture healing: an experimental study. *Eklemler Hastalıkları Cerrahisi* 2011;22:160-5.
18. FriedenberG ZB, Brighton CT. Bioelectric potentials in bone. *J Bone Joint Surg Am* 1966;48:915-23.
19. Bassett CA, Pawluk PJ, Pilla AA. Augmentation of bone repair by inductively coupled electromagnetic fields. *Science* 1974;184:575-7.
20. Bassett CA, Valdes MG, Hernandez E. Modification of fracture repair with selected pulsing electromagnetic fields. *J Bone Joint Surg Am* 1982;64:888-95.
21. Grace KL, Revell WJ, Brookes M. The effects of pulsed electromagneticism on fresh fracture healing: osteochondral repair in the rat femoral groove. *Orthopedics* 1998;21:297-302.
22. Diniz P, Shomura K, Soejima K, Ito G. Effects of pulsed electromagnetic field (PEMF) stimulation on bone tissue like formation are dependent on the maturation stages of the osteoblasts. *Bioelectromagnetics* 2002;23:398-405.
23. Marino AA, Cullen JM, Reichmanis M, Becker RO. Fracture healing in rats exposed to extremely low-frequency electric fields. *Clin Orthop Relat Res* 1979;(145):239-44.
24. Muhsin AU, Islam KM, Ahmed AM, Islam MS, Rabbani KS, Rahman SM, et al. Effect of pulsed electromagnetic field on healing of experimental nonunion in rat tibiae. *Bangladesh Med Res Counc Bull* 1991;17:1-10.
25. De Haas WG, Lazarovici MA, Morrison DM. The effect of low frequency magnetic fields on the healing of the osteotomized rabbit radius. *Clin Orthop Relat Res* 1979;(145):245-51.
26. van Roermund PM, ter Haar Romeny BM, Hoekstra A, Schoonderwoert GJ, Brandt CJ, van der Steen SP, et al. Bone growth and remodeling after distraction epiphysiolytic of the proximal tibia of the rabbit. Effect of electromagnetic stimulation. *Clin Orthop Relat Res* 1991;(266):304-12.
27. Hannay G, Leavesley D, Percy M. Timing of pulsed electromagnetic field stimulation does not affect the promotion of bone cell development. *Bioelectromagnetics* 2005;26:670-6.
28. Meral I, Mert H, Deger Y, Yoruk I, Yetkin A, Keskin S. Effects of 900-MHz electromagnetic field emitted from cellular phone on brain oxidative stress and some vitamin levels of guinea pigs. *Brain Res* 2007;1169:120-4.
29. Eliyahu I, Luria R, Hareuveny R, Margalioth M, Meiran N, Shani G. Effects of radiofrequency radiation emitted by cellular telephones on the cognitive functions of humans. *Bioelectromagnetics* 2006;27:119-26.
30. Koyu A, Cesur G, Ozguner F, Akdogan M, Mollaoglu H, Ozen S. Effects of 900 MHz electromagnetic field on TSH and thyroid hormones in rats. *Toxicol Lett* 2005;157:257-62.
31. Oktem F, Ozguner F, Mollaoglu H, Koyu A, Uz E. Oxidative damage in the kidney induced by 900-MHz-emitted mobile phone: protection by melatonin. *Arch Med Res* 2005;36:350-5.
32. Zamorano M, Torres-Silva H. FDTD chiral brain tissue model for specific absorption rate determination under radiation from mobile phones at 900 and 1800 MHz. *Phys Med Biol* 2006;51:1661-72.
33. Tuschl H, Novak W, Molla-Djafari H. *In vitro* effects of GSM modulated radiofrequency fields on human immune cells. *Bioelectromagnetics* 2006;27:188-96.
34. Tandogan I, Ozin B, Bozbas H, Turhan S, Ozdemir R, Yetkin E, et al. Effects of mobile telephones on the function of implantable cardioverter defibrillators. *Ann Noninvasive Electrocardiol* 2005;10:409-13.
35. Yıldız M, Çiçek E, Çerci SS, Çerci C, Oral B, Koyu A. Influence of electromagnetic fields and protective of CAPE on bone mineral density in rats. *Arch Med Res* 2006;37:818-21.
36. Atay T, Aslan A, Heybeli N, Aydoğan NH, Baydar MI, Ermol C, et al. Effects of 1800 MHz electromagnetic field emitted from cellular phones on bone tissue. *Balkan Medical Journal* 2009;26:292-6.
37. Cicek E, Gokalp O, Varol R, Cesur G. Influence of electromagnetic fields on bone fracture in rats: role of CAPE. *Biomed Environ Sci* 2009;22:157-60.
38. Atay T, Aksoy BA, Aydoğan NH, Baydar ML, Yıldız M, Ozdemir R. Effect of electromagnetic field induced by radio frequency waves at 900 to 1800 MHz on bone mineral density of iliac bone wings. *J Craniofac Surg* 2009;20:1556-60.
39. Aslan A, Aydoğan NH, Atay T, Çömlekçi S. The effects of electromagnetic field exposure at short and long term of 900 MHz frequency emitted from mobile phones on rat bone tissue. *Dicle Tıp Dergisi* 2011;38:452-57.
40. Kalender AM, Goktas U, Ozbag D, Erturk C, Okumus M, Guner S, et al. The effect of GSM mobile phone electromagnetic field on femur fracture healing in a rat model. *J Clin Anal Med* 2012;3:388-92.
41. Aslan A, Aydoğan NH, Atay T, Kırdemir V. Effects of 50 Hz electric field on bone mineral density and fractures healing: an experimental rat study. [Article in Turkish] *Ankara Eğitim ve Araştırma Hastanesi Tıp Dergisi* 2012;45:22-8.
42. Shupak NM, Prato FS, Thomas AW. Therapeutic Uses of pulsed magnetic field exposure: A review. *Radio Sci Bull* 2003;307:9-32.
43. Christ A, Samaras T, Neufeld E, Klingensböck A, Kuster N. SAR distribution in human beings when using body-worn RF transmitters. *Radiat Prot Dosimetry* 2007;124:6-14.
44. Dasdag S, Ketani MA, Akdag Z, Ersay AR, Sari I, Demirtas OC, et al. Whole-body microwave exposure emitted by cellular phones and testicular function of rats. *Urol Res* 1999;27:219-23.