



# The linea aspera-pilaster complex as a possible cause of confusion with the 'flame sign': a case report

Daniel GHEORGHIU, Andrea LEINENKUGEL

*Department of Trauma and Orthopaedic Surgery, Royal Liverpool and Broadgreen University Hospital, Liverpool, UK*

The linea aspera is an important osteological feature onto which many muscles insert. Evolutionary as well as individual lifestyle changes can lead to the radiographic appearance of the linea aspera-pilaster complex as the track sign. This rare feature is known to radiologists and anthropologists as a normal roentgen and anatomical variant. However, its knowledge is less common even amongst experienced senior orthopedic surgeons. The track sign can be readily confused with the pathological 'flame sign' of Paget's disease leading to unnecessary investigations. This case report intends to increase awareness amongst experienced and trainee orthopedic surgeons alike, of the physiological existence of the track sign.

**Key words:** Femur/anatomy & histology/radiography.

The linea aspera is a prominent longitudinal ridge or crest, on the middle third of the femur, presenting a medial and a lateral lip, and a narrow, rough, intermediate line representing the linea pectinea. They serve for the insertion of the gluteus maximus, adductor magnus, adductor brevis, adductor longus, and pectineus muscles.

The linea aspera is frequently elevated by an underlying bony ridge or pilaster, resulting in a prismatic, cross-sectional configuration that provides additional biomechanical support for the posterior femur.<sup>[1]</sup> On anteroposterior radiographs of the adolescent femur, the linea aspera-pilaster complex may sometimes appear as the so-called track sign and it can be readily mistaken for the pathological flame sign in Paget's disease.<sup>[2]</sup>

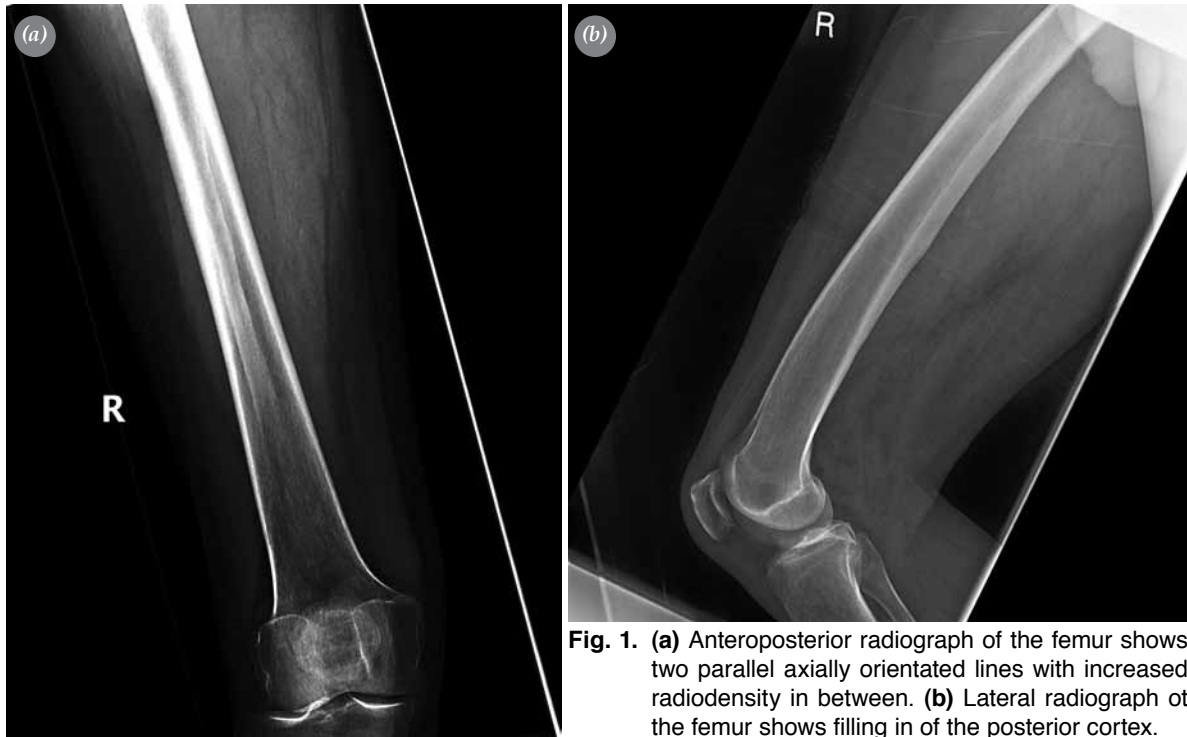## Case report

A 61-year-old male patient presented to our outpatient clinic with a nine-month history of right posterior thigh pain. He worked as an HGV (heavy goods vehicle) driver and he could not remember any trau-

matic event or any other incident relating to the onset of pain. He denied any recent weight loss, lethargy, night sweats, or any other symptoms suggesting an underlying malignant pathology. He described the pain as intermittent, sharp, and stabbing in his posterior thigh.

On clinical examination, the patient had an antalgic gait on the right side. Inspection of the thigh revealed no muscle wasting or change in circumference compared to the other side. There were no obvious skin changes such as erythema or skin lesions on the posterior thigh. Examination of the lumbosacral spine, bilateral hips and knees were normal. Superficial and deep palpation of the thigh showed no underlying soft tissue mass. Blood investigations showed normal full blood count, erythrocyte sedimentation rate of 7 mm/hr (normal, 0-10 mm/hr), serum alkaline phosphatase level of 93 U/l (normal, 35-125 U/l), and normal clinical chemistry results.

Anteroposterior and lateral radiographs of the right femur showed two parallel lines which were axially orientated along the middle third of the fem-



**Fig. 1.** (a) Anteroposterior radiograph of the femur shows two parallel axially orientated lines with increased radiodensity in between. (b) Lateral radiograph of the femur shows filling in of the posterior cortex.

oral diaphysis (Fig. 1). These findings were identified as a possible 'flame' sign associated with Paget's disease and the patient was further investigated with an isotope bone scan. The scan showed no evidence for active Paget's disease or any other significant osteoblastic pathology, but mildly increased tracer uptake in both shoulders and the right hip, likely to be due to osteoarthritic changes (Fig. 2). A subsequently performed magnetic resonance scan showed no localized soft tissue or bone abnormality in the thigh but arthropathy in the right hip joint. Based on the negative investigations for Paget's disease or a bone pathology, the lesion in question was identified to be a track sign.

We showed the plain radiographs of the patient to two senior radiologists, trained in assessing musculoskeletal radiographs, and three orthopedic consultants at our institute. The radiologists were aware of the track sign being a normal roentgen variant but had only seen 3-4 cases before. None of the orthopedic consultants were aware of the track sign and its significance.

## Discussion

The appearance of the linea aspera is often delayed until after birth, and its distinctive form is sometimes

not attained until adolescence. The pilaster is rarely seen as early as late childhood, but develops after puberty and is maximal by middle age.<sup>[3]</sup> Prominent development is a distinct human feature that is not seen in lower primates.<sup>[2]</sup>

In anthropology, there seems to be a change in the trend for pilasteric development, which may reflect changes in lifestyle and biomechanical stress in human evolution in general as well as the individual lifestyle of its possessor in particular.<sup>[4]</sup>

Prominent development of the linea aspera is visible on a frontal radiograph of the femur mainly in adults and in some cases of adolescents. Lateral radiographs may demonstrate filling in of the posterior shaft concavity.<sup>[5]</sup>

When the surface of the linea aspera is rough, it appears on a lateral view as a scalloping on the posterior femoral margin.<sup>[1]</sup> Although this normal roentgen variant may present as a periosteal reaction, osteonecrosis, and periostitis suggestive of Paget's disease, it should not be confused with it.<sup>[1,5]</sup>

In conclusion, the track sign is a normal but relatively rare finding. It seems to be well known to radiologists and less known to orthopedic surgeons. Orthopedic trainees and trainers should be aware of

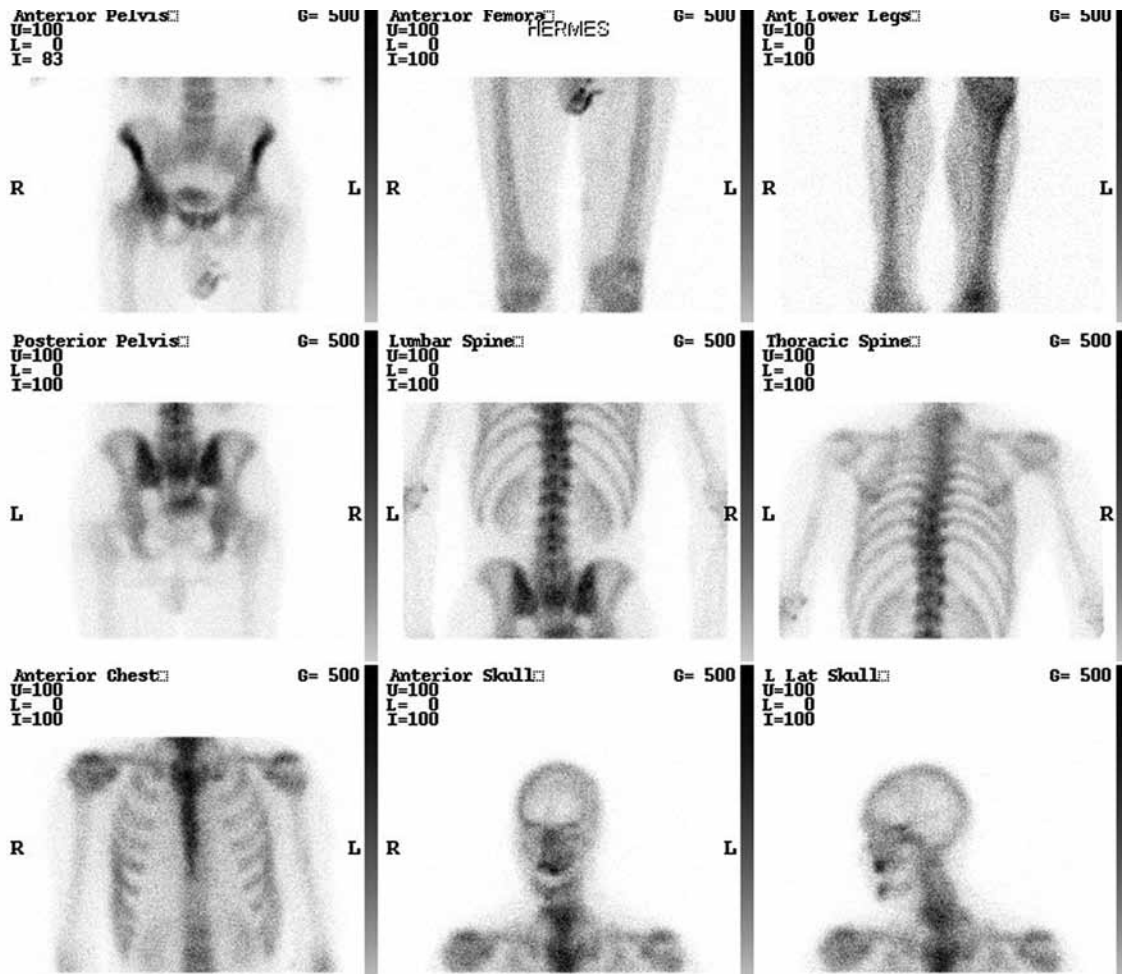


Fig. 2. Isotope bone scan shows mild tracer uptake in both shoulders and the right hip.

the existence of this normal radiographic variant in order to prevent unnecessary radiographic imaging in the future.

## References

1. Hoeffel C, Munier G, Hoeffel JC. The femoral linea aspera: radiological pattern. *Eur Radiol* 1993;3:357-8.
2. Hrdlicka A. The gluteal ridge and gluteal tuberosities (3rd trochanters). *Am J Phys Anthropol* 1937;23:127-98.
3. Wang Q, Tobias PV, Roberts DL, Jacobs Z. A re-examination of a human femur found at the Blind River Site, East London, South Africa: its age, morphology, and breakage pattern. *Anthropological Review* 2008;71:43-61.
4. Scheuer L, Black S. The lower limb. In: *The juvenile skeleton*. London: Elsevier Academic Press; 2004. p. 341-408.
5. Pitt MJ. Radiology of the femoral linea aspera-pilaster complex: the track sign. *Radiology* 1982;142:66.