



Sensory recovery of the reverse homodigital island flap in fingertip reconstruction: a review of 66 cases

Memet YAZAR, Atakan AYDIN, Sevgi KURT YAZAR, Karaca BAŞARAN, Erdem GÜVEN

Istanbul University, İstanbul Faculty of Medicine, Department of Plastic and Reconstructive Surgery, İstanbul

Objectives: The location of the fingertip entitles it to have significant cosmetic and functional values, but also places it at high risk for injury. During repair, finger length and function should be maintained, and stiffness and neuroma should be avoided. Various flaps have been described for reconstruction of distal finger defects with bone, tendon, or joint exposures, including reverse flow homodigital island flap. In this study, we present our experience of reverse flow homodigital island flap in terms of sensory recovery.

Methods: Sixty-six patients (70 fingers) with fingertip amputations were included in the study. Patients were treated with homodigital island flaps. All patients underwent sensitivity assessment by 2-point discrimination and Semmes-Weinstein monofilament tests at 6, 12, and 18 months during follow-up, and complications were recorded.

Results: Monofilament testing results were normal in 64 fingers (91.4%), and diminished light touch was found in six fingers. Two-point discrimination results were normal (<6 mm) in 40 fingers and fair (6-10 mm) in 30 fingers (mean 5.7 mm, range 4-9 mm). Complications included one partial flap necrosis, three flexion contractures, and two neuromas.

Conclusion: In repair of injuries to areas in which sensory feedback is critical, such as the index finger, the homodigital flap may be the treatment of choice.

Key words: Fingers; reconstructive surgical procedures; recovery of function; sensation; surgical flaps.

Because of the highly specialized nature of the fingertip, pulp reconstruction may be challenging. The optimal treatment of the fingertip injuries is still arguable. Finger length and function should be preserved, and there should be no joint stiffness or neuroma formation. Cosmetically acceptable appearance is also required by patients. Fingertip sensation is particularly important for the thumb and the index finger, where pinch and grasp are crucial. Many options like V-Y advancement flap (Atasoy), lateral V-Y advancement

flap (Kutler), thenar flap, and cross-finger flap have been defined in fingers with exposed bones, tendons, or joints.^[1-5] One of these methods is the reverse flow homodigital island flap, first described by Lai et al.^[6] and Kojima et al.^[7] Different results have been reported concerning the outcomes of this flap in literature. In our series of 66 patients who referred to our emergency department for fingertip injury, we aimed to report the sensory recovery following reverse flow homodigital island flap.

Patients and methods

Sixty-six patients (70 fingers, 56 males, 10 females) with complex fingertip injuries between May 2006 and June 2008 were included in the study. Flap coverage was indicated for all injuries. Reverse flow homodigital island flap was chosen as the treatment method. Patients' age ranged between 10 and 54 years (mean 31.5 years). Forty cases were work-related accidents, 15 were home accidents, and the remaining 11 were classified as traffic accidents. Involved digits included the second finger in 36 cases, middle finger in 15 cases, fourth finger in 16 cases, and fifth finger in three cases (Table 1). All cases were regarded as group 1 by Tamai classification. Bone or tendon exposure with volar oblique or transverse amputations was found in all patients.

Surgical technique

All patients were operated by the same surgeon. A digital or axillary block was used. Antibiotic prophylaxis was done, and a pneumatic tourniquet was applied. A loupe with 4x magnification was used throughout the procedure. Debridement of the stump was done initially. The flap was designed from the mid-lateral portion of the non-dominant side of the proximal phalanx of the same finger (Fig. 1).

During planning, flap size was determined in a standard fashion, where flap width did not cross the borders between midlateral line and the middle of the volar zone. Therefore all donor regions could be closed primarily without a need for a skin graft (Fig. 1). The length, in contrast, was planned according to the flap size. However, it was maximally planned between the levels of proximal interphalangeal (PIP) and the metacarpophalangeal (MP) joints (Fig. 1). The flap was designed in a fusiform shape. This enabled us to close the defect easily together and get rid of "dog ears." After the initial plan, we performed a straight 1-cm incision proximally towards the distal palmar crease and a zig-zag incision distally up to the defect. This incision was required to prevent contracture during healing. Flap incision was done later together with the dissection of the digital bundle proximally. After identification of the digital artery, it was ligated and cut (Fig. 2a). The distal end of the artery was ligated with 5/0 silk and left long where it was used for retraction during dissection. The identified proximal digital nerve was again ligated and cut proximally. To prevent a neuroma, the proximal stump of the nerve was buried in the soft tissues.

Table 1
Demographic and clinical findings [number of patients or mean (range)]

Gender	Male	56
	Female	10
Injured finger	Index	36
	Middle	15
	Fourth	16
	Fifth	13
Two-point discrimination test (mm)		5.7 (4-9)
Semmes-Weinstein monofilament testing	Normal	64
	Diminished light touch	6

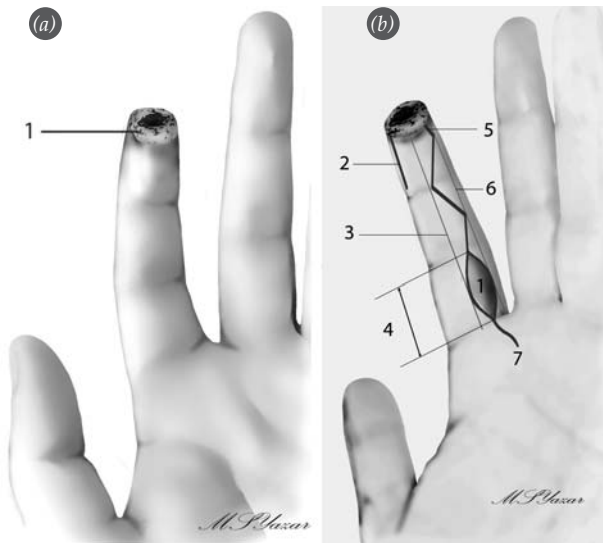


Fig. 1. (a) Finger-tip amputation. 1: View following debridement. (b) Homodigital island flap design. 1: Flap skin island, 2: Contralateral incision for nerve coaptation, 3: Mid-volar line 6: Mid-lateral line (3 and 6 designate the flap width), 4: Flap length borders (between proximal interphalangeal and metacarpophalangeal creases), 5. Zig-zag incision planned at region distal to the flap, 7: Proximal incision for the nerve transection.

The flap was then dissected over the paratenon distally to 5 mm proximal to the distal interphalangeal (DIP) joint with inclusion of the bundle (Fig. 2b).

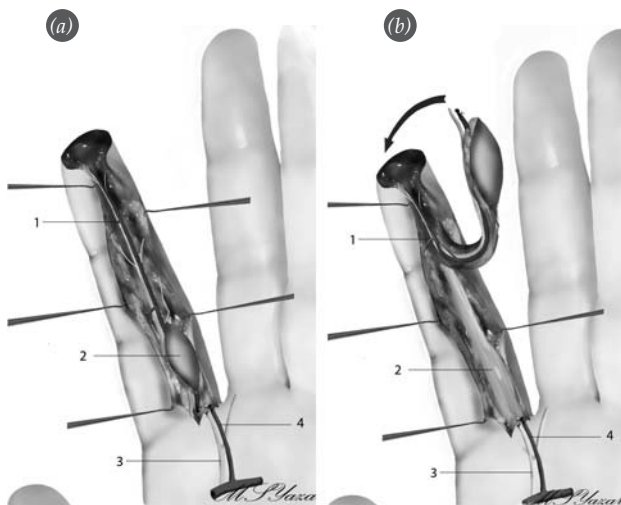


Fig. 2. (a) Flap dissection. 1: Distal digital bundle, 2: Flap, 3: Proximal digital nerve, 4: Proximal digital artery. (b) Flap harvesting over the paratenon. 1: Distal digital bundle, 2: Paratenon, 3: Proximal digital nerve, 4: Proximal digital artery.

After completion of the ipsilateral dissection, a contralateral mid-lateral incision was done where the digital nerve was identified and cut from an appropriate level. The flap inset was done later. The contralateral transected digital nerve was coapted to the recipient nerve in the flap (Fig. 3a).

The donor region was closed primarily (Fig. 3b). Skin edges close to the pedicle were approximated only loosely in order to prevent pedicle constriction (Fig. 4). A dorsal splint was applied with the hand in an anatomical position. The splint was removed 10 days later with the initiation of physiotherapy.

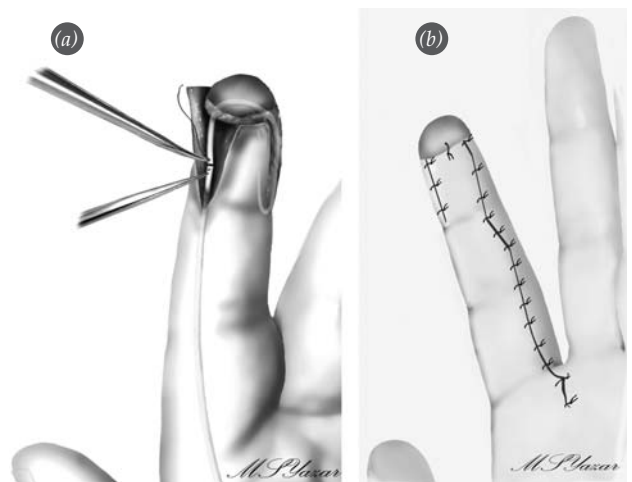


Fig. 3. (a) Nerve coaptation. (b) Final view of the finger.

Results

All of the patients were evaluated at 6, 12, and 18 months with Semmes-Weinstein monofilament and 2-point discrimination tests (Fig. 5, Table 1). In addition, cold intolerance, hypersensitivity at the donor and the recipient regions, cosmetic outcome, and patient satisfaction were evaluated (Fig. 6). On Semmes-Weinstein tests 64 fingers had normal sensation (value 2.83, corresponding to the green color), and 6 patients had decreased sensation (value 3.61, corresponding to the blue color); in average, 91.42% of the fingers had normal sensory recovery (Table 1).

Tactile sensation was evaluated with the Disk-Criminator to assess 2-point discrimination. Forty

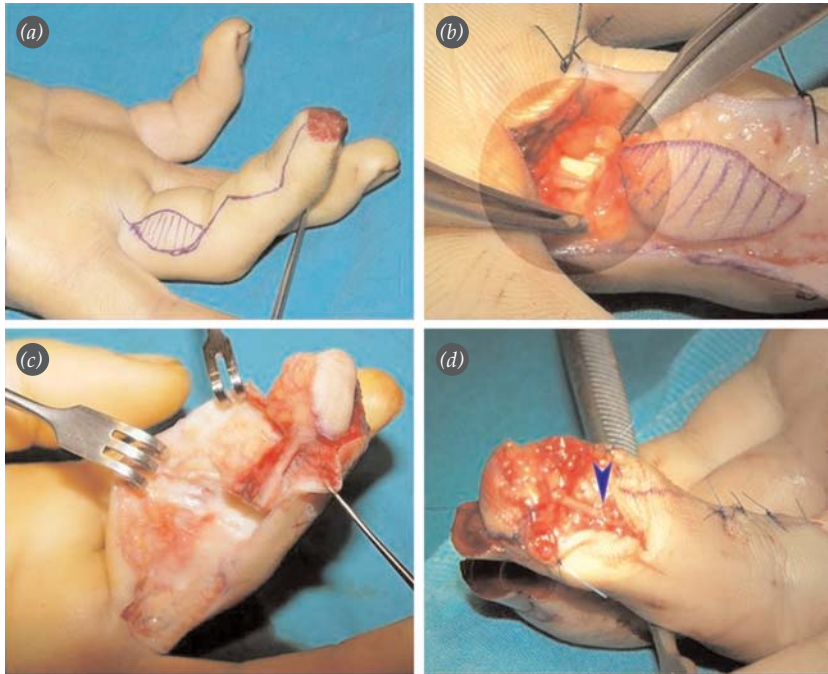


Fig. 4. Homodigital island flap. **(a)** Design of the reverse flow homodigital island flap at the non-dominant side of the finger following an amputation. **(b)** Incision made on the distal palmar crease with demonstration of the proximal bundle dissection. **(c)** Inclusion of the digital bundle together with the elevation of the flap over paratenon. **(d)** Coaptation of the included nerve to the contralateral nerve.

patients had normal values (<6 mm), and 30 patients had good-to-moderate values (6-10 mm). Values ranged between 4 and 9 mm, and the mean value was 5.7 mm (Table 1).

In terms of complications, two patients had neuromas. They refused reoperation, so they had desensitization therapy.^[8] Three patients had flexion contractures at the incision sites (Table 2). These contractures were released with Z-plasties (Fig. 7). One patient had a partial necrosis. Debridement was done,

and the wound healed secondarily. All the patients had a full range of motion. Cold intolerance was seen in seven patients (Table 2). All of the patients were satisfied with the cosmetic outcome (Fig. 6).

Discussion

One of the mostly commonly used classifications of fingertip amputations is the Tamai classification,^[9] in which the distal phalanx is divided into two regions. The region between the nail bed and distally to the

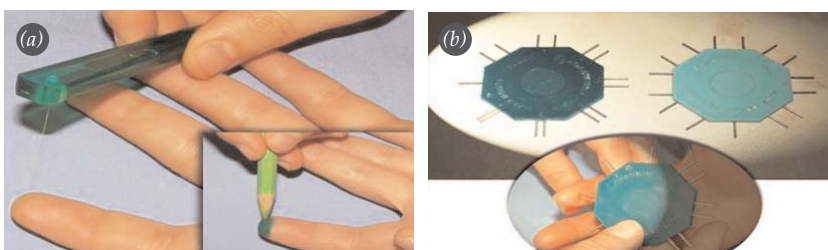


Fig. 5. **(a)** Semmes-Weinstein monofilament test. **(b)** Two-point discrimination test.

	Number of patients
Flap loss	1 (partial)
Cold intolerance	7
Hypersensitivity	2 (at flap)
Contracture	3 (at incision site)
Neuroma	2

fingertip is classified as Zone 1, and the zone between the nail bed and proximally to the DIP joint is designated as Zone 2. Although replantation is the best treatment method, it may not always be possible.^[10,11] Because of the importance of the fingertip

for the general function of the hand, many options have been proposed for reconstruction. In cases of bone or tendon exposition, initial options might be local flaps, such as the V-Y flap of Kutler and the Atasoy volar V-Y flap.^[1-3] In order to cover larger defects, cross-finger and thenar flaps have been proposed. Although these options seem to be logical, long-term immobilization of the hand may be a disadvantage for these flaps.^[4,5] As understanding of the vascular anatomy of the fingers has advanced, the option of using pedicle-based neurovascular island flaps has developed.^[12] It has been found that each palmar digital artery has deeper branches as well as superficial branches. Superficial branches mainly supply palmar subcutaneous tissues, and deep branches make anastomoses with the contralateral counterparts on proximal and middle phalanges.^[13]

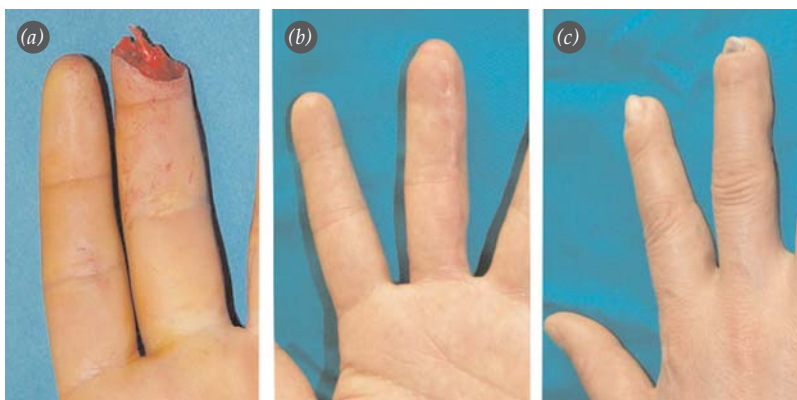


Fig. 6. (a) Preoperative view of the finger. Long-term (b) volar and (c) dorsal view of the same finger.

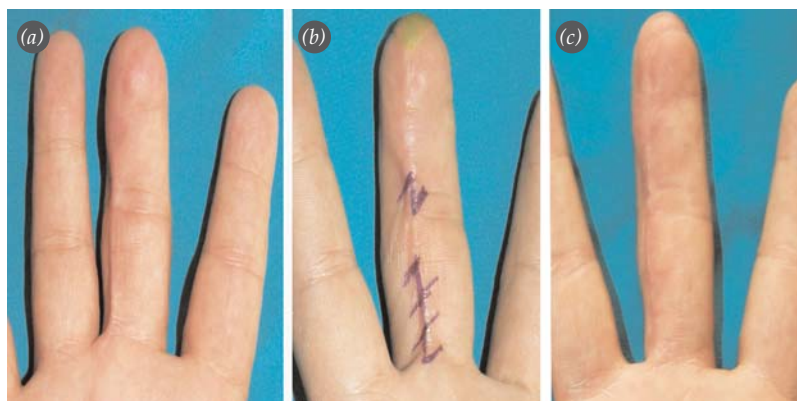


Fig. 7. (a-c) Release of the contracture following a homodigital island flap with Z-plasties.

These anastomoses, particularly at the level between the nailbed and the distal phalanx enable the homodigital island flap to survive retrogradely.^[14] Distal anastomosis is located between DIP joint and the fingertip. A retrotendinous vascular network is situated at the PIP joint and proximal to the DIP joint (Fig. 8).^[13] In cadaver studies, these anastomoses were found to be at the proximal phalanx and at the middle part of middle phalanx. Therefore, these flaps are contraindicated in injuries located proximal to the distal phalanx.^[14] These type of island flaps have certain advantages when compared to local flaps.^[15] They have a larger axis of rotation, which enables transfer of healthy tissue distant from the injury zone. A single step surgery confined to the damaged finger is another advantage. It also enables early mobilization. Healthy vascular tissue is transferred to the relatively poorly nourished area, enabling good wound healing. Cold intolerance risk might be reduced, as well. In addition, tactile sensation can be transferred to an anesthetic region.^[15] Transferred hairless palmar skin enables a better sensory recovery because of better alignment and greater numbers of myelinated fibers. Possible disadvantages are the sacrifice of the digital artery and the relative difficulty of the dissection and requirement of microsurgical skills.^[16,17]

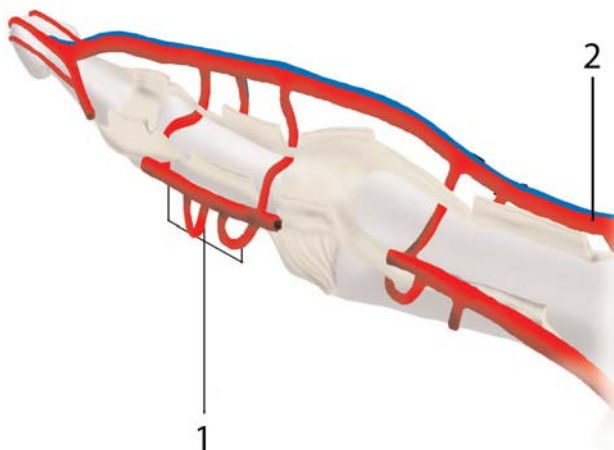


Fig. 8. Vascular anatomy of the finger. 1: Transverse commissural artery, 2: Proper digital artery.

Homodigital island flaps can be raised antegrade or retrograde. Antegrade flow homodigital island flap was first used by Kim et al.^[13] in 2001. This flap was based on transverse branch of proper palmar digital artery. The main advantage of this flap is the achievement of flap harvesting without sacrifice of one of the digital arteries. A disadvantage is that requirement of graft placement on the volar donor region might cause a contracture.^[17]

The reverse flow homodigital island flap was first described by Lai et al.^[6] in a study of 10 patients. Kojima et al.^[7] also used the same flap in a study of 8 patients. Three transverse commissural branches between 2 proper palmar digital arteries enable these flaps to survive. These arteries maintain a back-flow when one of the main digital arteries has been ligated proximally. These arteries might be located proximally on phalanx condyle and dorsal to the flexor tendons. This flap can be harvested from any place on the non-dominant side of the proximal and middle phalanges. In addition, the size of the flap can be increased in either the volar or dorsal direction, according to the size of the defect.

Sensory restoration can be obtained by two methods in island flaps. One method is increasing the dimension of the flap toward the dorsal side with inclusion of the dorsal digital nerve.^[18] The other option is the harvesting of digital nerve together with the digital artery. Included digital nerve can be coapted to the contralateral transected nerve. In cases where a dorsal digital nerve is included in the flap, the flap is composed of dorsal skin. As mentioned above, it does not have the advantages of volar skin, which is thicker and hairless; this may cause aesthetic and functional problems postoperatively. In the literature, no significant differences have been observed when cases with nerve coaptation were compared with non-coapted ones in terms of 2-point discrimination.^[19] However, in a study by Kaleli et al.,^[14] 2-point discrimination was found to be 5-7 mm in cases where nerve coaptation had been done; 2-point discrimination was 8-10 mm in cases

where nerve repair had not been done. In cases where nerve repair had not been done and dorsal digital nerve had been included, 2-point discrimination test was 9-10 mm.^[18] Sensory recovery, however, was observed to be worse when no digital nerve was included in the flap.^[15,20] The result of 2-point discrimination testing was 6.5 mm in a study by Lai et al.^[6] with 10 patients and also in a separate study by Alagöz et al.^[21] with 14 patients. Digital nerve was included in all flaps in that study. In our study, the digital nerve was included and coapted together with the homodigital island flaps. The 2-point discrimination test value was 5.7 mm, which was similar to values of previous studies.

In conclusion, sensation is indispensable for the hand. Therefore, sensory flaps should be used in reconstruction of fingertip injuries, where sensation is crucial. The reverse flow homodigital island flap may be an option for these cases.

References

- Goubier JN, Teboul F. Atasoy flap. *Interact Surg Am* 2007;2:116-7.
- Shepard GH. The use of lateral V-Y advancement flaps for fingertip reconstruction. *J Hand Surg Am* 1983;8:254-9.
- Venkataswami R, Subramanian N. Oblique triangular flap: a new method of repair for oblique amputations of the fingertip and thumb. *Plast Reconstr Surg* 1980;66:296-300.
- Tempest MN. Cross-finger flaps in the treatment of injuries to the finger tip. *Plast Reconstr Surg* 1952;9:205-22.
- Dellon A. The proximal inset thenar flap for fingertip reconstruction. *Plast Reconstr Surg* 1983;72:698-704.
- Lai CS, Lin SD, Yang CC. The reverse digital artery island flap for fingertip reconstruction. *Ann Plast Surg* 1989;22:495-500.
- Kojima T, Tsuchida Y, Hirasé Y, Endo T. Reverse vascular pedicle digital island flap. *Br J Plast Surg* 1990;43:290-5.
- Fisher GT, Boswick JA Jr. Neuroma formation following digital amputations. *J Trauma* 1983;23:136-42.
- Tamai S. Twenty years' experience of limb replantation--review of 293 upper extremity replants. *J Hand Surg Am* 1982;7:549-56.
- Dautel G, Barbary S. Mini replants: fingertip replant distal to the IP or DIP joint. *J Plast Reconstr Aesthet Surg* 2007;60:811-5.
- Özçelik İB, Purisa H, Sezer İ, Mersa B, Aydın A. The results of digital replantations et the level of the distal interphalangeal joint and the distal phalanx. *Acta Orthop Traumatol Turc [Article in Turkish]* 2006;40:62-6.
- Smith KL, Elliot D. The extended Segmüller flap. *Plast Reconstr Surg* 2000;105:1334-46.
- Kim KS, Yoo SI, Kim DY, Lee SY, Cho BH. Fingertip reconstruction using a volar flap based on the transverse palmar branch of the digital artery. *Ann Plast Surg* 2001;47:263-8.
- Kaleli T, Ersözülü S, Öztürk Ç. Double reverse-flow island flaps for two adjacent finger tissue defect. [Article in Turkish] *Arch Orthop Trauma Surg* 2004;124:157-60.
- Han SK, Lee BI, Kim WK. The reverse digital artery island flap: clinical experience in 120 fingers. *Plast Reconstr Surg* 1998;101:1006-11.
- Yıldırım S, Avcı G, Akan M. Complications of the reverse homodigital island flap in fingertip reconstruction. *Ann Plast Surg* 2002;48:586-92.
- Koshima I, Urushibara K, Fukuda N, Ohkochi M, Nagase T, Gonda K, et al. Digital artery perforator flaps for fingertip reconstructions. *Plast Reconstr Surg* 2006;118:1579-84.
- Tan O. Reverse dorsolateral proximal phalangeal island flap: a new versatile technique for coverage of finger defects. *J Plast Reconstr Aesthet Surg* 2010;63:146-52.
- Moschella F, Cordova A. Reverse homodigital dorsal radial flap of the thumb. *Plast Reconstr Surg* 2006;117:920-6.
- Orhun E, Öztürk K, Nuzumlalı E. The results of reverse digital artery island flap for fingertip injuries. [Article in Turkish] *Acta Orthop Traumatol Turc* 2000;34:147-51.
- Alagöz M, Uysal CA, Kerem M, Şensöz O. Reverse homodigital artery flap coverage for bone and nailbed grafts in fingertip amputations. *Ann Plast Surg* 2006;56:279-83.