



## Thrust plate prosthesis for proximal femoral deformity: a series of 15 patients

Vasfi KARATOSUN, Bayram ÜNVER,\* Alper GÜLTEKİN, İzge GÜNAL

*Dokuz Eylül University Faculty of Medicine, Department of Orthopedics and Traumatology, İzmir;*

*\*Dokuz Eylül University School of Physical Therapy and Rehabilitation, Department of Orthopedic Physiotherapy, İzmir*

**Objectives:** Patients with coxarthrosis and proximal femoral deformity experience problems with total hip arthroplasty. A custom-made prosthesis or a proximal osteotomy is required for such cases, and these also increase the rate of complications. The purpose of this study was to evaluate the results of the thrust plate prosthesis (TPP) in patients with deformity of the proximal femur.

**Methods:** Fifteen patients (7 females, 8 males) with a mean age of 56.4 years (range 19-75 years) at the time of the surgery were included in the study. The etiology was traumatic coxarthrosis in 12, and nonunion of a femoral neck fracture with osteonecrosis of the femoral head in the remaining three. While the femoral component was a third-generation TPP in all patients, the acetabular component was a Protek expansion cup in 12, and a cementless standard cup in three patients. All operations were performed through a Hardinge approach. Patients were followed up for at least 3 years (range 36-116 months) and evaluated clinically with the Harris Hip Score.

**Results:** The mean preoperative Harris Hip Score increased from 51.2 (range 15-79) to 92.7 (range 60-100) at the latest assessment. In two cases, loosening of the femoral component was observed in zone 3, both 12 months postoperatively. One was replaced by an intramedullary prosthesis, and the other was asymptomatic.

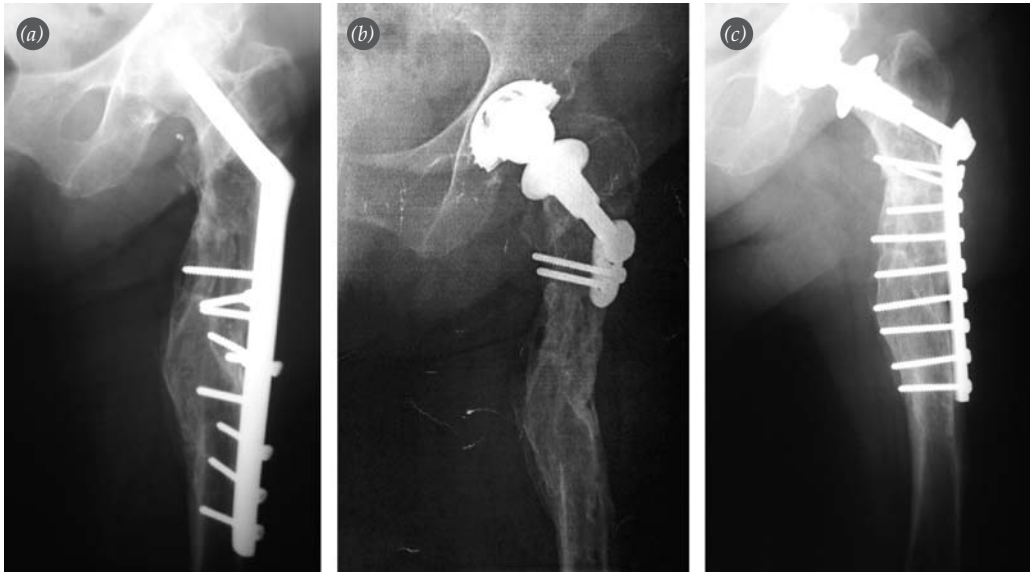
**Conclusion:** TPP is a good alternative for patients with deformations of the proximal femur. The use of TPP avoids technical difficulties and a custom-made prosthesis.

**Key words:** Coxarthrosis; hip; proximal femoral deformity; thrust plate prosthesis.

The anatomy of the proximal femur can change as a result of previous osteotomies, failed fracture fixations, or developmental dysplasias.<sup>[1]</sup> Distorted anatomy of the proximal femur may be problematic for surgeons who try to achieve a durable arthroplasty and an anatomically accurate reconstruction in primary or revision total hip arthroplasty (THA).<sup>[2,3]</sup> In such cases, custom-made prostheses or corrective osteotomies are required in order to adapt the pros-

thesis to the femur, or to adapt the femur to the prosthesis, but the complication rate following these procedures is extremely high, up to 50%.<sup>[1-11]</sup>

The thrust plate prosthesis (TPP), implanted primarily in Europe, is a cementless fixation in the metaphysis of the proximal femur.<sup>[12-14]</sup> TPP is an extramedullary type prosthesis, and is fixed to the lateral cortex of the femur. Thus, adaptation of the bone to the prosthesis (or vice versa) is not required.



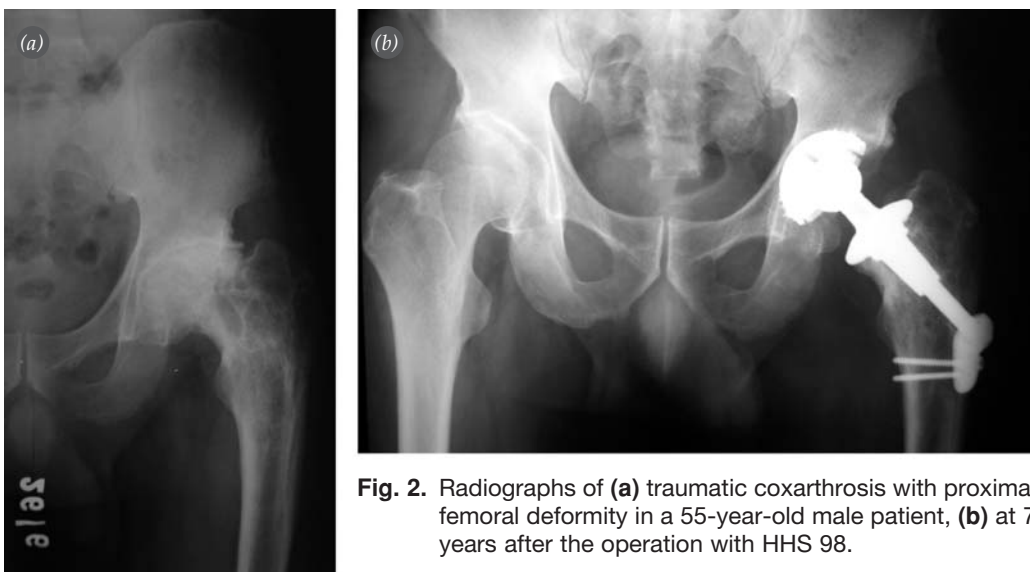
**Fig. 1.** Radiographs of (a) traumatic coxarthrosis with proximal femoral deformity in a 74-year-old female patient, (b) at 3 months after the operation with Harris Hip Score (HHS) score 82, and (c) at 5 years after the operation with HHS 95.

TPP theoretically can overcome the problems of a classical intramedullary type prosthesis in a distorted femur. However, there is no published study evaluating the outcome of TPP in patients with deformity of the proximal femur.

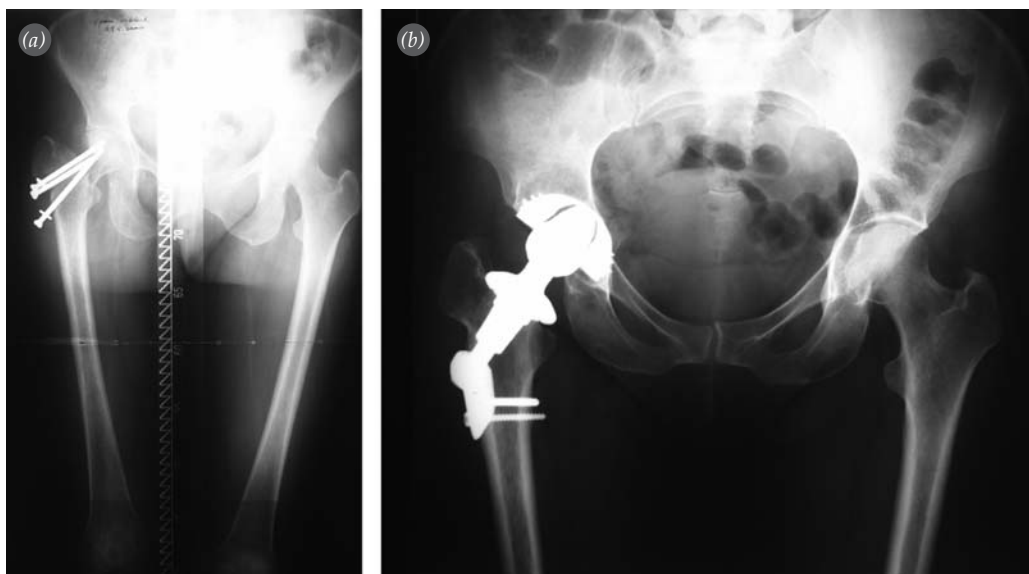
The purpose of this study was to evaluate our results with TPP in patients with deformity of the proximal femur, and to compare our observations with the results in the literature.

### Patients and methods

The series consisted of 15 hips in 15 patients who were prospectively followed for at least 3 years post-operatively. There were seven women and eight men with a mean age of 56.4 years (range 19-75 years) at the time of the surgery. The etiology was traumatic coxarthrosis in 12 and nonunion of a femoral neck fracture with osteonecrosis of the femoral head in the remaining three (Fig. 1-3).



**Fig. 2.** Radiographs of (a) traumatic coxarthrosis with proximal femoral deformity in a 55-year-old male patient, (b) at 7 years after the operation with HHS 98.



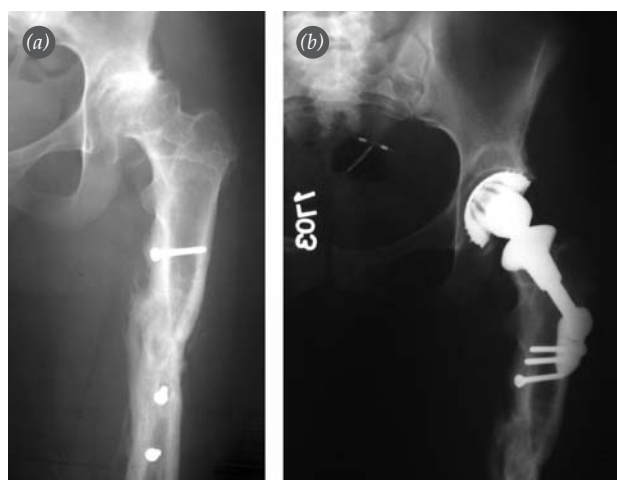
**Fig. 3.** Radiographs of (a) nonunion of a femoral neck fracture with osteonecrosis of the femoral neck in a 39-year-old female patient, (b) at 9 years after the operation with HHS 100.

While the femoral component was a third-generation TPP (Allopro, Sulzer Medica, Winterthur, Switzerland) in all patients (Fig. 4), the acetabular component was an Expansion Cup with a polyethylene insert (Protek, Sulzer Medica, Winterthur, Switzerland) in 12, and cementless metal-on-metal Standard Cup (Allopro, Sulzer Medica, Winterthur, Switzerland) in three hips. The femoral component was a long-plate TPP in one patient. All operations were performed through a Hardinge anterolateral approach, and TPP was implanted without cement to the metaphysis of the proximal femur, and was secured to the lateral cortex of the femur with a plate and screws.

All patients underwent an accelerated rehabilitation program. In the first seven consecutive patients, partial weight bearing was allowed on the second postoperative day and was gradually converted to full weight bearing at 6 weeks. In the remaining eight patients, full weight bearing was allowed from the day after the surgery.<sup>[15]</sup>

Patients were evaluated clinically with the Harris Hip Score (HHS) preoperatively and at 3, 6, 12, 18, and 24 months after surgery and every year thereafter. The HHS contains questions about pain, function, absence of deformity, and range-of-motion. The best possible score is 100 points.<sup>[16]</sup> We chose HHS because

it is more convenient in evaluating patients with a TPP. This is because the HHS has a larger effect size (than is seen in other scoring systems) without floor and ceiling effects.<sup>[17]</sup> The stability of the components was determined by the radiographs with special reference to the change in the position of the implant. Alternatively, the presence of radiolucent lines around the thrust plate and threaded bolt were noted using anteroposterior and lateral views of the hip.



**Fig. 4.** Radiographs of (a) traumatic coxarthrosis with femoral deformity and remnants of previous operation in a 32-year-old female patient, (b) at six years after the operation with HHS 100.

## Results

The patients were followed for a mean of 80.4 months (range 36-116 months) postoperatively. Mean preoperative HHS was 51.2 (range 15-79) and improved to 92.7 (range 60-100) at the latest follow-up (Fig. 4, Table 1). None of the patients complained of discomfort in the lateral aspect of the thigh.

In two cases, osteolysis around the femoral component was observed in zone 3, both 12 months postoperatively. One was replaced by a stemmed femoral prosthesis, and the other was asymptomatic. In one case, there was a periprosthetic fracture after 6 months due to significant trauma; the femoral component was replaced by a long lateral plate TPP, which was required because the fracture line extended distal to the level of the plate (Fig. 1).

## Discussion

A deformity of the proximal end of the femur can interfere with the performance of either a primary or a revision hip replacement.<sup>[10]</sup> Metaphyseal deformities in patients undergoing hip replacement may be

treated with femoral implants that bypass the deformity or with modular or custom implants tailored to fit the deformity, but hip replacement may require resection of the deformity.<sup>[5]</sup> Diaphyseal defects can have a important impact on implant alignment; in some cases, a short implant can be used, but major diaphyseal deformities may require femoral osteotomy.<sup>[5]</sup> These procedures are technically demanding and may have a significant rate of complications.<sup>[3]</sup>

TPP is a neck-sparing hip prosthesis with cementless fixation in the metaphyses of the proximal femur.<sup>[12-15,17-20]</sup> The aim is to provide a physiological force transmission into the calcar area in order to prevent stress shielding and subsequent aseptic loosening.<sup>[12-14,18-20]</sup> In addition, the design of TPP that is not inserted into the medullary canal seems to overcome the problems of an intramedullary type prosthesis. We reevaluated our results in such cases. Although the results are promising, there are some weak points of the study; the number of the patients is limited, and we had no control group. Such obstacles prevent more definitive conclusions.

**Table 1**

Demographic and clinical characteristics of the patients

Case no	Sex	Age	Etiology	Surgery date (month/year)	Complication	Preoperative Harris hip score	Harris hip score in the latest follow-up
1	Male	62	Traumatic coxarthrosis	09/1998	Osteolysis	42	96
2	Female	32	Traumatic coxarthrosis	05/1999	-	47	100
3	Female	70	Traumatic coxarthrosis	01/2000	-	42	93
4	Female	39	Nonunion	06/2000	-	79	100
5	Male	55	Traumatic coxarthrosis	09/2000	-	64	98
6	Male	73	Nonunion	11/2000	-	63	60
7	Male	62	Traumatic coxarthrosis	10/2001	-	15	93
8	Female	19	Nonunion	10/2001	-	51	100
9	Male	75	Traumatic coxarthrosis	10/2001	-	47	91
10	Male	45	Traumatic coxarthrosis	02/2002	-	72	98
11	Female	74	Traumatic coxarthrosis	06/2002	Periprosthetic fracture	57	89
12	Female	66	Traumatic coxarthrosis	06/2002	Osteolysis	34	78
13	Male	46	Traumatic coxarthrosis	09/2002	-	60	98
14	Male	66	Traumatic coxarthrosis	04/2003	-	48	97
15	Female	63	Traumatic coxarthrosis	12/2003	-	48	100

The rate of complications after THA with femoral osteotomy for proximal femoral deformity is extremely high. In the series of Papagelopoulos et al.,<sup>[3]</sup> 48% of patients had one or more complications, including loosening, perforation of the femoral canal, or nonunion at the site of osteotomy and dislocation, and 32% required reoperation.

The rate of aseptic loosening with cemented THA after osteotomy was found higher than in the general population.<sup>[8]</sup> Uncemented implants also may be at risk, primarily because deformity can compromise the initial fit and fixation of the prosthesis to bone.<sup>[3]</sup> Biomechanical studies have supported the concept that TPP transmits forces to the femoral cortex, identical to the process in intact bone in order to prevent stress shielding and subsequent loosening.<sup>[21]</sup> In the present series, only one patient required revision for aseptic loosening. Although this rate is not high, it is obvious that TPP does not totally eliminate the problem of aseptic loosening. On the other hand, we cannot compare our results with those of the other TPP series in the literature, because our study is the first to report TPP in patients with deformity of the proximal femur.

None of our patients experienced discomfort due to irritation of the fascia lata by the lateral strap or the bolt. The use of third generation TPP, which is made of titanium alloy with a smaller lateral strap, may prevent of lateral irritation.

Another important complication is femoral canal perforation during preparation of the canal, and the rate of such a complication reaches 23%.<sup>[3,4,8,9]</sup> We did not encounter such a complication, because no canal preparation is required for TPP.

Most cases of THA for proximal deformity requires osteotomy, and this increases risk of nonunion at the site of the osteotomy.<sup>[3,4,6,8,9]</sup> Avoidance of osteotomy by using TPP eliminates risk of nonunion.

Our study has some limitations. The study group is not homogeneous, which limits the applicability of our conclusions. On the other hand, our patients gained excellent HHS [92.7 (range 60-100) at the latest follow-up] with a low rate of complications. These results recommend TPP as an alternative tool in the treatment of patients with proximal femoral deformity.

## References

1. Cabanela ME. Proximal femoral deformity: bent but not broken. *Orthopedics* 2004;27:953-4.
2. Goldstein WM, Branson JJ. Modular femoral component for conversion of previous hip surgery in total hip arthroplasty. *Orthopedics* 2005;28:s1079-84.
3. Papagelopoulos PJ, Trousdale RT, Lewallen DG. Total hip arthroplasty with femoral osteotomy for proximal femoral deformity. *Clin Orthop Relat Res* 1996;(332):151-62.
4. Benke GJ, Baker AS, Dounis E. Total hip replacement after upper femoral osteotomy. A clinical review. *J Bone Joint Surg Br* 1982;64:570-1.
5. Berry DJ. Total hip arthroplasty in patients with proximal femoral deformity. *Clin Orthop Relat Res* 1999;(369):262-72.
6. Boos N, Krushell R, Ganz R, Müller ME. Total hip arthroplasty after previous proximal femoral osteotomy. *J Bone Joint Surg Br* 1997;79:247-53.
7. Cameron HU, Lee OB, Chou H. Total hip arthroplasty in patients with deficient bone stock and small femoral canals. *J Arthroplasty* 2003;18:35-40.
8. Ferguson GM, Cabanela ME, Ilstrup DM. Total hip arthroplasty after failed intertrochanteric osteotomy. *J Bone Joint Surg Br* 1994;76:252-7.
9. Haidukewych GJ, Berry DJ. Hip arthroplasty for salvage of failed treatment of intertrochanteric hip fractures. *J Bone Joint Surg Am* 2003;85-A:899-904.
10. Holtgrewe JL, Hungerford DS. Primary and revision total hip replacement without cement and with associated femoral osteotomy. *J Bone Joint Surg Am* 1989;71:1487-95.
11. Paavilainen T, Hoikka V, Solonen KA. Cementless total replacement for severely dysplastic or dislocated hips. *J Bone Joint Surg Br* 1990;72:205-11.
12. Karatosun V, Günal İ, Ünver B. Medium-term results of thrust plate prostheses for osteoarthritis of the hip. *Bull Hosp Jt Dis* 2005;63:28-30.
13. Yasunaga Y, Goto T, Hisatome T, Tanaka R, Yamasaki T, Ochi M. Bone-preserving prosthesis with a single axis for treating osteonecrosis of the femoral head: midterm results for the thrust plate prosthesis. *J Orthop Sci* 2003;8:818-22.
14. Huggler AH, Jacob HA, Bereiter H, Haferkorn M, Ryf C, Schenk R. Long-term results with the uncemented thrust plate prosthesis (TPP). *Acta Orthop Belg* 1993;59:215-23.
15. Ünver B, Karatosun V, Günal İ, Angin S. Comparison of two different rehabilitation programmes for thrust plate prosthesis: a randomized controlled study. *Clin Rehabil* 2004;18:84-91.
16. Harris WH. Traumatic arthritis of the hip after dislocation and acetabular fractures: treatment by mold arthroplasty.

- An end result study using a new method of result evaluation. *J Bone Joint Surg Am* 1969;51:737-55.
17. Ünver B, Karatosun V, Günel İ. Assessing the results of thrust plate prosthesis: a comparison of four different rating systems. *Clin Rehabil* 2005;19:654-8.
  18. Corner JA, Rawoot A, Parmar HV. The thrust plate prosthesis in the treatment of osteoarthritis of the hip. Clinical and radiological outcome with minimum 5-year follow-up. *Hip Int* 2008;18:88-94.
  19. Karatosun V, Günel İ, Ünver B. Thrust plate hip prosthesis: early results of a new concept in the femoral component of total hip arthroplasty. [Article in Turkish] *Acta Orthop Traumatol Turc* 2001;35:35-40.
  20. Karatosun V, Ünver B, Günel İ. Hip arthroplasty with the thrust plate prosthesis in patients of 65 years of age or older: 67 patients followed 2-7 years. *Arch Orthop Trauma Surg* 2008;128:377-81.
  21. Beretier H, Burgi M, Schenk R. Finite element investigations of the proximal femur after implantation of the thrust plate prosthesis compared with findings in a post-mortem histological specimen and in radiological follow-up examinations. In: Huggler AH, Jacob HAC, editors. *The thrust plate prosthesis*. Berlin: Springer; 1997. p. 48-62.