



A new technique in the treatment of distal radius fractures: the Micronail®

Ron Wilhelmus Petrus Maria GEERTS,¹ Hanneke Gerlinde TOONEN,²
Josephus Marinus Jacobus VAN UNEN,³ R. VAN VUGT,⁴ Andries Jan WERRE³

¹Department of Orthopedics, Orbis Medical Center, Sittard; The Netherlands;

²Department of Radiology, University Medical Center St. Radboud, Nijmegen; The Netherlands;

³Department of Surgery and Traumatology, Canisius Wilhelmina Hospital, Nijmegen; The Netherlands;

⁴Department of Surgery and Traumatology, University Medical Center St. Radboud, Nijmegen; The Netherlands

Objective: In 2006, an intramedullar titanium osteosynthesis for the stabilization of distal radius fractures was introduced in The Netherlands: the Micronail®. The Micronail® can be used in approximately 30% of distal radius fracture treatments. This article presents the introduction of this new treatment, and first clinical results.

Methods: In the first year after introduction of the Micronail® in our clinic, 10 patients have been treated with 11 Micronails® (eight 23-A2 radius fractures and three distal 22-A3 forearm fractures). Our patients were mainly woman (n=9) and had a mean age of 81 years (range 69-88 years). After re-alignment of the fracture, the Micronail® was placed into the medulla through a small incision over the styloid process of the radius. By using a guidance system, three locking buttress screws were placed in the distal radial fragment and two locking bolts were placed in the proximal radius. Postoperative treatment consisted of a splint for 5 days, after which full load-carrying exercises can be started.

Results: After 6 weeks, six patients had a full range of motion. Two patients were still in a cast because of secondary dislocation and CTS, respectively. One patient had a cast because of newly sustained trauma, which resulted in a peri-osteosynthetic fracture. Pain was not recorded in these patients. All fractures healed without major loss of alignment. Patients experienced good to excellent results on an analog scale showing the wrist function. At 4 months, all patients had a good range of motion in the operated wrist; the difference between the two wrists was a maximum of 10°.

Conclusion: The first results of Micronail® are promising. It has the advantages of other operative techniques (minimally invasive, stable, intramedullar) without their known disadvantages. Short immobilization is sufficient, after which full load-carrying exercises are indicated.

Key words: Micronail®; orthopedic fixation device; radius fractures.

The incidence of distal radius fractures in the Netherlands is more than 10,000 per year.^[1] Our hospital annually treats approximately 600 patients with a fractured wrist. Most of these fractures occur in elderly patients with a peak age at incidence between 60 and 69 years.^[2] Distal radius fractures in the elderly can be successfully treated conservatively.^[3]

However, operative treatment has the advantage of anatomical fixation and an earlier initiation of load-carrying mobilization. We operate on nearly one-fourth of wrist fractures at our hospital.

There are different types of operations for stabilization of distal radius fractures such as intrafocal

nailing, plating, and external fixation.^[1,4-6] These techniques are either percutaneous and only relatively stable or more stable using locking plates in an open technique or an external fixator.

A new device combines the benefits of these methods: the Micronail®. It is a minimally invasive device that reduces soft tissue damage, minimizes tendon irritation because of intramedullary positioning and provides proper stability of the fracture by using locking buttress screws. The Micronail® can be used in approximately 30% of distal radius fractures. It can be used for stabilization of dislocated extra-articular fractures (23-A2, 23-A3, distal 22-A3, and distal 22-B3) and even in a number of displaced intra-articular fractures (23-C1). In our hospital, this intramedullary fixation method has been used since 2006.




Fig. 1. The Micronail®. [Color figure can be viewed in the online issue, which is available at www.aott.org.tr]

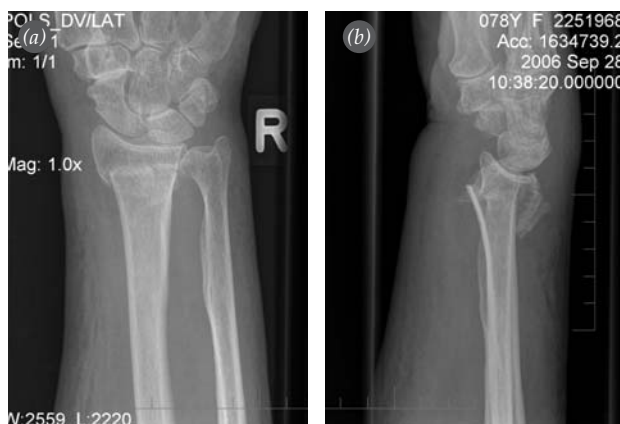

Fig. 2. Two-part dislocated fracture can be seen in radiographs of the right wrist in a 78-year-old female after a collapse. (a) Anteroposterior and (b) lateral views.

The purpose of this article was to present an introduction of this new treatment and our first clinical results.

Patients and methods

Population

Our group consisted of 10 patients, nine women and one man. All were treated in the first year in which the Micronail® was introduced in our clinic. Of all wrist fractures, 53% were treated with plating, 25% with intrafocal nailing, 17% with an external fixation, and 5% received a Micronail®. The mean age was 81 years (range 69-88 years). All fractures were classified according to the ASIF/AO Comprehensive Classification system.^[2] In seven patients, the indication for the Micronail® was a fracture of the radius (23-A2 fracture). One of these patients had a 23-A2 fracture on both sides. The remaining three patients received a Micronail® because of a distal 22-A3 fracture on their right side. Two of these patients also had a concomitant fracture; a distal radius (23-B2) fracture and a femoral neck fracture, respectively. These were treated with Kirschner wires (K-wire) and hemiarthroplasty respectively.

Material

The Micronail® (Fig. 1) is a minimal invasive intramedullary titanium pin fixation for two-part dislocated extra-articular fractures and average displaced intra-articular fractures. Use of the titanium Micronail® reduces soft tissue complications and supplies fixed-angle support.

Operation

The patient's fractured wrist (Fig. 2) was placed on a radiologic lucent arm support. Closed reduction and temporary fixation using a K-wire were performed if necessary. Subsequently, an incision 2 to 3 cm in length over the radial styloid process was made (Figs. 3-5). Care was taken not to harm the superficial branches of the radial nerve. Deep dissection was performed between the synovial sheaths of the extensor carpi radialis muscle and the combined synovial sheaths of the abductor pollicis longus and extensor pollicis brevis muscles until the periosteum was reached. Approximately 3 mm proximal to the radioscaphoid joint and centered, dorsal to ventral, a K-wire was inserted (Fig. 6a). A cannulated drill was inserted over this K-wire to create a cortical window

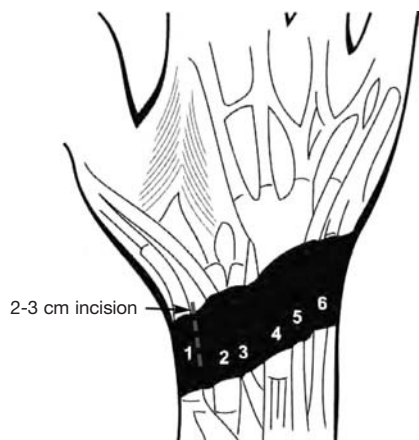


Fig. 3. Dorsal view of the incision location for placement of the broach.

(Fig. 6b). A broach was inserted through the cortical window into the medulla. During this introduction, the wrist was ulnar deviated to achieve better positioning. The tip of the broach was always in contact with the radial cortex. The broach was replaced by the Micronail®. Simultaneously, K-wire fixation just proximal of the subchondral bone was achieved. On the distal end of the Micronail® a guiding system for the distal buttress screws was placed (Fig. 7). With the use of this guiding system, three divergent screws were easily placed into the distal radius (Figs. 8 and 9).

By means of these three buttress screws, the distal fracture fragment was firmly attached with fixed-angle support. Finally, the Micronail® was attached to the proximal radius. With a proximal targeting guide, which was attached to the distal guiding system, the location for the proximal screws was determined (Fig. 10). Subsequently, the K-wires were removed because this was the last possibility to achieve optimal positioning of the different fracture parts. Two openings in the proximal targeting guide guided the drill through the cortex, towards the openings in the proximal part of the Micronail®; and stable situation was achieved (Fig. 11). Finally, the stability of the fracture and the range of motion needed to be tested and final radiographs were taken to ensure that no screws were placed in the distal radial ulnar joint or in the radiocarpal joint (Figs. 12 and 13).

Postoperative treatment and follow-up

Standard postoperative treatment consisted of a wrist splint for 5 days and finger motion was started imme-

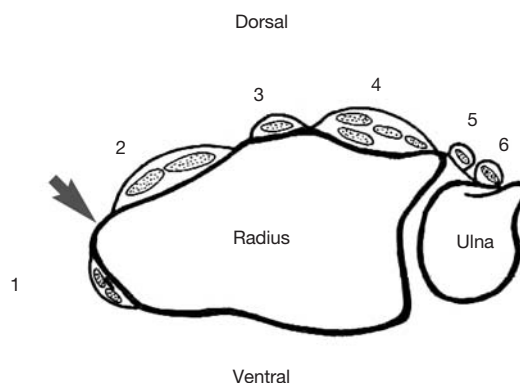


Fig. 4. Axial view of the incision location (arrow) for placement of the broach.

diately after operation.^[7] Approximately 1 week after surgery, the splint was removed, and radiographs were taken (Fig. 14). As long as there were no complications, load carrying physical therapy was initiated. If no bilateral wrist trauma had occurred, wrist function after Micronail® placement could be compared to the wrist on the non-operative side.

Clinical results were evaluated 4 months after surgery using the visual analogue scale (VAS). We asked patients if they were satisfied regarding the function of their operated wrist. They had to indicate, on an analogue scale, if they experienced the function of their operated wrist as being bad, poor, average, good or excellent. We also looked at the range of motion of the operated wrist, comparing it with the contralateral one. We analyzed the radio-

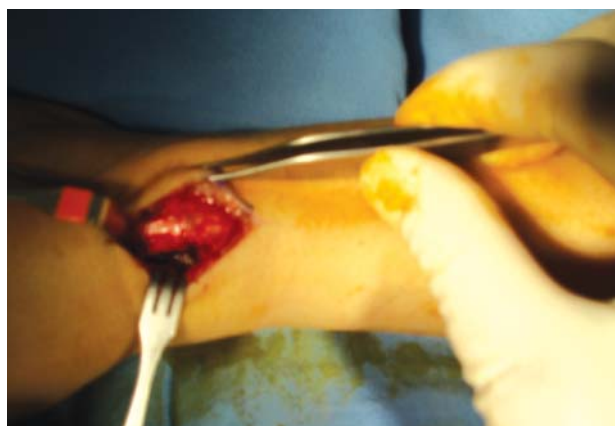

Fig. 5. Intraoperative view for placement of the broach. [Color figure can be viewed in the online issue, which is available at www.aott.org.tr]

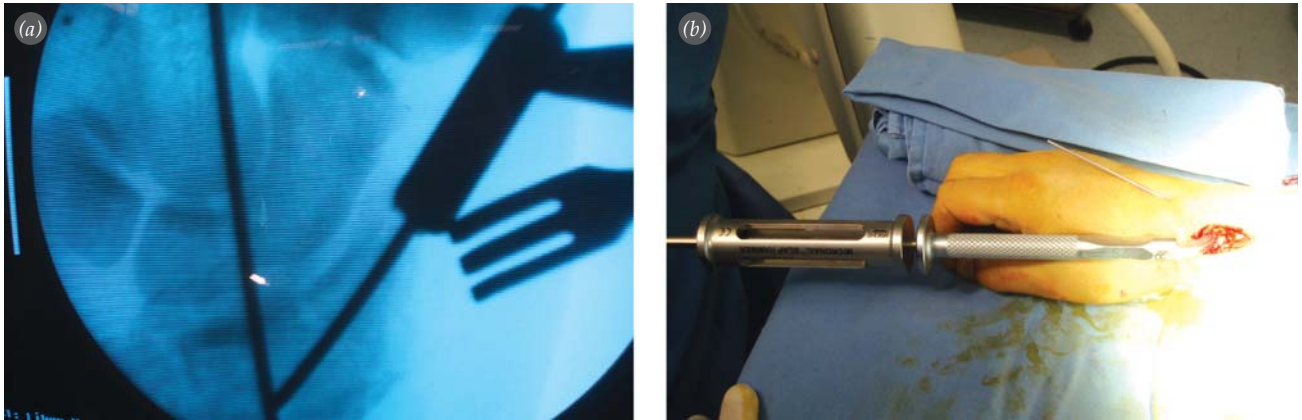


Fig. 6. (a) Placement of a K-wire under roadmap guidance and (b) intraoperative approach for the incision to place the Micronail® in the wrist. The cannulated drill is seen on (a). [Color figure can be viewed in the online issue, which is available at www.aott.org.tr]

logic outcome with regard to the union or occurrence of malunion. We also looked at the position of the Micronail®, to see if there was angulation, inclination or shortening in length due to the operation.

Results

Eleven Micronails® were placed in 10 patients. The mean operation time was 63 min (range 41-106 min).

Three out of 10 patients underwent bilateral surgery during the same operation. One patient received a Micronail® bilaterally with an operation time of 106 min. Two other patients had a concomitant contralateral distal radius (23-B2) fracture, which were treated with an external fixator or K-wire fixation.

The total operation time was 55 min and 98 min, respectively. The mean operation time for the seven unilateral patients was 52 min.

Although the placement of a Micronail® can be done in day-care surgery setting,^[8] only two patients were discharged the next day. One patient could be discharged after two days. The seven other patients, with multiple fractures and/or concomitant disease, stayed more than 10 days in our hospital.

In six patients, standard postoperative protocol was utilized. In four patients, however, we needed to deviate from the standard protocol. One patient received a circular underarm splinting cast to prevent complications and overstraining on the Micronail®

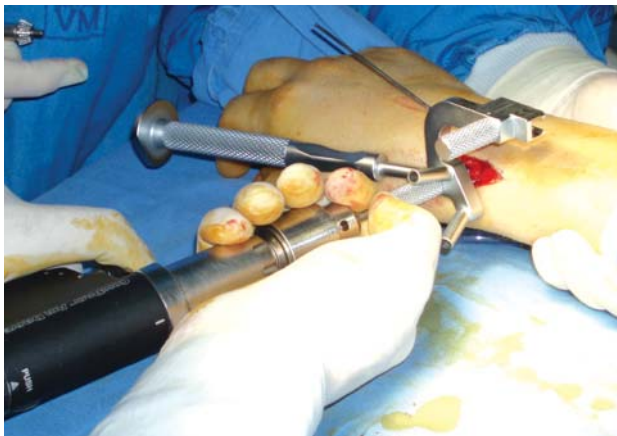

Fig. 7. Use of the guiding system. [Color figure can be viewed in the online issue, which is available at www.aott.org.tr]

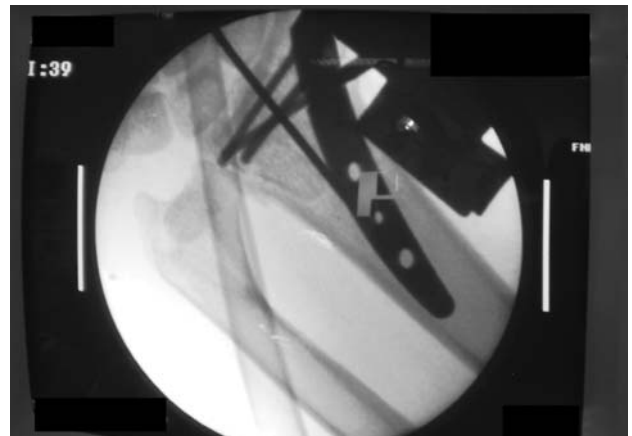


Fig. 8. Placement of 3 buttress screws under roadmap guidance.

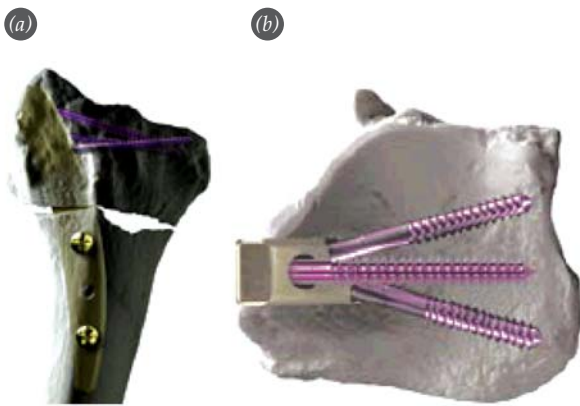


Fig. 9. Buttress screws (a) in anteroposterior view and (b) in distal fragment of the radius. [Color figure can be viewed in the online issue, which is available at www.aott.org.tr]

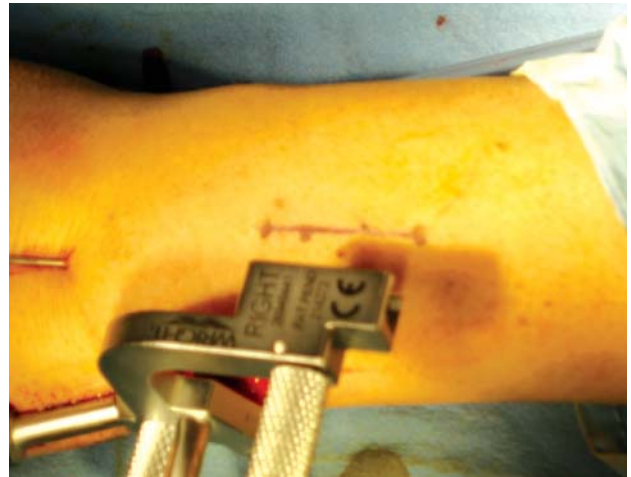

Fig. 10. Proximal screw placement using the proximal targeting guide. [Color figure can be viewed in the online issue, which is available at www.aott.org.tr]

because of her rheumatoid arthritis and a concomitant 23-B2 fracture of the wrist on the contralateral side, which was treated with an external fixator. This cast was removed after 2 weeks, and physical therapy could be started. Another patient initially received a cast splint, which was replaced after one week with a circular cast because of an accompanying fracture of the thumb. In the third patient, the fracture was secondarily dislocated during one-week follow-up, which was treated by closed reduction, after which this fracture was stabilized with a circular cast for another 6 weeks (Fig. 15). Fourth patient had, at the one week follow-up, complaints of pain for which longer cast immobilization was prescribed.

There were no preoperative complications. Two patients developed postoperative complications. One patient had carpal tunnel syndrome which was surgically released, and another patient had a secondary dislocation of the Micronail® (Figs. 15a-c).

The mean follow-up duration was 4 months (range 3-6 months). At 6 weeks, one patient still had a cast for a secondary dislocation, and another patient was recovering from a carpal tunnel release. One patient sustained a new trauma 9 weeks postoperative, which resulted in a peri-osteosynthetic fracture. All fractures healed without major loss of alignment (<5° or 2 mm).

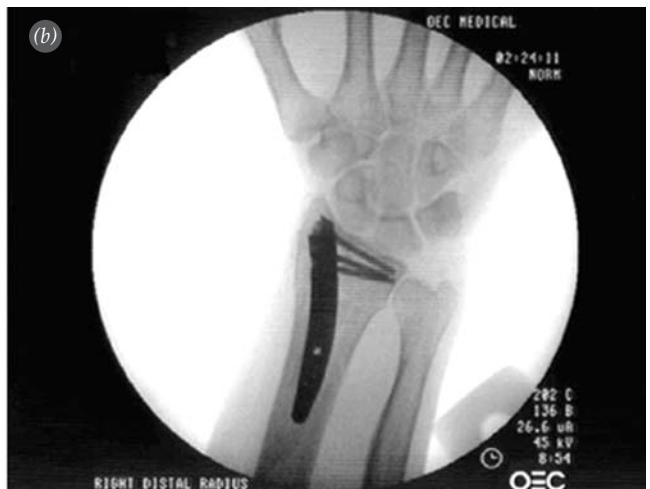
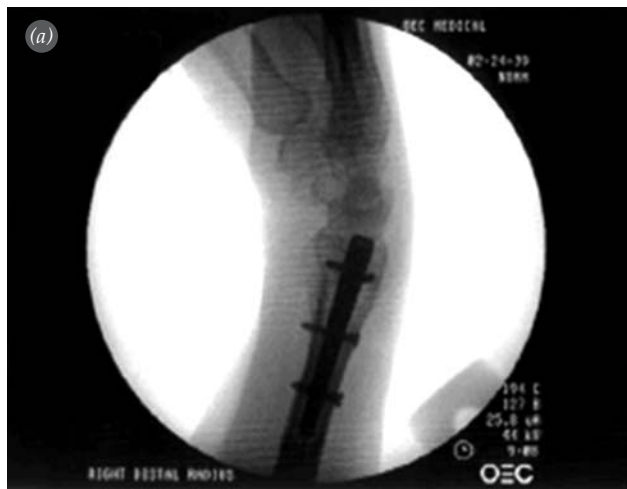
Fig. 11. (a) Lateral and (b) anteroposterior postoperative views under roadmap guidance.

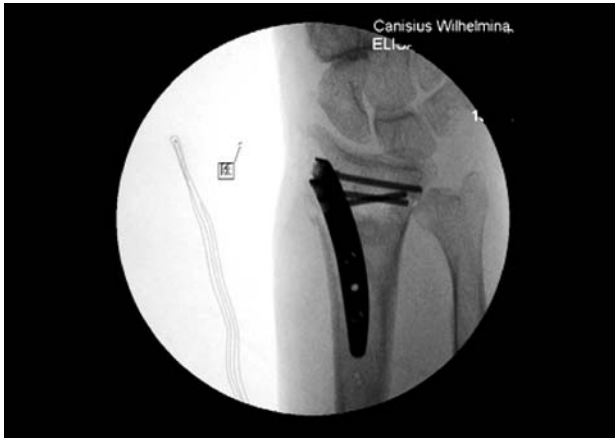

Fig. 12. Anteroposterior radioscopic view during surgery, after positioning the Micronail®.

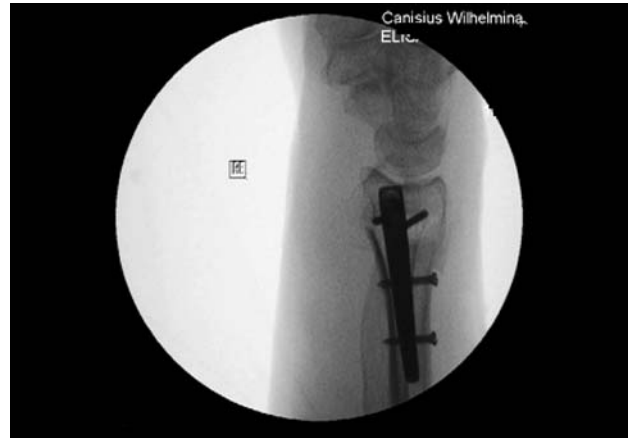

Fig. 13. Lateral radioscopic view during surgery after positioning the Micronail®.

At four-month follow-up, patients treated with the Micronail® experienced good to excellent results in function. Only one patient experienced impaired wrist function compared to the pre-trauma status. Patients had a pain sensation with a mean VAS score of 1.3 (range 0-3), suggesting that they almost did not experience any pain. In eight patients who did not have fracture in both wrists, the maximum difference in range of motion between the operative and non-operative site was slight, being zero to a maximum of 10° in all motions. The mean difference in range of motion in flexion was 5° (range 1° - 10°), for extension 5° (range 0° - 8°), for radial deviation 7° (range 6° - 10°), for ulnar deviation 3° (range 1° - 10°), for pronation 5° (range 3° - 8°), and for supination 5° (range 4° - 8°).

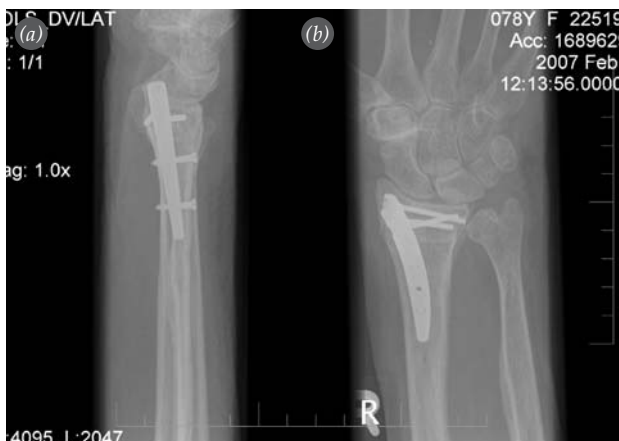

Fig. 14. Control radiographs of the wrist after four months follow-up. (a) Lateral and (b) anteroposterior views.

Discussion

The placement of a Micronail® is minimally invasive and easy to accomplish in daily surgical practice.^[7,8] This internal fixation method can be used in two-part extra-articular and mildly displaced intra-articular distal radius fractures.^[7] We used the Micronail® in the treatment of eight 23-A2 fractures and three distal 22-A3 fractures.

The mean age of our patients was 81 years (range 69-88 years), which is somewhat higher than the mean age in which most wrist fractures occur (range 60-69 years).^[2] This difference can be attributed to patient selection. All of our patients were known to have pre-existing osteoporosis and had a relatively low demand of their wrist function due to their small amount of activities in daily life.

Micronail® can be placed in day-care surgery center.^[7,8] However, only two of our patients could be discharged the next day after surgery. The elderly often have extensive comorbidities, which could affect postoperative recovery and thus time of admission. Treatment and complications of concomitant fractures have also influenced admission time. A decreased self-help capability due to multiple fractures and the waiting time for admission in a rehabilitation center or nursing home also prolonged hospital stays.

The time in which a Micronail® was placed (mean 52 min) was longer than the time it takes to place an external fixator or even plate osteosynthesis. However, at this moment, there is a learning curve.

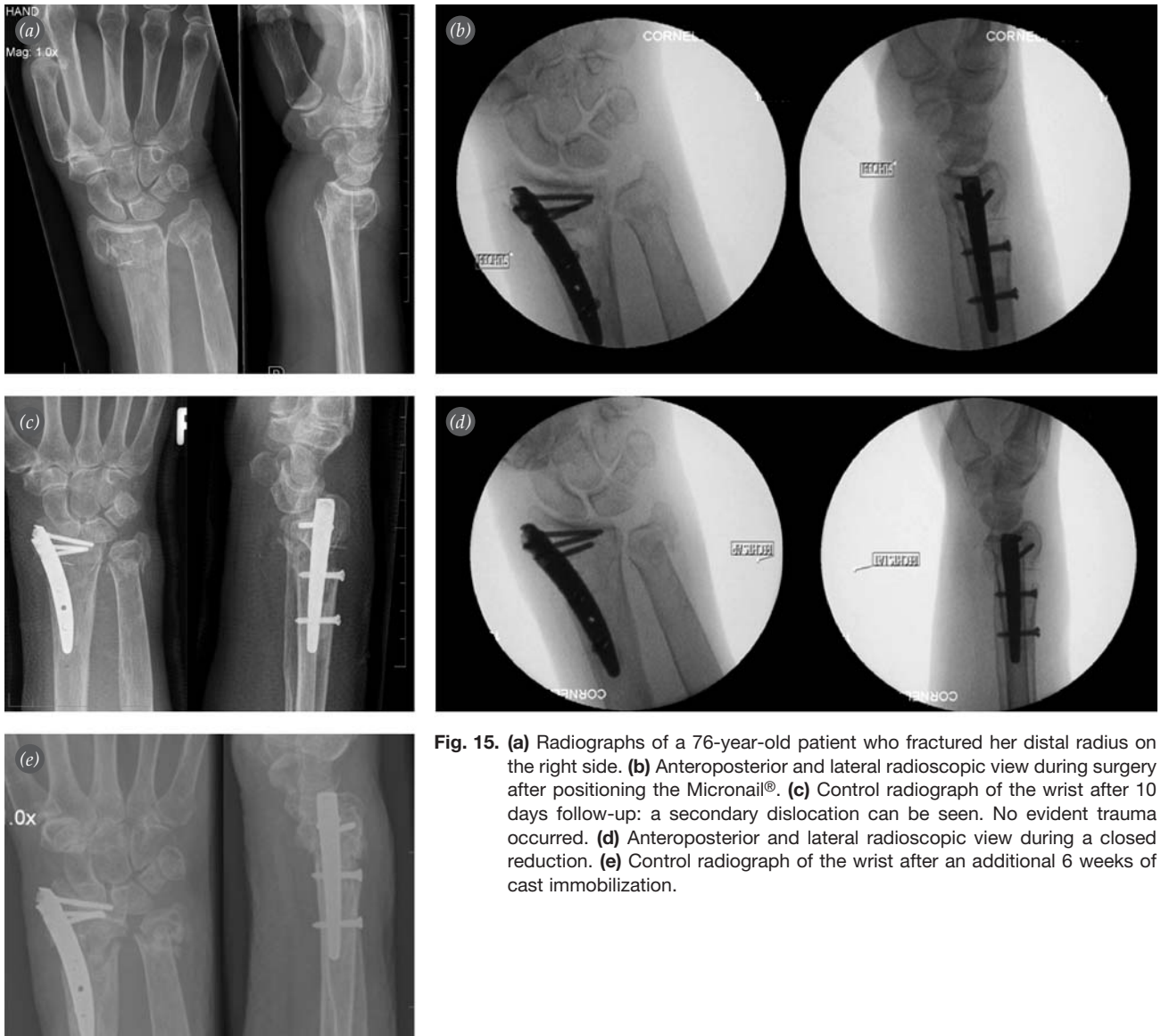

Fig. 15. (a) Radiographs of a 76-year-old patient who fractured her distal radius on the right side. (b) Anteroposterior and lateral radioscopic view during surgery after positioning the Micronail®. (c) Control radiograph of the wrist after 10 days follow-up: a secondary dislocation can be seen. No evident trauma occurred. (d) Anteroposterior and lateral radioscopic view during a closed reduction. (e) Control radiograph of the wrist after an additional 6 weeks of cast immobilization.

The operation time was shorter for the last patients compared to the first ones. We estimate that eventually we can successfully place a Micronail® in the same time as volar plating with a locking plate system.

Normal postoperative treatment consisted of a splint for 5 days for proper wound healing. However, we encountered four situations in which we deviated from this standard protocol. One patient had pre-existing rheumatoid arthritis and concomitant fractures. She was given a circular underarm cast for 2 weeks to prevent overstraining of the Micronail®. Second patient had a concomitant fracture of the thumb in the ipsilateral hand for which

she needed a cast. Another patient complained of more than average pain for which we continued splint immobilization for another week. It was not clear if this pain was due to the placement of the Micronail®. The Micronail® in the fourth patient showed secondary dislocation for which a closed reduction and a circular cast for another 6 weeks were indicated (Figs. 15a-e).

In two of the 11 placed Micronails®, postoperative complications occurred. One patient developed carpal tunnel syndrome, which is common after trauma of the wrist.^[9] Carpal tunnel syndrome also occurs in 5% of patients with conservatively treated

distal radius fractures.^[10,11] A study of 3,391 patients showed an odds ratio of 2.29 for developing carpal tunnel syndrome after fracturing the wrist.^[12] The Micronail® in a second patient revealed secondary dislocation with a clear cause. She was known to have osteoporosis and could not be properly instructed due to her mental status. Because of her comorbidities, she constantly overstrained her wrist. Other studies have also found osteoporosis to be a risk factor for secondary dislocation.^[13]

After 6 weeks of follow-up, 64% of the wrists (n=7) had nearly unrestricted range of motion. After 4 months of follow-up, all patients had a full range of motion. These results have also been reported in the United States^[7,8] and are promising.

In 11 distal radius fractures, a Micronail® was placed. They accounted for eight 23-A2 fractures and three 22-A3 fractures. Prognosis in these two different fracture types did not differ. All patients (except the one with newly sustained trauma) at 4 months follow-up had an unrestricted function of the wrist. Data on long-term results are currently being assembled.

The indication for Micronail® placement was AO-classification and bilateral trauma (one wrist would be immobilized for a longer period of time) or fractures with a poor prognosis which could not effectively be reconstructed using minimally invasive methods. Because of the introduction of this new technique, only one surgeon in the Netherlands was capable of placing the Micronail® during the time period of this study.

Two patients sustained bilateral trauma to the wrist. When treated with a Micronail®, earlier load carrying capacity of the injured wrist can be achieved. When only one extremity was fractured, the indication of Micronail® placement was 23-A2 radius fractures or distal 22-A3 forearm fractures in which consolidation prognosis was poor because of the angle of the fracture.

Although there is growing popularity for surgical treatment of distal radius fractures, a recent Cochrane database review did not provide robust evidence for the decision-making.^[14] There is some evidence for the support of some treatment options, but their precise roles are not established, nor are the long-term outcomes. A relatively new concept in adults is intramedullary fixation.^[15,16]

Infections of the osteosynthesis materials, as often occurs in percutaneous or external fixation techniques, were not seen. Most fixators are transarticular, resulting in tissue irritation and finger motion problems secondary to tendon adhesion. Gripping activities may reduce and fixating the wrist in flexion may even compress the median nerve. According to the patient's opinion and the VAS score, treatment by Micronail® was satisfying. Patients experienced good-to-excellent function of their fractured wrists, and the pain sensation was low, with a mean VAS score of 1.3. All patients experienced an almost full range of motion of their wrists. Radiologic results were also acceptable, without major loss of alignment ($<5^\circ$ or 2 mm).

Our results are comparable with the results of patients who underwent volar plating, considering ranges of motion, postoperative pain, and radiologic outcome.^[14,17-19] Complications in our study, as mentioned previously, also happen in surgeries using volar plating.^[20]

A negative aspect of this surgical procedure is the cost. Six weeks of plaster casting treatment is less expensive than surgery.

The positive effects of the Micronail® (earlier load carrying capacity and with that earlier return to normal daily living), taking the costs in mind, is best suited for patients with active daily living. In a selected population, placement of a Micronail® can be more effective, and therefore more profitable, than the already existing, and more common, osteosynthesis.

Research in younger populations is necessary because we believe that younger patients, in comparison to the elderly, will benefit more from the Micronail®. This is because they have higher demands of wrist function and the greater amount of usage of the wrist in modern society.

Our first results were promising, and few complications were seen. Using the Micronail® for a longer period of time will show us if this new device has additional value to the already existing osteosynthesis. Because of the small patient group, no definitive conclusions could be drawn from our results. Further investigations should be done with larger patient populations.

The Micronail® combines the advantages of other fixation methods. The minimally invasive technique results in less soft tissue damage. Because of the use of intramedullary locking screws, the wrist can be fully strained one week after surgery, and the expected range of motion is at least as good as with other known fixation methods. The placement of this intramedullary fixator can be done in 41 min and in day-care surgery setting.

The results in our first ten patients are promising. All interventions were applied without complications, and few postoperative complications were seen. Furthermore, all patients at 4 months follow-up had an unrestricted range of motion.

As a conclusion, this minimally invasive technique is suitable in selected, two-part dislocated extra-articular and in mildly displaced intra-articular distal radius fractures.

Acknowledgement

We thank Rafael Delgado, MD (Madrid, Spain) for his efforts to help us finalize this article.

Conflicts of Interest: No conflicts declared.

References

1. Brink PRG. Distale radiusfractuur. *Ned Tijdschr Traumatologie* 2007;15:55-63.
2. www.aofoundation.org
3. Young BT, Rayan GM. Outcome following non-operative treatment of displaced distal radius fractures in low-demand patients older than 60 years. *J Hand Surg Am* 2000;25:19-28.
4. Strohm PC, Müller CA, Boll T, Pfister U. Two procedures for Kirschner wire osteosynthesis of distal radius fractures. A randomized trial. *J Bone Joint Surg Am* 2004;86-A:2621-8.
5. Hargreaves DG, Drew SJ, Eckersley R. Kirschner wire pin tract infection rates: a randomized controlled trial between percutaneous and buried wires. *J Hand Surg Br* 2004;29:374-6.
6. Zamzuri Z, Yusof M, Hyzan MY. External fixation versus internal fixation for closed unstable intra-articular fracture of the distal radius. Early results from a prospective study. *Med J Malaysia* 2004;59:15-9.
7. Tan V, Capo J, Warburton M. Distal radius fracture fixation with an intramedullary nail. *Tech Hand Up Extrem Surg* 2005;9:195-201.
8. Brooks KR, Capo JT, Warburton W, Tan V. Internal fixation of distal radius fractures with novel intramedullary implants. *Clin Orthop Relat Res* 2006;(445):42-50.
9. Ruch DS, Yang CC, Smith BP. Results of acute arthroscopically repaired triangular fibrocartilage complex injuries associated with intra-articular distal radius fractures. *Arthroscopy* 2003;19:511-6.
10. Hove LM, Mölster AO. Surgery for posttraumatic wrist deformity. Radial osteotomy and/or ulnar shortening in 16 Colles' fractures. *Acta Orthop Scand* 1994;65:434-8.
11. Kato N, Nemoto K, Arino H, Fujikawa K. Multiple neurilemmomas of the median and ulnar nerves with a communicating branch in the same upper extremity. *Scan J Plast Reconstr Surg Hand Surg* 2002;36:314-5.
12. Geoghegan JM, Clark DI, Bainbridge LC, Smith C, Hubbard R. Risk factors in carpal tunnel syndrome. *J Hand Surg Br* 2004;29:315-20.
13. Bass RL, Blair WF, Hubbard PP. Results of combined internal and external fixation for the treatment of severe AO-C3 fractures of the distal radius. *J Hand Surg Am* 1995;20:373-81.
14. Handoll HH, Madhok R. Surgical interventions for treating distal radial fractures in adults. *Cochrane Database Syst Rev* 2003;(3):CD003209.
15. Orbay JL, Touhami A, Orbay C. Fixed angle fixation of distal radius fractures through a minimal invasive approach. *Tech Hand Up Extrem Surg* 2005;9:142-8.
16. Pritchett JW. External fixation or closed medullary pinning for unstable Colles fractures. *J Bone Joint Surg Br* 1995;77:267-9.
17. Protopsaltis TS, Ruch DS. Volar approach to distal radius fractures. *J Hand Surg Am* 2008;33:958-65.
18. Musgrave DS, Idler RS. Volar fixation of dorsally displaced distal radius fractures using the 2.4-mm locking compression plates. *J Hand Surg Am* 2005;30:743-9.
19. Osada D, Kamei S, Masuzaki K, Takai M, Kameda M, Tamai K. Prospective study of distal radius fractures treated with a volar locking plate system. *J Hand Surg Am* 2008;33:691-700.
20. Berglund LM, Messer TM. Complications of volar plate fixation for managing distal radius fractures. *J Am Acad Orthop Surg* 2009;17:369-77.