



# Efficacy of 5-Fluorouracil in inhibition of unintended bone formation in spinal surgery: a histological evaluation on a rat model of spontaneous spinal fusion

Esat KITER<sup>1</sup>, Ertan ER<sup>2</sup>, Nilay ŞEN TÜRK<sup>3</sup>, Murat OTO<sup>1</sup>, Semih AKKAYA<sup>1</sup>

<sup>1</sup>Department of Orthopedics and Traumatology, Pamukkale University Faculty of Medicine, Denizli, Turkey;

<sup>2</sup>Department of Orthopedics and Traumatology, Acıpayam State Hospital, Denizli, Turkey;

<sup>3</sup>Department of Pathology, Pamukkale University Faculty of Medicine, Denizli, Turkey

**Objective:** The aim of this study was to investigate the influence of the antiproliferative agent 5-Fluorouracil (5FU) over inhibition of spinal bone formation in an experimental rat model.

**Methods:** The study included 30 6-month-old Sprague-Dawley rats divided into 3 groups. Aggressive periosteal denuding was performed by scalpel to induce punctuate bleeding in the posterior elements of the L4-L5 vertebrae in the spontaneous fusion model. Spinous processes were fixated by wires and no graft substitute was applied. Adcon-L was applied in Group 1, single-touch technique 5FU in Group 2. Group 3 was the control group. Rats were sacrificed at 4 weeks and specimens acquired for histological examination.

**Results:** 5FU substantially inhibited fibroblast and inflammatory cell densities as well as bone formation compared to the control group. 5FU was considerably superior to Adcon-L with regard to inhibition of bone formation and inflammatory cells ( $p=0.0001$ ).

**Conclusion:** 5FU can inhibit fusion, fibrosis and unwanted scar tissue in spinal surgery. We believe that after further studies on its local delivery dose, it can be used in humans for inhibition of unintended fusion.

**Key words:** 5-Fluorouracil; inhibition of spinal fusion; spontaneous spinal fusion.

In spinal surgery, with the exception of prosthetic implants, fusion is a desired outcome in all but two procedures. Generally, surgical interventions on immature spines (<10 years of age) are not performed with the intent of achieving fusion. Observation of spinal decompression or short spinal height in fusions performed on young patients has indicated the need for non-fusion techniques. The main target of these techniques is to

spare the spine from excessive deformation until the definitive fusion procedure or adequate maturation of the spine. However, unintended spontaneous fusions associated with the surgical exposure of the immature spine may arise as even a periosteal scratch can generate fusion in an immature spine.<sup>[1-7]</sup> Fusion is also an undesired outcome in decompression surgery for the treatment of degenerative spinal disease. In degenerative spinal dis-

**Correspondence:** Esat Kiter, MD. Pamukkale Üniversitesi Tıp Fakültesi, Ortopedi ve Travmatoloji Anabilim Dalı, 20070 Kınıklı, Denizli, Turkey.

Tel: +90 258 – 296 24 02 e-mail: esatkiter@gmail.com

**Submitted:** January 15, 2013 **Accepted:** July 10, 2013

©2014 Turkish Association of Orthopaedics and Traumatology

Available online at  
www.aott.org.tr  
doi: 10.3944/AOTT.2014.3161  
QR (Quick Response) Code



eases which necessitate fusion and decompression, post-operative restenosis may present a problem. Although not proven, the presence of a potential risk for restenosis is considered in cases in which osteogenetic agents such as bone morphogenetic protein (BMP) are used.<sup>[8-10]</sup>

Since spinal fusion is generally desired, many studies in the literature have focused on the negative influence on fusion of various drugs and prevention of this effect. Therefore, only a limited numbers of studies have been designed to create fusion inhibition. In the literature, studies evaluating the inhibition of fusion by application of local agents have assessed the impacts of fibrin sealant and Adcon-L.<sup>[10,11]</sup> Different opinions on the effects of fibrin sealant on fusion have been reported and studies have indicated a positive impact on fusion by holding the graft substitutes together.<sup>[12]</sup> Adcon-L is a biomaterial used for the inhibition of adhesion and fibrosis based on the theory that it prevents migration of proliferative cells to the lesion site. It has been shown to inhibit fusion based on the same principle.<sup>[11]</sup> In recent decades, the classical antiproliferative agent 5-Fluorouracil (5FU) has been increasingly used for prevention of fibrosis in ophthalmological procedures and hand surgery. We hypothesized that 5FU may be as effective as Adcon-L in the inhibition of spinal fusion.

The aim of the present study was to investigate the inhibitory effect on spinal fusion of local application of 5FU using a rat model.

## Materials and methods

This study was conducted with approval of the Local Ethics Committee for Research on Animals of our institute.

Posterior spine exposure was performed on the thoracic region of two 2-week-old immature Sprague-Dawley rats in order to simulate a valid model for spontaneous spinal fusion. Subperiosteal denuding was applied to all muscles using a scalpel. Animals were sacrificed 4 weeks later. No osseous or fibrous proliferations were observed. For this reason, spinous process wiring was integrated to the procedure in an additional 2 immature rats in order to achieve a more proper spontaneous fusion model. However, optimum fixation was not achieved due to small posterior elements. Two 6-month-old Sprague-Dawley rats were subjected to aggressive subperiosteal denuding and spinous process wiring. Wires were removed at the postoperative 4th week. This process was recognized as the study model after observation of significant proliferative changes when compared to the un-operated segments.

This study included 30 6-month-old Sprague-Dawley rats, divided into 3 groups. Group 1 received Adcon-L (Adcon-L Adhesion Control Gel<sup>®</sup>; Gliatech Inc., Cleveland, OH, USA), Group 2 5FU (5-Fluorouracil<sup>®</sup>; Choongwae Pharma Corp., Seoul, South Korea) and Group 3 was the control group.

Following anesthesia with 10 mg/kg xylazine hydrochloride (Rompun<sup>®</sup>; Bayer AG, Leverkusen, Germany) and 40 mg/kg ketamine hydrochloride (Ketalar<sup>®</sup>; Eczacibasi, Istanbul, Turkey), the operation site was shaved and prepared for the surgery under sterile conditions. After the midline incision, posterior elements of the L4-L5 lumbar spine were reached and muscles were denuded. During the denuding process, cautery was not used. The entire muscle tissue and bone periosteum were denuded by scraping with a scalpel until observation of punctate bleeding over the lamina. Wires of 0.3-mm thickness were used on the spinous processes for the L4-L5 fixation. In Group 1, 50  $\mu$ l Adcon-L was applied using its own apparatus on the exposed posterior elements of the L4-L5 vertebrae. In Group 2, 5FU was applied on the vertebrae by a sponge with single-touch technique<sup>[13]</sup> for 5 minutes following irrigation of the operation site with 10 ml saline. Group 3 (control group) received only 10 ml saline over the operation site.

Postoperative ambulatory activities and wound healing were monitored daily. None of the groups displayed neurological deficit, infection or difference in cutaneous healing. Rats were sacrificed by intravenous high-dose sodium pentothal (100 mg/kg) at postoperative 28 days and the entire lumbar vertebrae were excised en bloc through the former incision for histological examination.

Vertebrae were fixed in a 10% formaldehyde solution and decalcified with 10% formic acid and 8% HCl for 2 days. Sections of 5  $\mu$ m thickness were prepared from the specimens and stained with hematoxylin-eosin (HE) and Masson's trichrome (MT).

Cells were counted in 3 different fields of 3 sections for each subject. Similarly, inflammatory cells (polymorphonuclear cells, lymphocytes and monocytes) were counted under x400 magnification. He and Revel's criteria were used to calculate the density of the fibroblasts in the scar tissue.<sup>[14]</sup> New bone formation and neovascularization were assessed microscopically according to the criteria of Emery et al.<sup>[15]</sup> (0-3: no new bone - maximum new bone, and 0-3: no neovascularization - maximum neovascularization) (Table 1). Preparations were histopathologically evaluated with regard to degree of scarring, inflammation, infection and Adcon-L resorption.

**Table 1.** The 5FU Group shows significant difference with regard to inhibition of inflammatory cell density and new bone formation.

Groups	1	2	3	4	5	6	7	8	9	10	Average
New Bone Formation*											
Adcon-L	3	3	3	3	3	3	3	3	2	3	
5FU	0	0	2	0	0	3	0	0	0	0	
Control	2	3	3	3	1	0	2	2	3	0	
Fibroblast density†											
Adcon-L	161	129	175	138	117	69	134	113	76	103	121.5
5FU	115	95	130	131	144	125	111	98	140	110	119.9
Control	292	210	157	204	242	199	158	186	218	141	200.7
Inflammatory cell density‡											
Adcon-L	4	15	4	5	15	25	15	2	20	12	11.7
5FU	4	3	2	1	2	2	1	1	1	1	1.8
Control	5	5	3	4	6	19	7	3	4	3	5.9
Neovascularization§											
Adcon-L	2	2	2	2	2	3	2	2	2	2	
5FU	1	2	2	2	1	2	2	2	2	2	
Control	2	2	2	3	2	2	2	2	2	2	

\*Semi-quantitative assessment of the new bone formation was based on Emery et al.'s<sup>[15]</sup> criteria. 0: No new bone formation, 1: Minimal bone formation, 2: Mild bone formation, 3: Maximal bone formation. †Fibroblast count was performed in three different fields of three sections for each subject under x400 magnification and the average value of those counts was used. ‡Polymorphonuclear cells, lymphocytes, and monocytes were counted in three different fields of three sections for each subject under x400 magnification and the average value of those counts was used. §Assessment of neovascularization was based on Emery et al.'s<sup>[15]</sup> criteria. 0: No neovascularization, 1: Minimal neovascularization, 2: Mild neovascularization, 3: Maximal neovascularization.

All data were analyzed using the Statistical Program for Social Science software v.10.0 (SPSS Inc., Chicago, IL, USA) with Kruskal-Wallis and Mann-Whitney U-tests. P values of less than 0.05 were considered significant.

## Results

Ninety percent of new bone formation in the Adcon-L group was Grade 3 while 80% in the 5FU group was Grade 0 (Fig. 1) (Table 1). The majority of new bone formation in the control group was Grade 2 and 3. There was a statistically significant difference between the 5FU and control groups ( $p=0.0001$ ).

Fibroblast density was low in the Adcon-L and 5FU groups. According to the criteria of He and Revel,<sup>[14]</sup> both the Adcon-L and 5FU groups demonstrated 70% density for Grade 2 fibroblasts and 70% density for Grade 3 fibroblasts in the control group (Table 1). Fibroblast density was significantly reduced in the Adcon-L and 5FU groups compared to the control group ( $p=0.0001$ ).

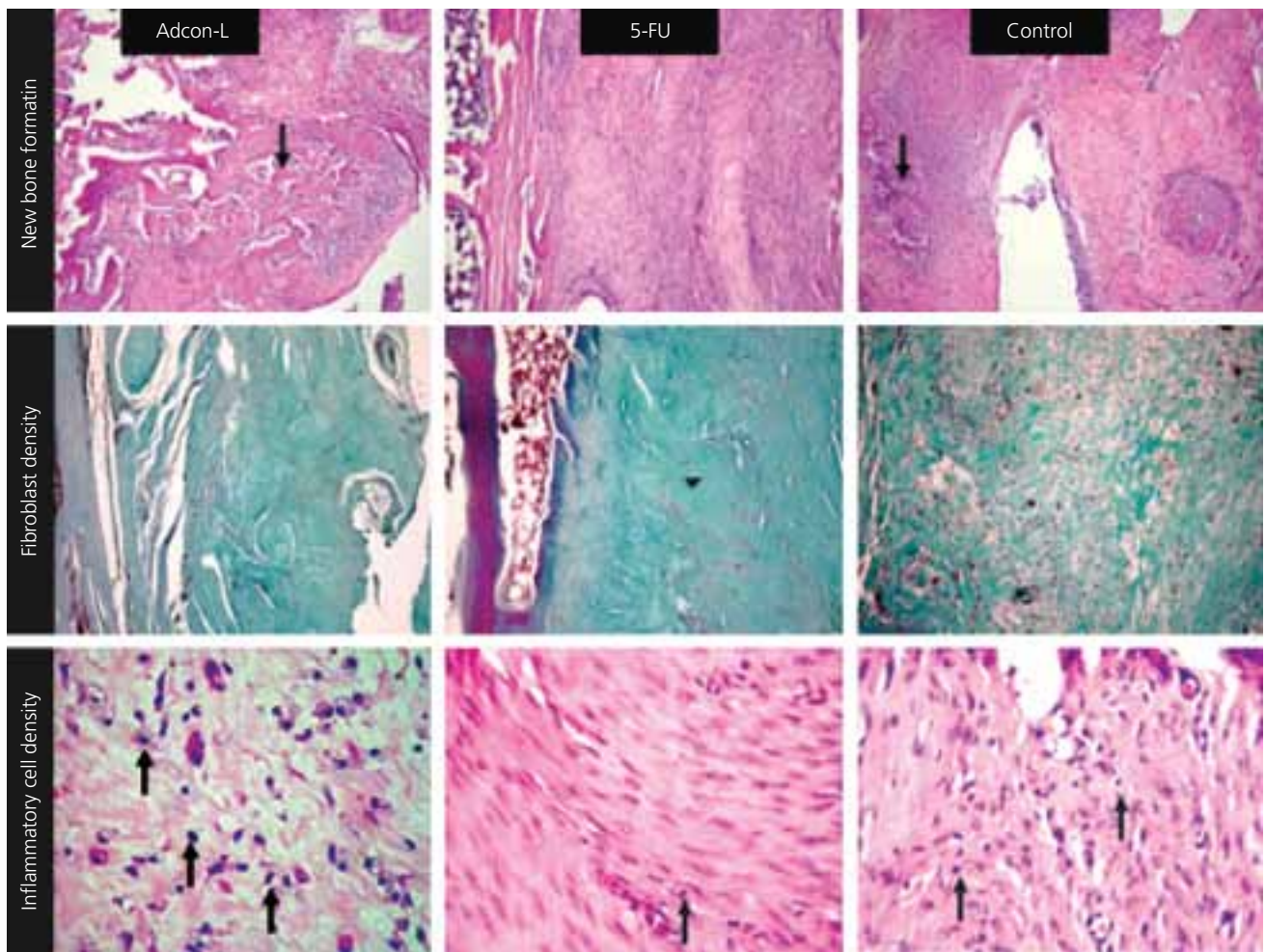
Inflammatory cell counts were elevated in the Adcon-L group and decreased in the 5FU group. Average inflammatory cell count under x400 magnification was 11.7 in the Adcon-L group while it was 1.8 for the 5FU group and 5.9 for the control group (Fig. 1) (Table 1). There was a significant difference between the 5FU and control

groups in terms of inflammatory cell density ( $p=0.0001$ ).

Assessment of the sections with regard to neovascularization based on Emery et al.'s<sup>[15]</sup> criteria revealed a prevalence of Grade 2 neovascularization in all the groups with no intergroup difference ( $p=0.1140$ ). None of the agents had a negative or positive effect over neovascularization. Adcon-L was not completely resorbed in half of the subjects in the Adcon-L group.

## Discussion

The issue of spontaneous, or unintended, fusion, in spinal surgery has been noted by many authors.<sup>[1-7]</sup> Osseous bridging and excessive fibrous reaction can affect the spine and hinder mobility in cases of spontaneous fusion.<sup>[16,17]</sup> Spontaneous fusion and fibrosis that hinders correction of the deformity and leads to crankshaft deformity have been reported in cases of Luque instrumentation without fusion.<sup>[6,18]</sup> Although the increased capacity for healing in immature spines is held responsible for spontaneous fusion, no significant change has been observed in the number of reports involving spontaneous fusion despite recent precautionary steps, such as small skin incision, minimal muscle denuding, effective hemostasis, wound site irrigation and use of the subfascial or subcutaneous method. Cahill et al. reported a spontaneous fusion rate of 89% in the spinal segments of 9 immature patients undergoing definitive fusion surgery.<sup>[7]</sup>



**Fig. 1.** New bone formation. Arrows indicate the foci of new bone formation. Bone formation of Grade 3 in Adcon-L and Grade 2 in control group are shown (HE, x10). Both agents reduce the fibroblast density significantly (MT, x10). Inflammatory cell density is significantly lower in the 5FU group. Opposite arrows show the inflammatory cells (HE, x40). [Color figure can be viewed in the online issue, which is available at [www.aott.org.tr](http://www.aott.org.tr)]

Only a small number of studies have investigated the inhibitory effect of pharmaceutical agents in spinal surgery. Zou et al.<sup>[11]</sup> reported that Adcon-L inhibited spontaneous fusion to a certain degree. In this experimental study, following bilateral decortication of the transverse processes, the authors performed intertransverse fusion by applying an autograft acquired from the iliac wing on one side, while using a mixture comprised of the same amount of autograft and Adcon-L on the other side. Since we believe that this model and other fusion models in different experimental studies do not simulate spontaneous fusion properly, we created a model in which no method that can trigger fusion or fibrosis other than aggressive denuding and spinous process wiring was used. Fibrin glue, which generally acts as a carrier to hold the graft substitutes together, has also been used in the literature for similar purposes and is thought

to prevent migration and distribution of graft materials and BMPs over areas where fusion is not desired.<sup>[9,10]</sup> However, fibrin glue enables fusion control rather than inhibits fusion and bears importance particularly with regard to decompressive surgery.

The two agents used in our study have different mechanisms of action. The antiproliferative agent 5FU is a fluorinated pyrimidine analog used as a topical agent for the prevention of fibrosis after trabeculectomy and glaucoma filtration surgery.<sup>[19,20]</sup> It has also been shown in experimental studies to reduce the fibrotic adhesions following tendon repairs.<sup>[21-23]</sup> The aim of the 5-minute long single-touch method is to avoid the side effects of 5FU while obtaining the benefit of its antiproliferative properties. This technique does not lead to cell death but alters the metabolism and behavior of cells by affecting cellular mRNAs of the cytoskeleton and inhibiting the normal chemical

pathways followed in DNA synthesis.<sup>[13,23,24]</sup> On the other hand, Adcon-L is comprised of polyglycan esters and a gelatin that can be absorbed within a phosphate-buffered solution. Its primary mechanism of action is as a mechanical barrier against the migrating fibroblasts.<sup>[25]</sup>

Histological examination suggested that both agents affect the healing process over the operation site. Both agents were found to reduce the fibrotic tissue. However, there was a significant difference between 5FU and Adcon-L with regard to bone formation. Although we cannot explain the reason behind this significant difference, the delay concerning the absorption of Adcon-L appears to have a different influence over the healing process. In our study, Adcon-L failed to be absorbed in half of the samples in the Adcon-L group. Zou et al.<sup>[11]</sup> obtained a similar result. However, the significant elevation in the number of inflammatory cells in our study may be associated with the delayed absorption of Adcon-L and the antigenic properties of Adcon-L particles. Another factor that may explain this difference is the above described action mechanism of the two agents.

Our study had some limitations, including the absence of manual and radiological assessments and complications in evaluation of movement between the two vertebrae due to the small size of the evaluated area.<sup>[26]</sup> In the present study, no graft substitute was employed. Therefore, no detectable fusion mass was determined in the posterior spine which made the observation of osseous bridging, both radiologically and manually, impossible.

In conclusion, 5FU was significantly superior to Adcon-L in the inhibition of fibroblasts, inflammatory cells and bone formation. These findings suggest that 5FU can successfully inhibit fusion, fibrosis, and unwanted healing tissue in spinal surgery. Although 5FU appears to be a promising agent in this regard, further studies outlining the appropriate dosage and technique concerning its use on the human spine are necessary.

**Conflicts of Interest:** No conflicts declared.

## References

- Mardjetko SM, Hammerberg KW, Lubicky JP, Fister JS. The Luque trolley revisited. Review of nine cases requiring revision. *Spine* 1992;17:582-9. [CrossRef](#)
- Blakemore LC, Scoles PV, Poe-Kochert C, Thompson GH. Submuscular Isola rod with or without limited apical fusion in the management of severe spinal deformities in young children: preliminary report. *Spine* 2001;26:2044-8. [CrossRef](#)
- Acaroglu E, Yazici M, Alanay A, Surat A. Three-dimensional evolution of scoliotic curve during instrumentation without fusion in young children. *J Pediatr Orthop* 2002;22:492-6. [CrossRef](#)
- Moe JH, Kharrat K, Winter RB, Cummine JL. Harrington instrumentation without fusion plus external orthotic support for the treatment of difficult curvature problems in young children. *Clin Orthop Relat Res* 1984;185:35-45.
- Eberle CF. Failure of fixation after segmental spinal instrumentation without arthrodesis in the management of paralytic scoliosis. *J Bone Joint Surg Am* 1988;70:696-703.
- Fisk JR, Peterson HA, Laughlin R, Lutz R. Spontaneous fusion in scoliosis after instrumentation without arthrodesis. *J Pediatr Orthop* 1995;15:182-6. [CrossRef](#)
- Cahill PJ, Marvil S, Cuddihy L, Schutt C, Idema J, Clements DH, et al. Autofusion in the immature spine treated with growing rods. *Spine* 2010;35:E1199-203. [CrossRef](#)
- Poynton AR, Lane JM. Safety profile for the clinical use of bone morphogenetic proteins in the spine. *Spine* 2002;27(16 Suppl 1):40-8. [CrossRef](#)
- Patel VV, Zhao L, Wong P, Kanim L, Bae HW, Pradhan BB, et al. Controlling bone morphogenetic protein diffusion and bone morphogenetic protein-stimulated bone growth using fibrin glue. *Spine* 2006;31:1201-6. [CrossRef](#)
- Patel VV, Zhao L, Wong P, Pradhan BB, Bae HW, Kanim L, et al. An in vitro and in vivo analysis of fibrin glue use to control bone morphogenetic protein diffusion and bone morphogenetic protein-stimulated bone growth. *Spine J* 2006;6:397-404. [CrossRef](#)
- Zou X, Li H, Egund N, Lind M, Bunger C. Inhibition of spinal fusion by use of a tissue ingrowth inhibitor. *Eur Spine J* 2004;13:157-63. [CrossRef](#)
- Abiraman S, Varma HK, Umashankar PR, John A. Fibrin glue as an osteoinductive protein in a mouse model. *Biomaterials* 2002;23:3023-31. [CrossRef](#)
- Khan U, Occleston NL, Khaw PT, McGrouther DA. Single exposures to 5-fluorouracil: a possible mode of targeted therapy to reduce contractile scarring in the injured tendon. *Plast Reconstr Surg* 1997;99:465-71. [CrossRef](#)
- He Y, Revel M, Loty B. A quantitative model of post-laminectomy scar formation. Effects of a nonsteroidal anti-inflammatory drug. *Spine* 1995;20:557-63; discussion 579-80. [CrossRef](#)
- Emery SE, Brazinski MS, Koka A, Bensusan JS, Stevenson S. The biological and biomechanical effects of irradiation on anterior spinal bone grafts in a canine model. *J Bone Joint Surg Am* 1994;76:540-8.
- Rinsky LA, Gamble JG, Bleck EE. Segmental instrumentation without fusion in children with progressive scoliosis. *J Pediatr Orthop* 1985;5:687-90. [CrossRef](#)
- Tello CA. Harrington instrumentation without arthrodesis and consecutive distraction program for young children with severe spinal deformities. Experience and technical details. *Orthop Clin North Am* 1994;25:333-51.

18. Morin MR. Pediatric Cotrel-Dubousset instrumentation system. In: Bridwell KH, DeWald RL, editors. *Spinal surgery*. Philadelphia, PA: JB Lippincott; 1991. p. 212-7.
19. Anand N, Sahni K, Menage MJ. Modification of trabeculectomy with single-dose intraoperative 5-Fluorouracil application. *Acta Ophthalmol Scand* 1998;76:83-9. [CrossRef](#)
20. Mora JS, Nguyen N, Iwach AG, Gaffney MM, Hetherington J Jr, Hoskins HD Jr, et al. Trabeculectomy with intraoperative sponge 5-fluorouracil. *Ophthalmology* 1996;103:963-70. [CrossRef](#)
21. Zhao C, Zobitz ME, Sun YL, Predmore KS, Amadio PC, An KN, et al. Surface treatment with 5-fluorouracil after flexor tendon repair in a canine in vivo model. *J Bone Joint Surg Am* 2009;91:2673-82. [CrossRef](#)
22. Moran SL, Ryan CK, Orlando GS, Pratt CE, Michalko KB. Effects of 5-fluorouracil on flexor tendon repair. *J Hand Surg Am* 2000;25:242-51. [CrossRef](#)
23. Khaw PT, Sherwood MB, MacKay SL, Rossi MJ, Schultz G. Five-minute treatments with fluorouracil, floxuridine, and mitomycin have long-term effects on human Tenon's capsule fibroblasts. *Arch Ophthalmol* 1992;110:1150-4.
24. Akali A, Khan U, Khaw PT, McGrouther AD. Decrease in adhesion formation by a single application of 5-fluorouracil after flexor tendon injury. *Plast Reconstr Surg* 1999;103:151-8. [CrossRef](#)
25. Geisler FH. Prevention of peridural fibrosis: current methodologies. *Neurol Res* 1999;21 Suppl 1:S9-22.
26. Zhu W, Rawlins BA, Boachie-Adjei O, Myers ER, Arimizu J, Choi E, et al. Combined bone morphogenetic protein-2 and -7 gene transfer enhances osteoblastic differentiation and spine fusion in a rodent model. *J Bone Miner Res* 2004;19:2021-32. [CrossRef](#)