



# An unusual complication following total hip arthroplasty: median circumflex femoral artery pseudoaneurysm

Serhat MUTLU<sup>1</sup>, Olcay GÜLER<sup>2</sup>, Adem UÇAR<sup>3</sup>, Mahir MAHIROĞULLARI<sup>2</sup>

<sup>1</sup>Department of Orthopedics and Traumatology, Kanuni Sultan Süleyman Training and Research Hospital, Istanbul, Turkey;

<sup>2</sup>Department of Orthopedics and Traumatology, Istanbul Medipol University Faculty of Medicine, Istanbul, Turkey;

<sup>3</sup>Department of Radiology, Istanbul University Istanbul Faculty of Medicine, Istanbul, Turkey

We report a case of a pseudoaneurysm of the medial circumflex femoral artery that presented 4 months following cementless left total hip arthroplasty (THA). A successful embolization was achieved using super-selective catheterization and coil embolization. Arterial complications associated with THA are remarkably rare. Endovascular techniques have been shown to be effective and are considered a valid alternative to conventional surgery.

**Key words:** Aneurysm; coil embolization; femoral artery; total hip replacement; vascular complication.

Surgery of the hip joint has become widespread. Since it is performed in the vicinity of major vessels and nerves, several intraoperative risks are important to consider. Such problems are associated with considerable morbidity, particularly if left undiagnosed or if treatment is delayed. Vascular injury is a rare complication following total hip arthroplasty (THA). Pseudoaneurysm occurs when there is a small laceration of the wall of a large artery with continuing leakage of blood into the surrounding tissues.<sup>[1]</sup>

We present a case of a pseudoaneurysm of the medial circumflex femoral artery that presented 4 months following cementless left THA performed via a lateral incision and anterior approach.

## Case report

We report a 75-year-old male patient with severe osteoarthritis and osteolytic degenerations of the left hip (Fig. 1a). Conservative treatment strategies did not show any improvement. Pain and immobilization increased significantly. The patient underwent THA with a cementless metal-on-polyethylene prosthesis (Fig. 1b). No intraoperative complications occurred. Two units of erythrocyte suspension were used after the operation. Vital signs, such as arterial blood pressure, pulse rate, central venous pressure, and urine volume, remained stable.

Four months after the hip operation, the patient was referred to the hospital with swelling and severe pain in the left great trochanteric region. Clinical examination,

**Correspondence:** Mahir Mahiroğulları, MD. İstanbul Medipol Üniversitesi, Atatürk Bulvarı, No: 27, Unkapanı, 34083 Fatih, İstanbul, Turkey

Tel: +90 212 – 531 75 55 e-mail: mahiroğullari@yahoo.com

**Submitted:** July 29, 2012 **Accepted:** January 07, 2013

©2014 Turkish Association of Orthopaedics and Traumatology

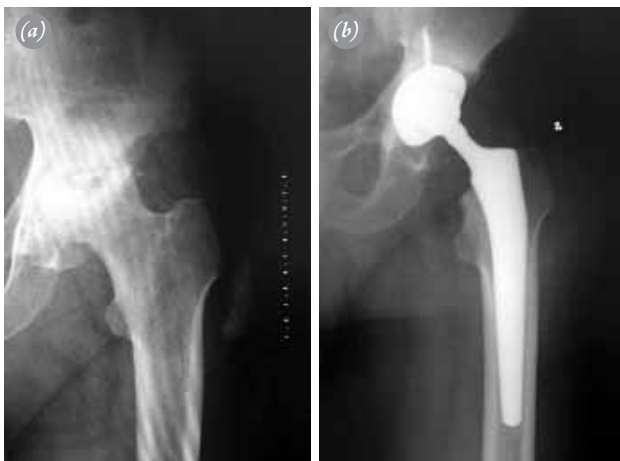Available online at

www.aott.org.tr

doi: 10.3944/AOTT.2014.3000

QR (Quick Response) Code

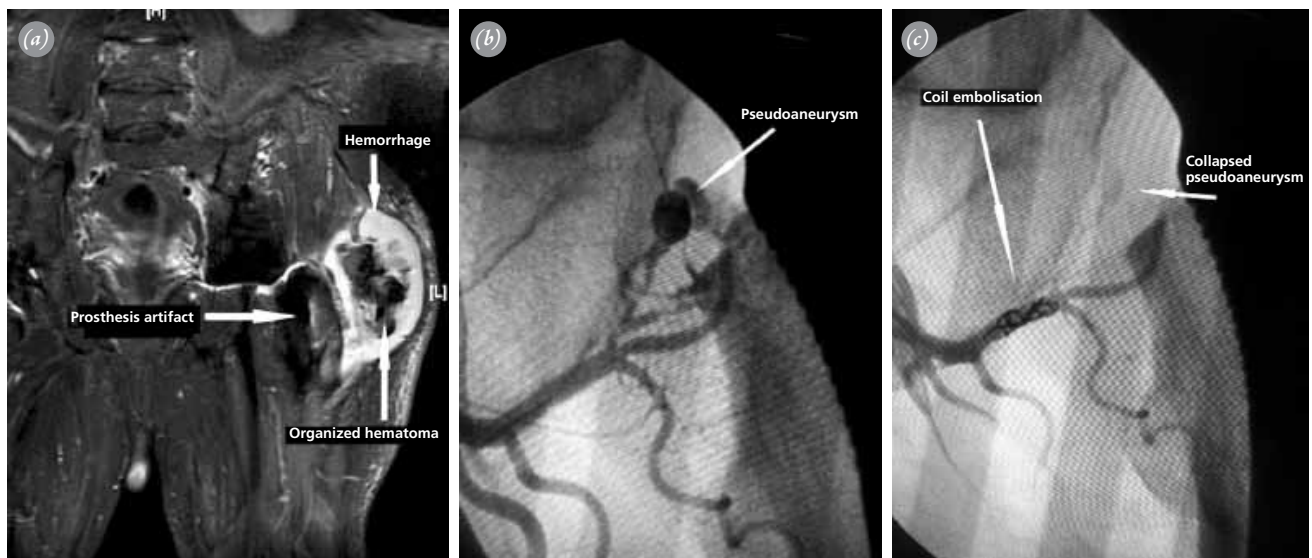




**Fig. 1.** (a) Preoperative and (b) postoperative radiographs of the patient.

ultrasound, radiography, MRI (Fig. 2a) and angiography (Fig. 2b) showed a pseudoaneurysm of the left femoral artery, spreading proximal to the left common iliac artery. Laboratory findings were normal. There were no signs of anemia or bleeding tendency.

During the angiography, successful embolization was subsequently achieved using superselective catheterization and coil embolization using one 3 mm x 3 mm and one 4 mm x 4 mm macro coils (Cordis macro coil with Terumo 5F Cobra 2 glide) placed proximal to the neck of the pseudoaneurysm (Fig. 2c). The patient was evaluated at 6-week intervals for 3 months and at the end of the 6th month. Clinically, we did not observe any complications.



**Fig. 2.** (a) Magnetic resonance image showing the organized hematoma at the center of the hemorrhage. (b) The angiogram showing a pseudoaneurysm of the left medial circumflex femoral artery following total hip replacement. (c) Post-coil embolization view of the medial circumflex femoral artery pseudoaneurysm. Note the collapsed pseudoaneurysm.

## Discussion

Although vascular injuries are a rare complication after THA,<sup>[2]</sup> their potential must be considered due to the proximity of the vascular structures to the hip joint.<sup>[2,3]</sup>

Nachbur et al.<sup>[2]</sup> described several causes and mechanisms of vascular injuries. Four mechanisms were distinguished; perforation of a major artery with a Hohmann retractor, overextension of atherosclerotic arteries with subsequent thrombus formation, laceration of a major artery during replacement of a total hip prosthesis, and thrombotic occlusion of a major artery due to extensive heat of polymerization.

Ratliff suggested that a patient may present weeks or months following THA with a painful pulsatile mass resulting from a pseudoaneurysm arising due to a small laceration of a large artery with continuing leakage of blood into the surrounding tissues.<sup>[4]</sup>

Regarding the reports of false aneurysm after THA, there appears to be an increased risk with revision procedures.<sup>[1,3,5]</sup> Malpositioning of retractors at the anterior aspect of the hip joint capsule can also cause vascular injuries, including pseudoaneurysm.<sup>[6]</sup>

In our case, the acetabular and femoral components were set in the ideal position. Our patient first developed symptoms of a false aneurysm 4 months after surgery. We believe that in late onset aneurysm, such as in the present case, the mechanisms described by Nachbur et al.<sup>[2]</sup> are unlikely (with the exception of thermal injury due to the use of cement).

Rossi et al. described intimal injury due to the use

of electrocautery in an experimental study.<sup>[7]</sup> We believe this might be the reason in our case as well.

Several treatment strategies for pseudoaneurysm have been proposed, including direct suture,<sup>[6,8]</sup> closure of the defect with a patch<sup>[9]</sup> and simple resection of the aneurysm.<sup>[10]</sup> In our patient, a minimally invasive technique was used successfully.

In conclusion, arterial complications associated with THA are remarkably rare. Endovascular techniques have been shown to be effective and are considered a valid alternative to conventional surgery.

**Conflicts of Interest:** No conflicts declared.

## References

1. Dorr LD, Conaty JP, Kohl R, Harvey JP Jr. False aneurysm of the femoral artery following total hip surgery. *J Bone Joint Surg Am* 1974;56:1059-62.
2. Nachbur B, Meyer RP, Verkkala K, Zürcher R. The mechanisms of severe arterial injury in surgery of the hip joint. *Clin Orthop Relat Res* 1979;141:122-33.
3. Giacchetto J, Gallagher JJ. False aneurysm of the common femoral artery secondary to migration of a threaded acetabular component. A case report and review of the literature. *Clin Orthop Relat Res* 1988;231:91-6.
4. Ratliff AH. Arterial injuries after total hip replacement. *J Bone Joint Surg Br* 1985;67:517-8.
5. Lacroix H, du Bois NA, van Biezen FC. Dislocation of a total hip prosthesis by a false aneurysm. *J Bone Joint Surg Br* 1992;74:159-60.
6. Mallory TH, Jaffe SL, Eberle RW. False aneurysm of the common femoral artery after total hip arthroplasty. A case report. *Clin Orthop Relat Res* 1997;338:105-8. [CrossRef](#)
7. Rossi FH, Izukawa NM, Silva DG, Chen J, Prakasan AK, Zamorano MM, et al. Effects of electrocautery to provoke endovascular thermal injury. *Acta Cir Bras* 2011;26:329-32.
8. Kroese A, Mollerud A. Traumatic aneurysm of the common femoral artery after hip endoprosthesis. *Acta Orthop Scand* 1975;46:119-22. [CrossRef](#)
9. Tkaczuk H. False aneurysm of the external iliac artery following hip endoprosthesis. *Acta Orthop Scand* 1976;47:317-9. [CrossRef](#)
10. Akizuki S, Terayama K, Kobayashi S. False aneurysm of the external iliac artery during total hip replacement. A case report. *Arch Orthop Trauma Surg* 1984;102:210-1.