



Surgical reconstruction in Wassel type IV thumb duplication

Murat KAYALAR¹, Yusuf GÜRBÜZ¹, Levent KÜÇÜK²,
Tahir Sadık SÜĞÜN¹, Yalçın ADEMOĞLU¹, Kemal ÖZAKSAR¹

¹Hand Microsurgery Orthopaedics Traumatology Hospital, Izmir, Turkey;

²Department of Orthopaedics and Traumatology, Ege University, Faculty of Medicine, Izmir, Turkey

Objective: The aim of this study was to review the results of patients with Wassel type IV thumb duplication, treated with a single reconstructive procedure.

Methods: The mean follow-up period was 76.9 months. Objective assessments were carried out using Horii modification of Tada scoring system and ALURRA scoring system. Thumb length, thumb girth, range of motion of metacarpophalangeal (MCP) and interphalangeal (IP) joints and angular deformities at MCP and IP joints were evaluated.

Results: The mean ALURRA score was 21 (range; 16–24) and Tada Score 5.25 (range; 2–7). The length of the operated thumb was approximately 95%, the girth 89% and nail width 80% of the non-operated side. The mean range of motion was 75.1% of the unaffected thumb in interphalangeal joint and 80.1% in metacarpophalangeal joint. Metacarpophalangeal joint malalignment had shown statistically significant negative correlation with the scores of Tada, ALURRA and VAS.

Conclusion: Surgical reconstruction may provide a functional and stable thumb in Wassel type IV thumb duplications. The satisfaction of patients is affected by angular deformity of thumbs and cosmetic outlook.

Key words: Thumb duplication; polydactyly; hand deformities, congenital; tenodesis; amputation.

Thumb duplication or radial polydactyly is the second most common congenital hand anomaly, after syndactyly.^[1] Wassel type IV duplication has the most common occurrence (about 50% of all thumb duplications) with duplication of the proximal and distal phalanges. The phalanges articulate with a bifid metacarpal head.^[2-4]

To preserve thumb function, duplication should undergo early surgical treatment in the first year of life.^[5-7] The purpose of the surgical treatment is to obtain a thumb similar to normal thumb anatomy with less growth im-

pairment. In thumb duplication interphalangeal (IP) and metacarpophalangeal joints (MCP) are supposed to be stable but have some limitations in range of motion.^[8]

Current reconstructive procedures are based on the ablation of radial supernumary thumb, reconstruction of the radial collateral ligament and reinsertion of abductor pollicis brevis (APB) muscle.^[6,7,9-12] However, in type IV duplications, the most important late period problems are instability, malalignment and zigzag deformity in IP and MCP joints.^[1,13-16]

Correspondence: Levent Küçük, MD. Ege Üniversitesi Tıp Fakültesi, Ortopedi ve Travmatoloji Anabilim Dalı, İzmir, Turkey.

Tel: +90 232 – 390 27 83 e-mail: kucuklevent@yahoo.com

Submitted: August 15, 2013 **Accepted:** October 14, 2013

©2014 Turkish Association of Orthopaedics and Traumatology

Available online at
www.aott.org.tr
doi: 10.3944/AOTT.2014.13.0042
QR (Quick Response) Code



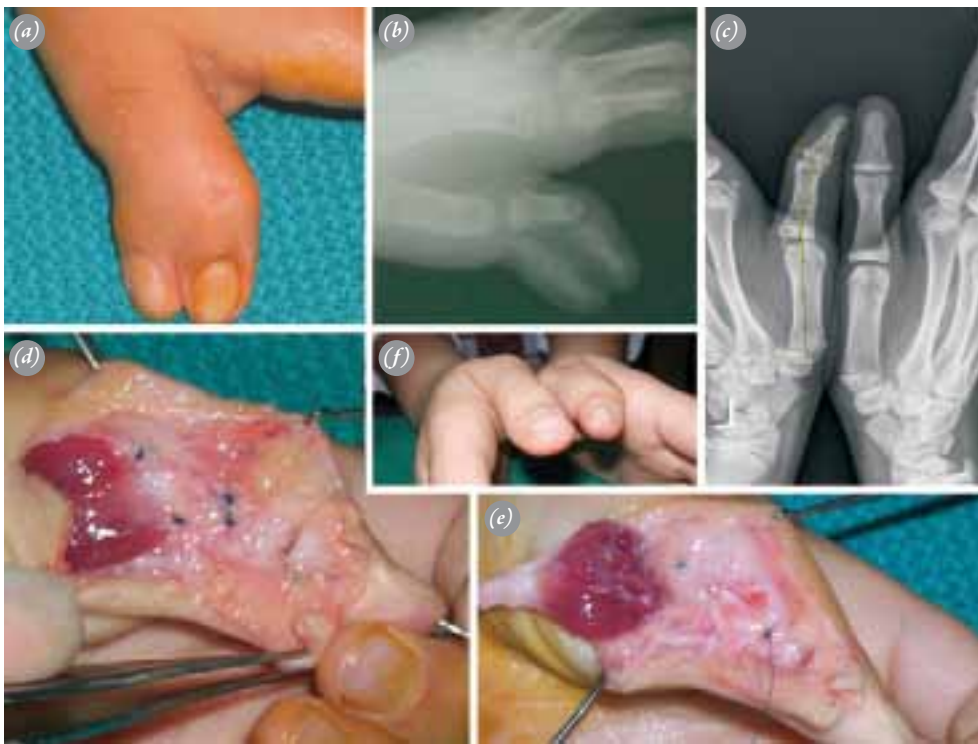

Fig. 1. (a) Clinical view of left hand thumb duplication. (b) Radiological view of left hand thumb duplication. (c) Radiological view of the affected thumb in the last control. There is more than 20 degree interphalangeal joint instability. (d, e) Operative view. After ablation of radial sided thumb, radial collateral ligament and abductor pollicis brevis reinsertion were performed. (f) Clinical view in the last control. [Color figure can be viewed in the online issue, which is available at www.aott.org.tr]

The aim of this study was to review the results of patients with Wassel type IV thumb duplication, treated with a single reconstructive procedure.

Patients and methods

A total of 35 patients underwent surgical treatment for thumb duplication between 1997 and 2009 and 21 of these patients were with Wassel type IV duplication.^[17] Of these 21 patients, 16 (11 male and 5 female; mean age: 16.8 months [range; 6–54]) were available for follow-up and were included in our study. There was no bilateral case. According to the subgroup classification of Horii et al. (1997), 3 patients were with A1, 2 patients were with A2, 5 patients were with B, 5 patients were with C and 1 patient was with type D duplication.

The surgical technique included excision of radial thumb, sculpturing of articular surface and extra facet excision, phalangeal or metacarpal osteotomy in necessary cases, capsular reefing, reinsertion of radial collateral ligament and thenar muscles and extensor pollicis longus (EPL) augmentation. The ulnar duplicate thumb was not excised in any case. The less functional radial supernumerary thumb was excised and the ulnar collateral ligament was preserved. During the excision of the thumb, radial collateral ligament was elevated from the metacarpal as an osteoperiosteal flap.^[18] APB tendon was marked with tag sutures to be reinserted into the ulnar side of the thumb later. Capsular reefing was performed in cases with capsular loosening (Figure 1).

Objective assessment were carried out using Horii

Table 1. TADA criteria of postoperative evaluation. (Results over or equal to 5 were categorized as good, 3 and 4 as fair, less than 3 as poor.)

| Score | 2 | 1 | 0 |
|------------------|------------|--------------------|-----------------------|
| Range of motion* | >70% | 50–70% | <50% |
| Instability | – | No instability | Instability |
| Deformity | <10° | 10°–20° | >20° |
| Cosmetic | Acceptable | Moderate deformity | Substantial deformity |

*Compared with the opposite side.

Table 2. ALURRA criteria. (A total score above 20 is categorized as good, between 13 and 20 as moderate, and less than 13 as poor.)

| Criteria | Score | | |
|-------------------------------------|--------|-------------|--------------------|
| | 2 | 1 | 0 |
| Alignment | | | |
| IP joint deviation(radial/ulnar) | <10° | 10°–20° | >20° |
| MP joint deviation (radial/ulnar) | <10° | 10°–20° | >20° |
| Ulnar instability | | | |
| IP joint | <5° | 5°–15° | >15° |
| MCPjoint | <20° | 20°–40° | >40° |
| Radial instability | | | |
| IP joint | <5° | 5°–15° | >15° |
| MCP joint | <20° | 20°–40° | >40° |
| Range of motion | | | |
| IP joint | >70° | 50°–70° | <50° |
| MCPjoint (% of opposite thumb) | >70° | 50°–70° | <50° |
| Aesthetical aspects | | | |
| Circumference (% of opposite thumb) | 75–100 | 50–75 | <50 |
| Length | 75–100 | 50–75 | <50 |
| Nail size | 75–100 | 50–75 | <50 |
| Nail deformities | None | Small ridge | Severe deformation |

modification of Tada scoring system and ALURRA scoring system^[19,20] (Table 1, 2). Both the normal side's and the operated side's thumb lengths, thumb girths, range of

motion of MCP and IP joints and angular deformities at MCP and IP joints were measured. Nail width and nail deformity were recorded. Joint instability was tested

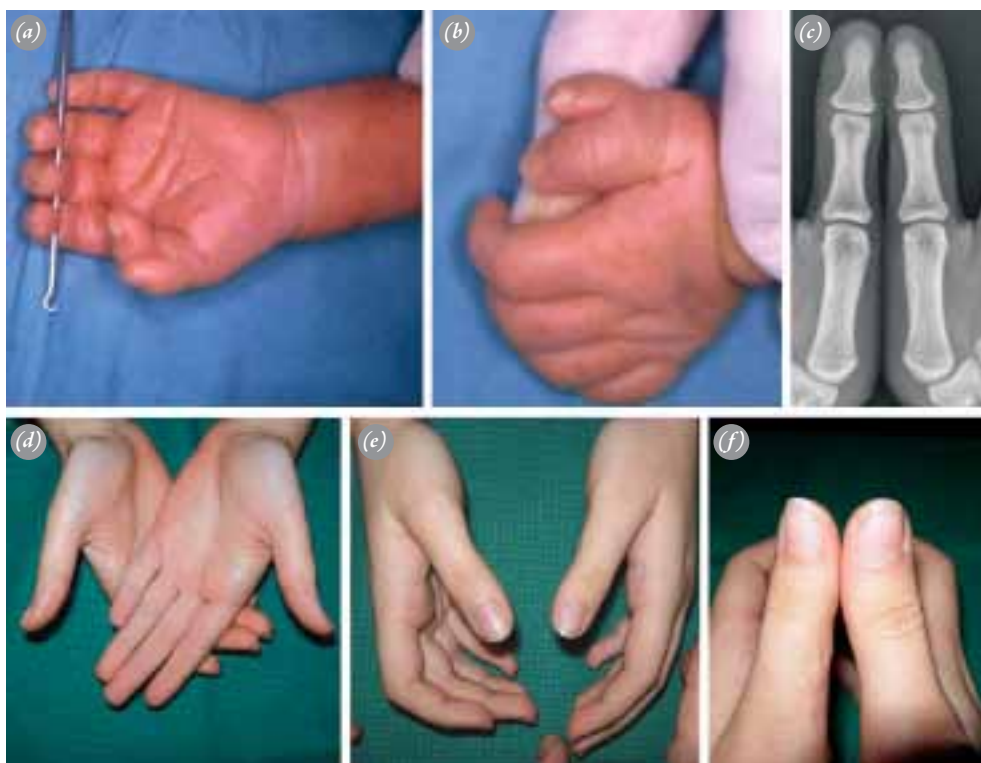


Fig. 2. (a, b) Preoperative view of left hand thumb duplication. (c) Radiological view in the last examination. (d-f) Final clinical view of the affected thumb in the last control after 144 months from the index procedure which includes radial collateral ligament and abductor pollicis brevis reinsertion. [Color figure can be viewed in the online issue, which is available at www.aott.org.tr]

Table 3. Demographic data and clinical results.

| No | Sub type | Age at surgery (months) | Procedures | Follow up (months) | IP ROM (of % control) | IP Stability (degree) | MP ROM (of % control) | MP stability (degree) | ALURRA Score | TADA Score | VAS |
|----|----------|-------------------------|----------------|--------------------|-----------------------|-----------------------|-----------------------|-----------------------|--------------|------------|-----|
| 1 | A2 | 15 | E, CL | 18 | 55 | <5 | 100 | <5 | 23 | 7 | 8 |
| 2 | A2 | 8 | E, CL, T | 34 | 77 | <5 | 100 | <5 | 24 | 7 | 9 |
| 3 | B | 54 | E, CL, T | 20 | 77 | <5 | 33 | <5 | 22 | 6 | 8 |
| 4 | C | 14 | E, CL | 36 | 50 | <5 | 50 | <5 | 20 | 6 | 7 |
| 5 | C | 6 | E, CL, T | 144 | 88 | <5 | 88 | <5 | 24 | 7 | 9 |
| 6 | B | 11 | E, CL, T | 36 | 100 | 30 radial | 66 | <5 | 19 | 4 | 7 |
| 7 | A1 | 6 | E, CL, T, PFO | 156 | 66 | 25 radial | 66 | 15 | 16 | 2 | 6 |
| 8 | C | 8 | E, CL, T, MCNO | 22 | 88 | <5 | 88 | <5 | 22 | 6 | 8 |
| 9 | D | 7 | E, CL, T | 12 | 100 | <5 | 100 | <5 | 23 | 7 | 9 |
| 10 | C | 12 | E, CL, T, MCNO | 28 | 77 | <10 ulnar | 88 | 35 | 21 | 3 | 8 |
| 11 | B | 43 | E, CL, T, MCNO | 45 | 100 | <5 | 100 | <5 | 24 | 7 | 7 |
| 12 | A1 | 11 | E, CL | 46 | 50 | 45 radial | 83 | <5 | 16 | 2 | 6 |
| 13 | C | 44 | E, CL, T, PFO | 155 | 66 | 25 radial | 83 | 45 | 18 | 4 | 7 |
| 14 | A2 | 8 | E, CL, T | 130 | 77 | <5 | 100 | <5 | 24 | 5 | 7 |
| 15 | B | 6 | E, CL, T, MCNO | 120 | 66 | <5 | 66 | <5 | 21 | 5 | 7 |
| 16 | B | 6 | E, CL | 228 | 66 | <5 | 72 | <5 | 23 | 6 | 7 |

E: Excision of extra thumb; CL: Capsulorhaphy and/or collateral ligament repair; T: Tendon transfer; PFO: Proximal phalanx corrective osteotomy; MCNO: Metacarpal neck corrective osteotomy.

manually. Moreover, the parents were asked to evaluate the aesthetic conditions of their patients subjectively using visual analog scale (VAS) (Figure 2).

The resultant subjective and objective data were analyzed using Pearson's correlation test. The p values less than 0.05 were considered significant.

Results

The mean follow-up period was 76.9 months (range; 12–228). At the time of evaluation, the mean age of the patients was 92.3 months (range; 30–234).

According to ALURRA system, the result was good in 11 patients and fair in 5. According to Tada system, the result was good in 11 patients, fair in 3 and poor in 2. The mean ALURRA score was 21 (range; 16–24) and Tada score 5.25 (range; 2–7) (Table 3).

In cosmetic overview the lowest VAS score rated by the parents was 6 for two patients. The mean VAS score for all patients was 7.5 (range; 6–9).

When compared with the contralateral thumb, the length of the operated thumb was found to be approximately 5% (range; 0–8) shorter, the girth 11% (range; 0–39) less and nail width 20% (range; 0–28) narrow. There was no abnormality in the nails except their sizes.

The mean range of motion of IP joint was %75.1 (range; 50–100) of the unaffected thumb. The range of motion of MCP joint was %80.1 (range; 33–100) of the

unaffected thumb.

Radiologically, there was an angular deformity of the IP joint of more than 200 in three patients and an angular deformity of 50 to 150 towards the ulnar side in 2 patients. When IP joint stability was evaluated, ulnar instability of 50 to 150 was measured in one patient and radial instability of more than 200 was measured in four patients.

There was an angular deformity of the MCP joint of 100 to 200 towards the radial side in two patients. There was a radial instability of 200 to 400 in one patient and a radial instability of more than 400 in another. There was no patient with ulnar instability of MCP joint.

There was a statistically negative correlation between MCP malalignment and Tada, ALURRA and VAS scores.

Discussion

Resection of radial side of duplicate thumb, reconstruction of ulnar retaining thumb and Bilhaut–Cloquet Procedure are the current methods of treatment in Wassel type IV duplications. There is no patient in our series that was treated with Bilhaut–Cloquet Procedure.

Reconstructive procedure in duplication cases was discussed in detail by Horii et al. (1997). They examined 175 patients and divided the patients with Wassel type IV thumb duplication into 4 subgroups according to the connection type between duplicate thumbs. Even if it

makes surgical algorithms easier to divide type IV duplications into subgroups, it is radiologically difficult to categorize skeletally immature patients. In preoperative planning, the involvement of the ulnar thumb and the presence of a delta phalanx should be carefully assessed.

During surgical treatment a stable but stiff thumb is generally preferred over an unstable but mobile one.^[3,8] Stability is important for grasping and pinching functions. While there was no ulnar instability at the MCP joint in our series, two patient had a radial instability. Also five patient had a radial instability at the IP joint.

It is generally believed that axial deviations less than 200 would cause aesthetic problems rather than functional impairment.^[21] It was noted by Goldfarb (2008) that the more MCP deviation increased, the more the VAS scores decreased ($r=-0.7$, $p<0.01$).^[12] In our study, the trend was that increasing of the IP and MCP joint deviations directly affected the Tada and ALURRA scores ($p<0.05$).

Ganley and Lubahn (1995) reported that 20 to 25% of the cases underwent a revision surgery in type IV duplications.^[13] As insertions of tendons in thumb duplication are usually eccentric and rudimentary, collateral reconstruction by itself might be insufficient to form a balanced thumb. Therefore, the reconstruction of a balanced excursion axis for the tendons is mandatory in type IV duplication treatment. In our series, reinsertion of APB tendons was performed in 12 patients for the concentric reduction of the joints. It may be necessary to perform phalangeal or metacarpal osteotomies for an optimal joint orientation. We performed a metacarpal neck osteotomy in four of our patients and osteotomy of proximal phalanx in two. We believe that APB reinsertion, collateral reconstruction and EPL augmentation harvested from the removed thumb are significant steps. In cases with extra-articular malalignment, osteotomy may provide a stable and congruent MCP joint.

One of the concerns in type IV duplications is on the growth and development of the thumb. In type IV duplications, both thumbs appear shorter and have narrower nail width when compared to the opposite normal thumb.^[13,22] It was reported that a well formed shorter thumb and 80% preserved nail width did not cause any problem aesthetically and functionally.^[5,18] It was determined in our study that compared to the opposite normal thumb, the nail width had decreased by 20% and the thumb length by 5%. Also, our patients had a narrowing of the thumb circumference by 11 %, when compared with the opposite side. We observed that these impairments did not alter patients' satisfaction level ($p>0.05$).

ALURRA scoring system developed by Brouwer et al. (2006) is a more detailed system when compared to Tada classification.^[20] We found a statistically significant correlation among the Tada scores, ALURRA scores and VAS scores ($r>0.9$; $p<0.01$). Though ALURRA system is more detailed than Tada system, coherent results are obtained from Tada system. ALURRA system may be more effective in the evaluation of the cosmetic results.

Relatively small number of patients and lack of a control group may be considered as the limitations of our study.

In conclusion, surgical reconstruction may provide a functional and stable thumb in Wassel type IV thumb duplications. The satisfaction of patients is affected by angular deformity of thumbs and cosmetic outlook.

Conflicts of Interest: No conflicts declared.

References

1. Townsend DJ, Lipp EB Jr, Chun K, Reinker K, Tuch B. Thumb duplication, 66 years' experience-a review of surgical complications. *J Hand Surg Am* 1994;19:973-6. [CrossRef](#)
2. Al-Qattan MM. The distribution of the types of thumb polydactyly in a Middle Eastern population: a study of 228 hands. *J Hand Surg Eur Vol* 2010;35:182-7. [CrossRef](#)
3. Andrew JG, Sykes PJ. Duplicate thumbs: a survey of results in twenty patients. *J Hand Surg Br* 1988;13:50-3.
4. Mih AD. Complications of duplicate thumb reconstruction. *Hand Clin* 1998;14:143-9.
5. Dobyns JH, Wood VE, Bayne LG. Congenital hand deformities. In: Green DP, editor. *Operative hand surgery*. 3rd ed. New York: Churchill Livingstone; 1993. p. 251-549.
6. Kozin SH. Reconstruction of Wassel type IV thumb duplication. *Tech Hand Up Extrem Surg* 2010;14:58-62.
7. Tada K, Yonenobu K, Tsuyuguchi Y, Kawai H, Egawa T. Duplication of the thumb. A retrospective review of two hundred and thirty-seven cases. *J Bone Joint Surg Am* 1983;65:584-98.
8. Tonkin MA, Bulstrode NW. The Bilhaut-Cloquet procedure for Wassel types III, IV and VII thumb duplication. *J Hand Surg Eur Vol* 2007;32:684-93. [CrossRef](#)
9. Benatar N. Thumb duplication - simple surgery for a common problem? *Handchir Mikrochir Plast Chir* 2004;36:137-40. [CrossRef](#)
10. Cooney WP, Wolf J, Holtkamp K, Dobyns JH. Congenital duplication of the thumb. *Handchir Mikrochir Plast Chir* 2004;36:126-36. [CrossRef](#)
11. Horii E, Nakamura R, Sakuma M, Miura T. Duplicated thumb bifurcation at the metacarpophalangeal joint level: factors affecting surgical outcome. *J Hand Surg Am* 1997;22:671-9. [CrossRef](#)
12. Goldfarb CA, Patterson JM, Maender A, Manske PR.

- Thumb size and appearance following reconstruction of radial polydactyly. *J Hand Surg Am* 2008;33:1348-53. [CrossRef](#)
13. Ganley TJ, Lubahn JD. Radial polydactyly: an outcome study. *Ann Plast Surg* 1995;35:86-9. [CrossRef](#)
 14. Iwasawa M, Noguchi M, Mishima Y, Fujita K. Long-term results of nail fusion plasty of the duplicated thumb. *J Plast Reconstr Aesthet Surg* 2008;61:1085-9. [CrossRef](#)
 15. Kawabata H, Tada K, Masada K, Kawai H, Ono K. Revision of residual deformities after operations for duplication of the thumb. *J Bone Joint Surg Am* 1990;72:988-98.
 16. Larsen M, Nicolai JP. Long-term follow-up of surgical treatment for thumb duplication. *J Hand Surg Br* 2005;30:276-81. [CrossRef](#)
 17. Wassel HD. The results of surgery for polydactyly of the thumb. A review. *Clin Orthop Relat Res* 1969;64:175-93.
 18. Manske PR. Treatment of duplicated thumb using a ligamentous/periosteal flap. *J Hand Surg Am* 1989;14:728-33.
 19. Lim YB, Seul JH, Nam HJ, Woo SH. Extended indications of Bilhaut-Cloquet procedure for type 3 and 4 of duplicated thumb. *J Korean Soc Plast Reconstr Surg* 2011;38:821-8.
 20. Brouwer N, Van der Biezen JJ. After thumb duplication: a proposal for evaluation of the result. The ALURRA system. *Eur J Plast Surg* 2006;29:1-4. [CrossRef](#)
 21. Mailet M, Fron D, Martinot-Duquennoy V, Herbaux B. Results after surgical treatment of thumb duplication: a retrospective review of 33 thumbs. *J Child Orthop* 2007;1:135-41. [CrossRef](#)
 22. Cohen MS. Thumb duplication. *Hand Clin* 1998;14:17-27.