



Removal of a bent inflatable femoral nail: a case report

Eğilmiş şişirilebilir femur çivisinin çıkarılması: Olgu sunumu

Doğan BEK, Bahtiyar DEMIRALP, Servet TUNAY, Ali SEHIRLIOGLU, Ali Sabri ATESALP

Gülhane Military Medical Academy, Department of Orthopaedics and Traumatology

Intramedüller çivileme femur cisim kırıklarının tedavisinde altın standarttır. Nadir bir komplikasyon olan çivinin ikincil bir travma ile eğilmesi, tam olarak iyileşmeyen ve çok parçalı kırıklarda görülür. Yirmi üç yaşındaki erkek hasta, sağ femur cisim kırığı nedeniyle şişirilebilir intramedüller çivi ile tedavi edildikten iki ay sonra düşme sonucu yeniden kırık oluşması ve çivide 32 derecelik eğilme ile başvurdu. Çivi yerindeyken dışardan kuvvet uygulanarak 10 dereceye kadar düzeltilti. Kırık hattı açılarak, metal drili yardımıyla çivinin lateral duvarına delikler açıldı ve dört metal çubuğundan en lateralde olanı kesilerek, çivi aynı manevra ile tamamen düzeltilerek çıkarıldı. Yeni bir intramedüller şişirilebilir çivi ile dört ay sonra kaynama elde edildi. Çivinin çıkarılması sırasında çiviye kısmen veya tamamen kesmek için gerekebilecek malzemelerin hazır bulundurulması uygun olacaktır.

Anahtar sözcükler: Kemik çivisi; cihaz çıkarımı/yöntem; femur kırığı/cerrahi; kırık fiksasyonu, intramedüller.

Intramedullary nailing is the gold standard for the treatment of diaphyseal femoral fractures. Bending of the nail secondary to trauma is a rare complication encountered in unhealed and comminuted fractures. A 23-year-old men was admitted with refracture of the right femoral shaft and a 32-degree bending of an inflatable intramedullary nail due to a fall, two months after the initial surgical treatment. The nail was first straightened by exerting an external force, which decreased the angulation to 10 degrees. Then, the fracture site was opened, the lateral wall of the nail was drilled, and one of the four metal bars of the nail was cut. This allowed complete straightening of the nail by the same maneuver and its removal. A new inflatable intramedullary nail was placed and union was achieved after four months. Tools that may be necessary to cut the nail partially or totally should be made available for removal of bent nails.

Key words: Bone nails; device removal/methods; femoral fractures/surgery; fracture fixation, intramedullary.

Intramedullary nailing is the modern and gold standard treatment of adult comminuted diaphyseal fractures of femur. Union rate has been reported up to 100 % in the large series.^[1] Recent years, new inflatable intramedullary nails were designed for distal locking problems and in order to lessen x-ray exposure. However, there is no prospective study in large series of cases treated with these resembling intramedullary nails. In published studies, case numbers are too few and most of them consist of stable fractures^[2,3]

Bending of the nail due to a secondary trauma at the level of fracture site is a rare complication for

unhealed fractures.^[4] In this report, case who had a bent inflatable intramedullary nail as a result of new trauma after 2 months from the initial surgery was presented.

Case report

23 years old male, who had a right femur diaphyseal fracture after motorcycle accident and treated with an inflatable intramedullary nail (Fixion Intramedullary Nailing Systems, Disc-O-Tech, Herzeliya, Israel) in an other center was admitted to our clinic with refracture and 32 degrees bending (varus) deformity

of the nail after falling from stairs after two months from the initial surgery (Figure 1a). He had a closed type fracture pattern and had no neurovascular injury. Removal of the nail was planned after in situ correction described as Patterson and Ramser.^[5] Metal drill and saw were prepared to cut the nail in case of necessity. After the patient was positioned in supine on the operation table, a copious cotton pad was placed just proximal to the apex of the fracture. While an assistant standing at the opposite site of the table was stabilizing the pelvis, surgeon at the fracture site performed a maneuver to correct the deformity. Bending of the nail was decreased to 10 degrees. On the other hand, the incomplete fracture which was fixed with a cerclage in the initial surgery was separated with this maneuver. As a result of displacement of wire into the fracture during this second trauma, fracture site was opened. Holes were created on the lateral site of the nail by using a metal drill and one of the four columns of the inflatable nail was cut with metal saw. We both achieved to decrease the pressure which was obtained by liquid in the nail and strenght of the nail and than it was corrected with same maneuver. During this procedure, soft tissues were protected from metal particles by draping and the surgical field was

rinsed for removing of the particles and neutralizing of heat that was arisen from cutting and perforating procedures. Afterwards, the nail was removed from the entry site on the trochanteric region by using original removing apparatus. Fractured proximal site was fixed with cerclage and same size, new inflatable intramedullary nail was inserted (Figure 1b).

No complication was occurred in the postoperative period. Union was achieved after four months. The ranges of motion in hip and knee were normal and there were no limb length discrepancy and extremity atrophy on the second-year-visit (Figure 1c).

Discussion

Broken of the intramedullary nails mostly occurs at nonunion, comminuted or unstable fractures, fixation of osteotomies and pathological fractures because of metal fatigue and/or thin nails. While removal of broken implant is generally easy,^[6,7] bending of the nails commonly occurred because of secondary traumas, so removal of these implants is a challenge. The presented case had an intramedullary nail that had bent according to a new trauma. When compared with locking nails and inflatable nails, it is reported that, inflatable nails has not adequate stability in unstable

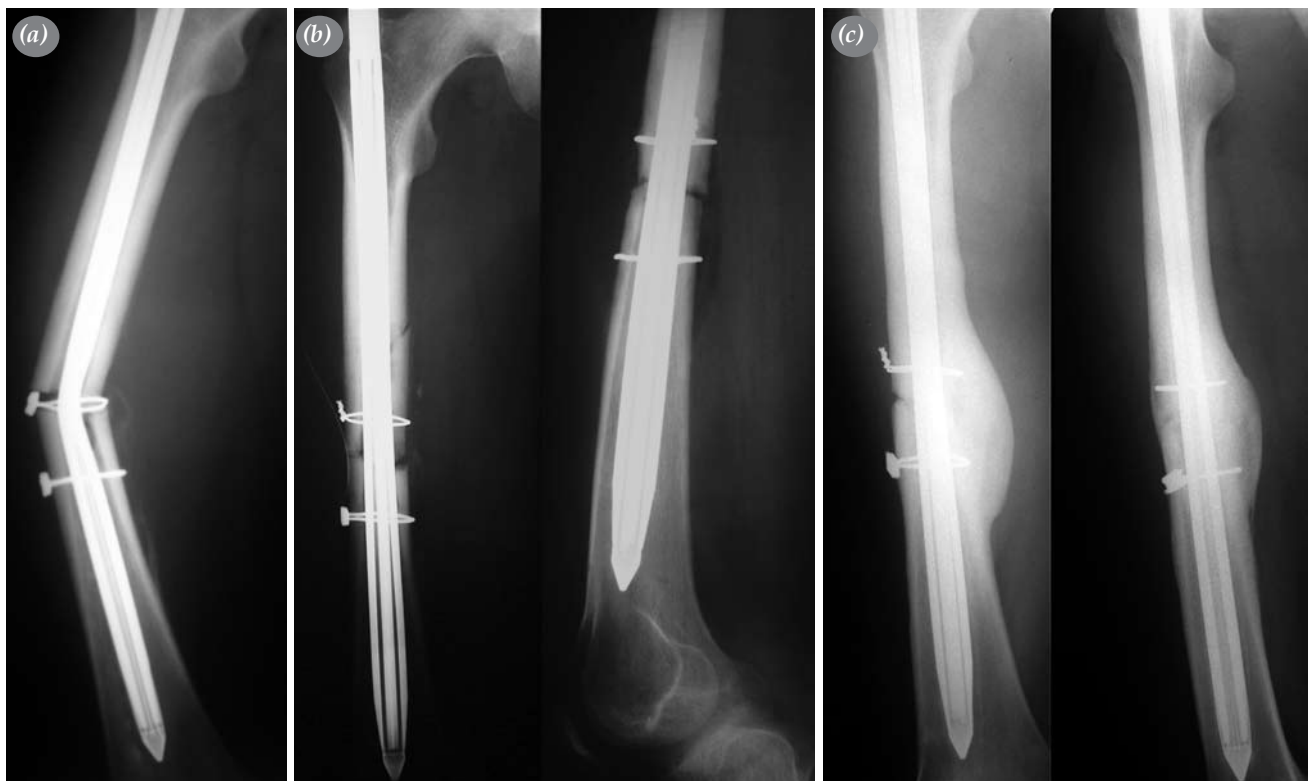


Figure 1. (a) 32 degrees of bending can be seen preoperatively. (b) X-rays of early postoperative period and (c) 2-years-follow-up

fractures, and strength in transverse fractures for torsional forces.^[2,8] Therefore, we thought that instead of exposing the fracture site and damaging the circulation by two cables and fixing fracture with an inflatable nail at the first surgery, it might be more adequate to fix the fracture with a locking nail with close method biologically.

There are several methods reported for removal of bent intramedullary nails.^[5,6,9-11] Some of them are correcting the nail and then removing without exposing the fracture site^[5], by weakening the nail at existing site with exposing the fracture site^[9,12], or by percutaneous method^[10], with metal drills or diamond cutters^[11] and then correcting and removing or cutting the nail totally where it bent and then removing.^[6,11,13]

The bent nail should be removed without damaging soft or bony tissue and circulation of fracture site. Because of the inflatable nail's proximal part is thicker, we have to remove the nail from the trochanteric site so first the nail should be corrected by external force if it fails, fracture site should be exposed and weakened the lateral column of the nail and then corrected the nail and removed the nail proximally. The risk of fracture during external correction, necessity of exposing the fracture site because of incomplete correction and the particles and heat produced by drill are the possible disadvantages. All necessary tools must be ready for cutting nail totally in case of necessity.

The negative properties of operation technique and nail increase the complication rate. For successful treatment of adult femur diaphyseal fracture, modern locking intramedullary nails which provide adequate stability and if possible closed reduction should be preferred.

References

1. Pintore E, Maffulli N, Petricciuolo F. Interlocking nailing for fractures of the femur and tibia. *Injury* 1992;23:381-6.
2. Bekmezci T, Baca E, Kaynak H, Kocabas R, Tonbul M, Yalaman O. Early results of treatment with expandable intramedullary nails in femur shaft fractures. [Article in Turkish] *Acta Orthop Traumatol Turc* 2006;40:1-5.
3. Lepore L, Lepore S, Maffulli N. Intramedullary nailing of the femur with an inflatable self-locking nail: comparison with locked nailing. *J Orthop Sci* 2003;8:796-801.
4. Yip KM, Leung KS. Treatment of deformed tibial intramedullary nail: report of two cases. *J Orthop Trauma* 1996;10:580-3.
5. Patterson RH, Ramser JR Jr. Technique for treatment of a bent Russell-Taylor femoral nail. *J Orthop Trauma* 1991;5:506-8.
6. Kockesen TC, Tezer M, Tekkesin M, Kuzgun U. Traumatic femoral diaphyseal fracture and a bent intramedullary nail in a case with a completely healed femoral diaphyseal fracture. [Article in Turkish] *Acta Orthop Traumatol Turc* 2002;36:177-80.
7. Kelsch G, Kelsch R, Ulrich C. Unreamed tibia nail (UTN) bending: case report and problem solution. *Arch Orthop Trauma Surg* 2003;123:558-62.
8. Maher SA, Meyers K, Borens O, Suk M, Grose A, Wright TM, et al. Biomechanical evaluation of an expandable nail for the fixation of midshaft fractures. *J Trauma* 2007;63:103-7.
9. Ohtsuka H, Yokoyama K, Tonegawa M, Higashi K, Itoman M. Technique for removing a bent intramedullary femoral nail: a case report. *J Orthop Trauma* 2001;15:299-301.
10. Apivatthakakul T, Chiewchantanakit S. Percutaneous removal of a bent intramedullary nail. *Injury* 2001;32:725-6.
11. Burzynski N, Scheid DK. A modified technique for removing a bent intramedullary nail minimizing bone and soft tissue dissection. *J Orthop Trauma* 1994;8:181-2.
12. al Maleh AA, Nielsen KS. How to remove a bent intramedullary nail. A technical note. *Acta Orthop Scand* 1998; 69:638-9.
13. Nicholson P, Rice J, Curtin J. Management of a refracture of the femoral shaft with a bent intramedullary nail in situ. *Injury* 1998;29:393-4.