



Functional outcomes of minimal invasive percutaneous plate osteosynthesis (MIPPO) in humerus shaft fractures: a clinical study

Gazi HURI¹, Ömer Sunar BIÇER², Hakan ÖZTÜRK³, Mehmet Ali DEVECİ², Ismet TAN²

¹Department of Orthopedics and Traumatology, Faculty of Medicine, Hacettepe University, Ankara, Turkey;

²Department of Orthopedics and Traumatology, Faculty of Medicine, Çukurova University, Adana, Turkey;

³Department of Anatomy, Faculty of Medicine, Mersin University, Mersin, Turkey

Objective: We aimed to evaluate the objective and subjective outcomes of humerus shaft fractures treated with minimal invasive percutaneous plate osteosynthesis and emphasize points which may enhance clinical outcomes and simplify the procedure.

Methods: The retrospective study included 14 patients (mean age: 41.7 years; range: 19 to 66 years) with humerus mid-shaft fractures treated with the MIPPO technique between 2009 and 2011. 4.5-mm locking plates were applied via an anterior approach and advanced antegradely (proximal to distal) to protect the integrity of the deltoid insertion. Fracture healing was evaluated using plain radiographs. Objective outcomes were assessed in terms of range of motion and subjective outcomes using the American Shoulder and Elbow Society (ASES), University of California, Los Angeles (UCLA), Mayo Elbow Performance Index (MEPI) and The Disability of The Arm, Shoulder and Hand (DASH) scores.

Results: Satisfactory outcomes with successful union were obtained within a mean of 17.8 (range: 13 to 30) months. While the average active forward flexion of shoulder was $163.9^\circ \pm 5.6^\circ$, the mean abduction was $87.8^\circ \pm 3.77^\circ$. Mean elbow flexion and extension loss was $134.6^\circ \pm 41.16^\circ$ and $3.9^\circ \pm 6.25^\circ$, respectively. Mean ASES and UCLA scores were 90.2 ± 4.76 and 31.8 ± 1.56 and mean MEPI and DASH score were 93.6 ± 4.12 and 4.6 ± 2.19 , respectively.

Conclusion: Minimal invasive percutaneous plate osteosynthesis appears to be a successful technique for the treatment of humerus shaft fractures. The procedure may be simplified and outcomes improved by engaging the plate with the anterior surface of the humerus during advancement, antegrade advancement of the plate to protect deltoid insertion and using of a minimum of 6 cortices for each side of the fracture to provide stable fixation.

Key words: Fracture; humerus shaft; MIPPO.

Fractures of the humerus shaft account for approximately 3% of all fractures and represent 20% of all humeral fractures.^[1] Primary causes of humerus shaft

fractures include traffic accidents, falls or violent injuries.^[2] Although conservative treatment is considered the gold standard,^[3-5] controversy still exists about the

Correspondence: Gazi Huri, MD, Asst. Prof. Hacettepe Üniversitesi Tıp Fakültesi, Ortopedi ve Travmatoloji Anabilim Dalı, Sıhhiye, 06100 Ankara, Turkey

Tel: +90 312 – 305 12 09 e-mail: ghuri1@jhmi.edu

Submitted: August 11, 2013 **Accepted:** April 05, 2014

©2014 Turkish Association of Orthopaedics and Traumatology

Available online at
www.aott.org.tr
doi: 10.3944/AOTT.2014.13.0009
QR (Quick Response) Code



ideal method of surgical fixation. Biologic fixation and minimally invasive surgery have become highly accepted alternatives in addition to conventional plating and intramedullary and external fixation.^[6]

Minimal invasive percutaneous plate osteosynthesis (MIPPO), primarily described for comminuted fractures of the tibia and femur, has also gained popularity in the treatment of humerus shaft fractures.^[7-11] MIPPO has the advantages of less soft tissue dissection, lower nonunion rates and low risk of iatrogenic radial nerve palsy, unlike open surgical procedures.^[12] It allows earlier functional treatment and higher postoperative range of motion in adjacent joints.^[13,14] Livani and Belangero^[15] and Apivarthakakul et al.^[12] investigated the feasibility of MIPPO via the anterior humeral approach in a cadaveric study and reported satisfactory results of 5 humeral shaft fractures treated by MIPPO in 4 patients. There is increasing evidence that MIPPO is superior to other fixation techniques. However, despite the aforementioned advantages, the technique also involves serious difficulties during application due to the proximity of neurovascular structures and anatomic obstacles.

The aim of the study was to report the objective and subjective outcomes of humeral shaft fractures treated with MIPPO via an anterior approach and emphasize the points that may enhance clinical results and simplify the procedure.

Materials and methods

Institutional review board approval was obtained before the retrospective study was initiated. The study included

14 humerus mid-shaft fractures of 13 patients (8 males and 5 females; mean age: 41.7 years; range: 19 to 66 years) surgically treated using the MIPPO technique between February 2009 and August 2011. Open fractures, skeletally immature patients, pathological fractures and revision cases were excluded from the study. Multi-trauma patients (7), failures after conservative treatment (5) and post-reduction radial nerve palsy (1) were included. Pre-injury shoulder and elbow range of motion were normal in all patients. Two patients had preoperative radial nerve palsy related to closed reduction and injury. Mechanisms of injury and classification of the fracture according to Orthopaedic Trauma Association (OTA) as well as other preoperative details are given in Table 1.

All patients underwent the same surgical procedure in the supine position using a hand table with the upper arm in the neutral position and forearm in full supination. Image intensifier control was used to check visualization of the shoulder as well as the entire humerus. After obtaining the adequate alignment and length of the humerus (<20° anterior angulation, <30° varus/valgus angulation, <3 cm shortening) by manual traction, two small incisions were made 5 to 7 cm proximal and distal to the fracture site in the standard line of anterolateral humeral approach (Fig. 1a). Delto-bicipital interval was used to expose the proximal shaft of the humerus and identify the anterior part of the deltoid insertion. For the distal humeral approach, biceps-brachialis cleavage was improved and a blunt retractor was inserted through the brachialis muscle belly to protect the radial nerve. The radial nerve was not explored with the exception of one patient with post-reduction radial nerve palsy. A periost-

Table 1. Preoperative details of the patients.

Patient [#]	Sex	Age (Years)	Side	Cause	AO/OTA classification	Concomitant injury
1	Female	64	Right	MVA	12 C1.1	None
2	Male	58	Right	MVA	12 A3.2	Floating elbow (R)
3	Female	39	Right Left	MVA	12 A3.2 (R) 12 B2.2 (L)	Clavicle fracture (R), metacarpal fractures (R), femur fracture (R), tibia fracture (L)
4	Male	55	Right	MVA	12A1.2	Post-reduction radial nerve palsy (R)
5	Male	19	Right	MVA	12B2.3	Forearm fracture (L), acetabulum fracture
6	Male	34	Right	MVA	12B2.2	Pelvis fracture, phalanx fracture (R Hand)
7	Male	19	Right	Fall	12 A3.2	Head injury, floating elbow radial nerve palsy (R)
8	Male	21	Right	MVA	12A3.2	Forearm compartment syndrome (R)
9	Female	35	Left	Fall	12B3.3	None
10	Male	42	Right	MVA	12A3.2	None
11	Female	36	Right	Fall	12 B2.2	None
12	Female	66	Right	MVA	12A3.2	Distal radius fracture (L)
13	Male	55	Left	MVA	12 C1.1	None

L: Left; MVA: Motor vehicle accident; R: Right.

teal elevator was inserted distally to proximally to create an anterior extraperiosteal tunnel between the brachialis muscle and humerus. Finally, a straight 4.5-mm locking compression plate (Synthes® 4.5 mm Narrow LCP Plate; Synthes Holding AG, Solothurn, Switzerland) was advanced antegradely through the submuscular tunnel in order to protect the anterior insertion of the deltoid muscle, which may cause functional weakness and avulsions (Fig. 1b).^[16] No external fixation was used for preliminary reduction, as described in previous studies.^[17,18] A threaded drill guide was used as a handle to help position the plate (Fig. 1c). A minimum of three screws penetrating six cortices were inserted in each of the main fracture fragment. All screws were inserted using a sleeve protection assembly and a drill guide to protect the neurovascular structures. In order not to penetrate the radial nerve in the groove posteriorly, single cortex screws were used in the mid-shaft of the humerus.

Patients were discharged with a sling 48 to 72 hours after surgery. Passive elbow and shoulder mobilization was permitted as tolerated. The sling and stitches were removed 10 to 14 days postoperatively. Patients were followed-up at four-week intervals for the first three months. Active motion with light resistance was started after 4 weeks, as early callus was detected as an evidence of bony union. Clinical and radiologic evaluation

was performed and range of motion of the shoulders and elbows were recorded to determine the objective outcomes. The American Shoulder and Elbow Society (ASES), University of California, Los Angeles (UCLA), Mayo Elbow Performance Index (MEPI) and The Disability of the Arm, Shoulder and Hand (DASH) scores were obtained from all patients at the time of their last clinic visit.

Results

Average time from injury to surgery was 6.4 (range: 1 to 14) days. All patients were followed up for a mean of 17.8 (range: 13 to 30) months. The mean healing time of the fractures was 13.8 (range: 10 to 20) weeks. Average active forward flexion of the shoulder was $163.9^\circ \pm 5.6^\circ$ and mean abduction was $87.8^\circ \pm 3.77^\circ$. Mean elbow flexion and extension loss was $134.6^\circ \pm 41.16^\circ$ and $3.9^\circ \pm 6.25^\circ$, respectively. Mean ASES score was 90.2 ± 4.76 . Mean UCLA score was 31.8 ± 1.56 (11 good and 3 excellent), MEPI 93.6 ± 4.12 (1 good and 13 excellent) and DASH score 4.6 ± 2.19 (Table 2).

In all cases, acceptable alignments were maintained by reducing the main fragments. All fractures had successful union without deep infection or wound complication (Fig. 2). Two patients had superficial wound infections which were controlled with antibiotic therapy. One

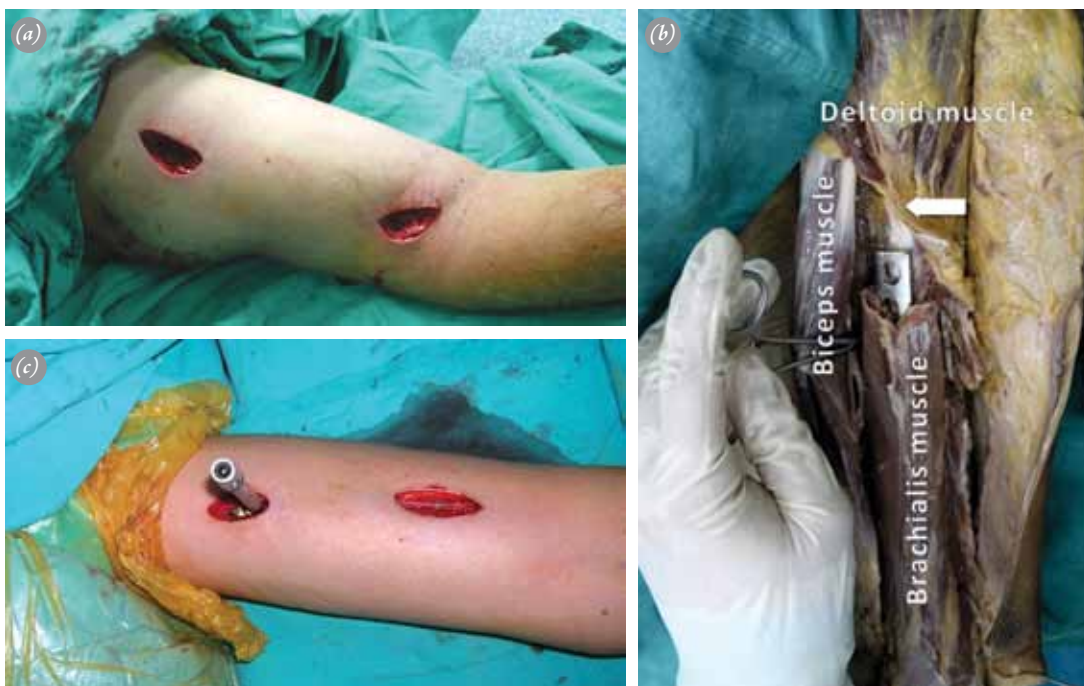

Fig. 1. (a) Proximal and distal incisions for MIPPO. (b) The brachialis muscle covering distal half of the anterior humeral surface, through which the plate is advanced and the detached anterior deltoid insertion (white arrow), to facilitate both plate advancement and positioning. (Cadaver dissection). (c) The threaded drill guide is engaged to the locking plate to help positioning. [Color figure can be viewed in the online issue, which is available at www.aott.org.tr]

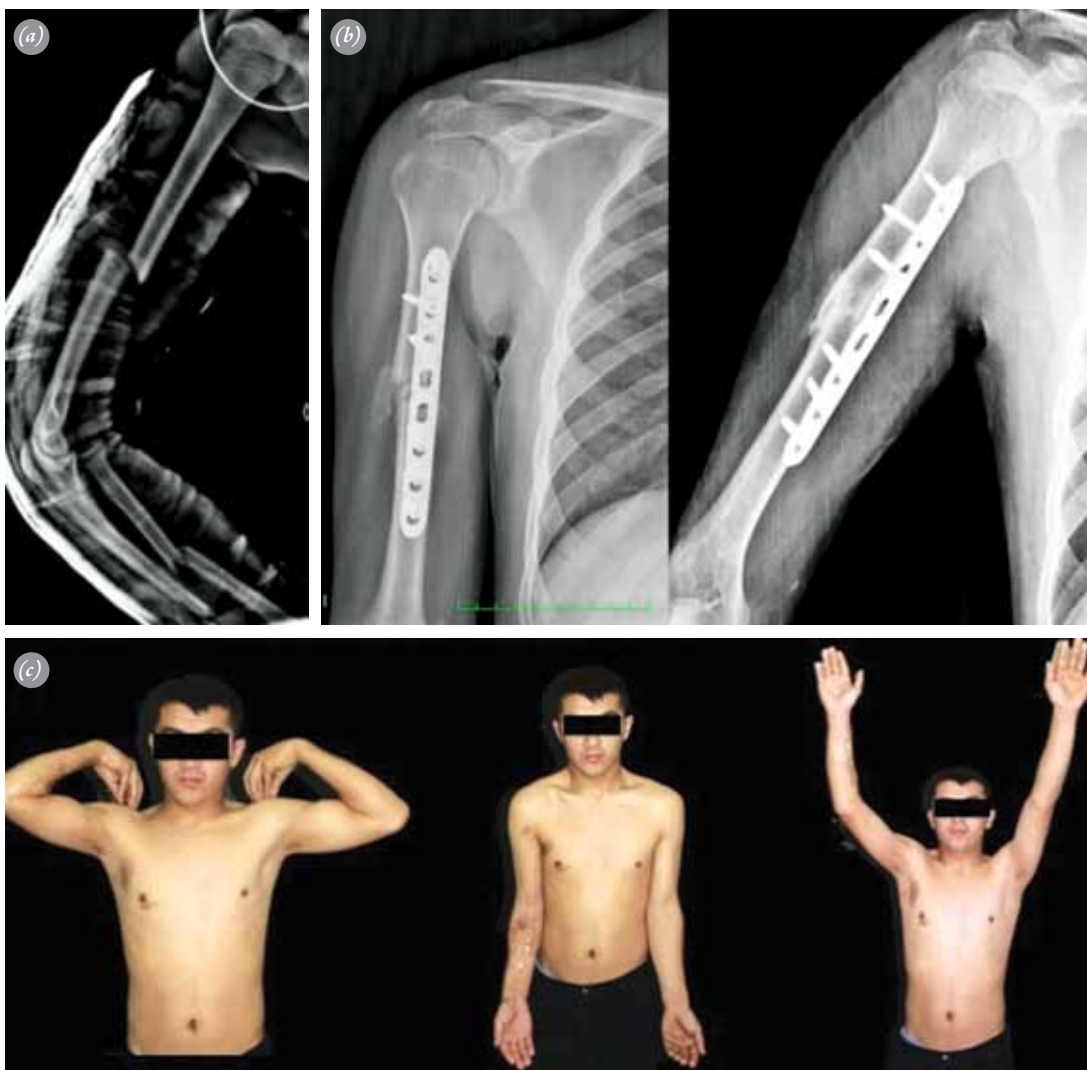


Fig. 2. (a) Motor vehicle accident; 19-year-old male patient with right floating elbow and radial nerve palsy. (b) Postoperative radiographs showing bone union at 4 months. (c) Functional results after fracture healing. [Color figure can be viewed in the online issue, which is available at www.aott.org.tr]

patient had transient radial nerve palsy due to surgery which fully recovered spontaneously within 6 months. Injury-related preoperative palsies resolved totally in 9 months. Complete recovery was observed in final follow-up of the two patients who experienced preoperative radial nerve palsy.

Discussion

While the majority of humerus shaft fractures are successfully treated by conservative methods,^[3,4] controversy regarding the ideal option of surgical fixation remains. The patient's clinical condition and activity level, fracture type and localization and the surgeon's experience are important determinants in deciding the most suitable alternative. Minimal invasive methods gained

popularity with bridging plate osteosynthesis in the last decade. However, few studies have reported on humerus fractures. In 2004, Livani and Belangero concluded that MIPPO is a feasible, safe and efficient method with no major complications in the treatment of humerus shaft fractures.^[15] Better results have also been reported with MIPPO compared to the conventional surgical techniques in terms of providing a shorter recovery time by early stabilization with minimal soft tissue damage.^[13] Aksu et al. reported early return of function in adjacent joints to the fracture site and reduced fracture healing time after MIPPO in humerus fractures.^[19] However, further clinical studies are needed to state the proven benefits of MIPPO in the treatment of humerus shaft fractures. In the present study, remarkable improvement in both objective and subjective measures was observed

Table 2. Results of the patients.

Patient#	Time of injury to surgery (days)	Follow-up (month)	Working length (mm)	Union time (weeks)	Shoulder abduction/forward flexion	Elbow Flexion/Extension	Surgical Complication	UCLA Score	ASES Score	MEPI Score	DASH Score	Malalignment
1	2	23	58	20	80/165	135/5	Superficial infection	34	96.6	95	4.2	4° valgus
2	3	18	36	14	90/170	130/0	None	32	91.9	90	5.8	2° valgus
3 (Left)	8	19	42	12	80/150	135/0	Transient RNP	29	81.6	90	7.5	None
3 (Right)	8	19	54	10	85/160	140/0	None	31	86.6	95	6.7	None
4	4	13	34	16	90/160	140/0	None	32	88.3	95	7.5	5° varus
5	5	21	52	12	85/160	135/0	None	31	91.6	95	6.7	None
6	12	30	48	18	90/170	140/0	None	34	93.3	100	4.2	None
7	8	12	40	14	90/165	125/20	None	30	89.9	85	5.8	None
8	1	24	38	10	90/165	135/15	Superficial infection	30	79.9	90	5.0	None
9	14	10	62	11	90/165	135/5	None	32	93.3	95	1.7	None
10	11	12	45	15	90/170	135/0	None	32	94.9	100	0.8	None
11	7	20	56	13	90/165	135/5	None	32	93.3	95	2.5	3° valgus
12	2	14	45	16	90/160	130/5	None	33	89.9	90	3.3	None
13	8	15	110	12	90/170	135/0	None	34	91.6	95	2.5	None

ASES: American Shoulder and Elbow Score, DASH: The Disability of The Arm, Shoulder and Hand, MEPI: Mayo elbow performance index, RNP: Radial nerve palsy, UCLA: University of California, Los Angles.

in the affected limbs at the final follow-up, with the exception of one patient with floating elbow. Despite the lack of a control group, we believe that the good results were related to the deltoid sparing approach, particularly in terms of shoulder function.

Although the MIPPO technique has many advantages, there is a general reluctance due to the concerns about neurovascular injury. Poor neurovascular monitorization, prolonged fluoroscopy time, difficulties in maintaining reduction and anatomic obstacles encountered during the advancement of the plate are factors complicating the procedure. Some cadaveric and clinical studies have been published on the proximity of the nerve and plate. Apivatthakakul et al. described the application of a percutaneous plate on the anterior surface of the humerus without the need of radial nerve exploration.^[20] Ji et al. emphasized that MIPPO through lateral approach is safe and feasible in the treatment of humeral shaft fractures.^[14] Regarding the close relation between the musculocutaneous nerve and the anterior compartment of the arm, Gardner et al.^[21] described the danger zones for musculocutaneous nerve in MIPPO of the humerus. They advised surgeons to make a longer skin incision and use an open approach to protect the musculocutaneous nerve during screw insertion. In our opinion, the radial nerve palsy observed in this study was due to over tightening of the nerve by a penetrating retractor (Hohmann retractor). Therefore, the use of this retractor was avoided and no other neurologic complication was seen.

Anatomical obstacles, which may interfere with the clinical outcomes, must be considered as well as neurovascular structures. It is well documented that disruption of the deltoid insertion is a serious problem, which often causes functional impairment.^[16] Preserving or reattaching the deltoid insertion has been highlighted in various studies.^[22,23] Our previous research experience in minimal invasive plating of the anterior humeral surface on 12 cadavers and the presented clinical study revealed that the anterior deltoid insertion is the main anatomical obstacles on the anterior humeral surface (Fig. 2). It was also noted that the release of more than 20% of the anterior deltoid insertion may compromise deltoid muscle function.^[16] Considering our previous anatomical research and the literature, we recommend antegrade advancement with the deltoid sparing approach in order to protect deltoid function.

In addition to the high risk of neurovascular injury, the difficulty in providing an 'optimal working length'

can be considered a limitation of this technique.^[24] However, we did not observe any failure due to the use of a shorter plate than recommended. This was contributed to the adequate implantation technique and screw placement (at least 6 cortices on each side), immediate rehabilitation and patients' orientation.

The relatively small number of patients and the absence of a comparison group is a possible limitation of this study. Therefore, further studies are necessary to compare minimal invasive osteosynthesis with alternative approaches to clarify the potential benefits of this technique.

In conclusion, MIPPO appears to be a promising and safe treatment alternative for humeral shaft fractures. In the application of the technique, the right intermuscular cleavage should be used and the plate engaged over the anterior surface keeping in touch with the bone during advancement, antegrade advancement of the plate is recommended to protect deltoid insertion and a minimum of six cortices per each side of the fracture should be applied to provide stable fixation. Consideration of the anatomical obstacles and soft tissue enhances the surgeon's ability to obtain adequate osteosynthesis with less compromise. Further clinical studies are needed to improve the technique.

Conflicts of Interest: No conflicts declared.

References

1. Igbigbi PS, Manda K. Epidemiology of humeral fractures in Malawi. *Int Orthop* 2004;28:338-41.
2. Tytherleigh-Strong G, Walls N, McQueen MM. The epidemiology of humeral shaft fractures. *J Bone Joint Surg Br* 1998;80:249-53.
3. Ekholm R, Ponzer S, Törnkvist H, Adami J, Tidermark J. The Holstein-Lewis humeral shaft fracture: aspects of radial nerve injury, primary treatment, and outcome. *J Orthop Trauma* 2008;22:693-7.
4. Toivanen JA, Nieminen J, Laine HJ, Honkonen SE, Järvinen MJ. Functional treatment of closed humeral shaft fractures. *Int Orthop* 2005;29:10-3.
5. Sarmiento A, Zagorski JB, Zych GA, Latta LL, Capps CA. Functional bracing for the treatment of fractures of the humeral diaphysis. *J Bone Joint Surg Am* 2000;82:478-86.
6. Perren SM. Evolution of the internal fixation of long bone fractures. The scientific basis of biological internal fixation: choosing a new balance between stability and biology. *J Bone Joint Surg Br* 2002;84:1093-110.
7. Yang KH. Helical plate fixation for treatment of comminuted fractures of the proximal and middle one-third of the humerus. *Injury* 2005;36:75-80.
8. Ziran BH, Belangero W, Livani B, Pesantez R. Percutaneous plating of the humerus with locked plating: technique and case report. *J Trauma* 2007;63:205-10.
9. Lin J, Hou SM. Locked nailing of severely comminuted or segmental humeral fractures. *Clin Orthop Relat Res* 2003;406:195-204.
10. Lau TW, Leung F, Chan CF, Chow SP. Minimally invasive plate osteosynthesis in the treatment of proximal humeral fracture. *Int Orthop* 2007;31:657-64.
11. Zhiqian A, Bingfang Z, Yeming W, Chi Z, Peiyan H. Minimally invasive plating osteosynthesis (MIPO) of middle and distal third humeral shaft fractures. *J Orthop Trauma* 2007;21:628-33.
12. Apivatthakakul T, Arpornchayanon O, Bavornratanavech S. Minimally invasive plate osteosynthesis (MIPO) of the humeral shaft fracture. Is it possible? A cadaveric study and preliminary report. *Injury* 2005;36:530-8.
13. Kobayashi M, Watanabe Y, Matsushita T. Early full range of shoulder and elbow motion is possible after minimally invasive plate osteosynthesis for humeral shaft fractures. *J Orthop Trauma* 2010;24:212-6.
14. Ji F, Tong D, Tang H, Cai X, Zhang Q, Li J, Wang Q. Minimally invasive percutaneous plate osteosynthesis (MIPPO) technique applied in the treatment of humeral shaft distal fractures through a lateral approach. *Int Orthop* 2009;33:543-7.
15. Livani B, Belangero WD. Bridging plate osteosynthesis of humeral shaft fractures. *Injury* 2004;35:587-95.
16. Klepps S, Auerbach J, Calhoun O, Lin J, Cleeman E, Flattow E. A cadaveric study on the anatomy of the deltoid insertion and its relationship to the deltopectoral approach to the proximal humerus. *J Shoulder Elbow Surg* 2004;13:322-7.
17. López-Arévalo R, de Llano-Temboury AQ, Serrano-Montilla J, de Llano-Giménez EQ, Fernández-Medina JM. Treatment of diaphyseal humeral fractures with the minimally invasive percutaneous plate (MIPPO) technique: a cadaveric study and clinical results. *J Orthop Trauma* 2011;25:294-9.
18. Jiang R, Luo CF, Zeng BF, Mei GH. Minimally invasive plating for complex humeral shaft fractures. *Arch Orthop Trauma Surg* 2007;127:531-5.
19. Aksu N, Karaca S, Kara AN, Işıklar ZU. Minimally invasive plate osteosynthesis (MIPO) in diaphyseal humerus and proximal humerus fractures. *Acta Orthop Traumatol Turc* 2012;46:154-60.
20. Apivatthakakul T, Patiyasikan S, Luevitoonvechkit S. Danger zone for locking screw placement in minimally invasive plate osteosynthesis (MIPO) of humeral shaft fractures: a cadaveric study. *Injury* 2010;41:169-72.
21. Gardner MJ, Griffith MH, Lorich DG. Helical plating of the proximal humerus. *Injury* 2005;36:1197-200.
22. Groh GI, Simoni M, Rolla P, Rockwood CA. Loss of the deltoid after shoulder operations: An operative disaster. *J*

- Shoulder Elbow Surg 1994;3:243-53.
23. Sher JS, Iannotti JP, Warner JJ, Groff Y, Williams GR. Surgical treatment of postoperative deltoid origin disruption. Clin Orthop Relat Res 1997;343:93-8.
24. Stoffel K, Dieter U, Stachowiak G, Gächter A, Kuster MS. Biomechanical testing of the LCP-how can stability in locked internal fixators be controlled? Injury 2003;34 Suppl 2:B11-9.