



# Humeral surface anatomy and percutaneous plate advancement: a cadaveric study

Gazi HURİ<sup>1</sup>, Ömer Sunkar BIÇER<sup>2</sup>, Akif MİRİOĞLU<sup>2</sup>, Hakan ÖZTÜRK<sup>3</sup>, Mehmet Ali DEVECİ<sup>2</sup>, İsmet TAN<sup>2</sup>

<sup>1</sup>Hacettepe University, Faculty of Medicine, Department of Orthopaedics and Traumatology, Ankara, Turkey;

<sup>2</sup>Çukurova University, Faculty of Medicine, Department of Orthopaedics and Traumatology, Adana, Turkey;

<sup>3</sup>Mersin University, Faculty of Medicine, Department of Anatomy, Mersin, Turkey

**Objective:** The aim of this study was to identify the anatomical obstacles on the humeral surface which can complicate subcutaneous plate advancement during surgical treatment of humeral fractures.

**Methods:** We dissected twelve upper extremities of six male cadavers, and measured the humeral length, which was defined as the distance between the greater tubercle and the lateral epicondyle. We performed a retrograde advancement of a 4.5 mm plate through the subbrachial tunnel and noted the mechanical obstacles during the procedure. In addition, we recorded the distances between the anatomic obstacles and lateral epicondyle.

**Results:** The average humeral length was 271.8 mm. We identified anterior insertion of the deltoid muscle and the proximal part of the brachialis muscle as the main anatomic obstacles on the anterior surface of the humerus. The average distances between the lateral epicondyle and the most proximal and distal insertion of anterior deltoid were 188.9 mm and 138.7 mm, respectively. The average distance between the lateral epicondyle and the brachialis origin was 147.4 mm. Proportions of the distances between the lateral epicondyle and proximal of anterior deltoid insertion, the lateral epicondyle and distal of anterior deltoid insertion and the lateral epicondyle and proximal of brachialis origin to humeral length were 69.4%, 51%, and 54.2%, respectively. There was a high interobserver reliability ( $p < 0.001$ ).

**Conclusion:** The deltoid insertion and proximal attachment of the brachialis muscles were identified as mechanical obstacles when performing the percutaneous plating. These sites caused difficulties with the procedure during the retrograde plate advancement through submuscular tunnel on the anterior surface of humerus. It was also noted that for successful plate advancement, it was necessary to release the anterior part of the deltoid insertion.

**Key words:** Humerus; minimal invasive plate osteosynthesis; cadaver; fracture.

Humerus shaft fractures represent approximately 1-7% of all fractures. A majority of these fractures occur in the elderly population due to low energy trauma.<sup>[1]</sup> Although the first line of treatment for these fractures is conserva-

tive measures, surgical management is still indicated in certain situations including polytrauma patients, open fractures, vascular injury, floating elbow injuries, and fractures that fail nonsurgical management.<sup>[1-3]</sup> Further-

**Correspondence:** Gazi Huri, MD. Hacettepe Tıp Fakültesi Ortopedi ve Travmatoloji Anabilim Dalı, 06100 Ankara, Turkey.

Tel: +90 312 – 305 12 09 e-mail: gazihuri@hacettepe.edu.tr

**Submitted:** November 12, 2012 **Accepted:** January 06, 2014

©2014 Turkish Association of Orthopaedics and Traumatology

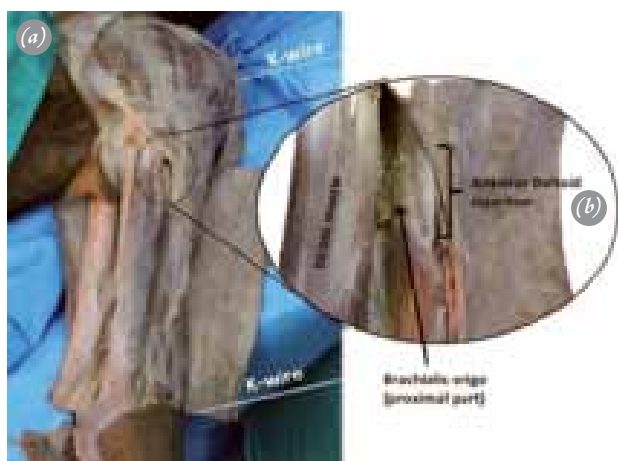
Available online at

www.aottt.org.tr

doi: 10.3944/AOTT.2014.3110

QR (Quick Response) Code





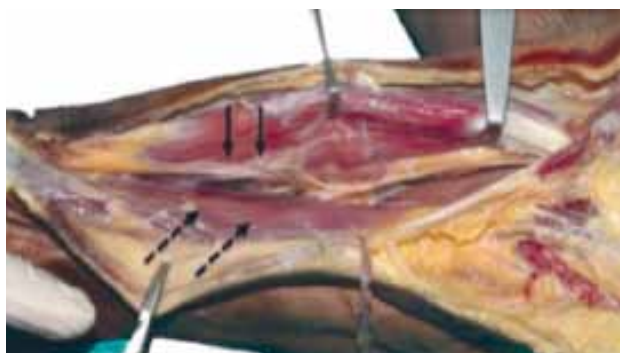**Fig. 1.** Anterior aspect of the arm. **(a)** The proximal part of greater tubercle and the prominence of the lateral epicondyle were marked by K-wires and measured as the humeral length **(b)** a closer view of anatomic obstacles on anterior humeral surface; anterior part of deltoid muscle insertion and the most proximal part of brachialis muscle origin. [Color figure can be viewed in the online issue, which is available at [www.aott.org.tr](http://www.aott.org.tr)]

more, the faster functional recovery and return to work have also dramatically increased the popularity of the surgical treatment.<sup>[4]</sup>

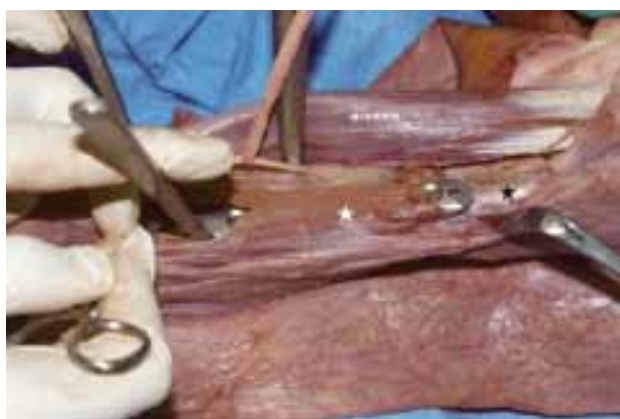Numerous surgical options for the stabilization of humeral shaft fractures have been described, including conventional plating, intramedullary nailing, and external fixation. More recently, some authors have advocated the use of minimally invasive plate osteosynthesis (MIPO) techniques, especially for management of highly comminuted humeral shaft fractures.<sup>[5-11]</sup> MIPO is gaining popularity because it is believed to minimize the disruption of fracture biology, limit the dissection, and enhance the fracture healing process. This technique is typically performed through a submuscular tunnel via an anterior approach, which protects the posteriorly located radial nerve.<sup>[10]</sup>

Even though the MIPO technique has many advantages such as the early recovery of motion and high union rates ranging from 90% to 100%, the procedure also involves serious risks and complications.<sup>[4,11]</sup> Poor neurovascular monitorization, prolonged fluoroscopy time, difficulties in maintaining reduction, and mechanical obstacles that are encountered during the advancement of the plate can be regarded as the factors that challenge the procedure.

Since the anterior surface of humerus is the preferred site for MIPO, there are several studies focused on the risks of anterior neurovascular injury during the procedure.<sup>[12-14]</sup> However, mechanical obstacles on the anterior surface of the humerus, which might be encountered



**Fig. 2.** The anterolateral view of the brachialis muscle (broken arrows) after retraction of the biceps brachii muscle medially exposing the musculocutaneous nerve (solid arrows). [Color figure can be viewed in the online issue, which is available at [www.aott.org.tr](http://www.aott.org.tr)]



**Fig. 3.** Subbrachial tunnel through which a 4.5 mm narrow locking plate was advanced retrogradely. Proximal part of brachialis origin (white star) and anterior deltoid insertion (black star) are observed as the main obstacles. [Color figure can be viewed in the online issue, which is available at [www.aott.org.tr](http://www.aott.org.tr)]

during the plate advancement, have not been studied previously. We hypothesized that the muscles that attach to the anterior surface are mechanical obstacles that interfere the plate advancement over the anterior surface of humerus during the MIPO procedure. In this study, we aimed to confirm the presence of these obstacles and identify their specific locations.

## Materials and methods

Twelve upper extremity specimens of 6 adult male cadavers were used for the study in the department of anatomy faculty of medicine at Mersin University. The average age of the cadavers was 61.8 years (range: 45-72 years). No specimen had prior history of significant trauma or previous upper extremity surgery. The dissections were performed in supine position, the arm in 60° of abduction and the forearm in full supination to examine the anterior region of the arm. In order to observe the gross



**Fig. 4.** (a) Proximal (broken arrow) and distal (solid arrow) points of anterior deltoid insertion, and proximal part of brachialis muscle origin (arrow head) were marked with K-wires. (b) Morphometric measurements held by digital calipers. [Color figure can be viewed in the online issue, which is available at [www.aott.org.tr](http://www.aott.org.tr)]

anatomy of the muscles and fascicle orientation, the skin and subcutaneous tissue were dissected from the anterior shoulder to the distal elbow. The proximal part of the greater tuberosity and the prominence of the lateral epicondyle were marked with K-wires and the distance between the wires was measured as the humeral length (Fig. 1a). To expose of the brachialis muscle and the musculocutaneous nerve, the interval between the biceps brachii and brachialis was identified, and the biceps brachii was retracted medially (Fig. 2). The deltoid and brachialis muscles were exposed from their origins to insertions with care not to disturb the integrity of the muscles. The distal part of brachialis was then divided longitudinally along its midline to reach the periosteum of the anterior cortex of the humerus. Subsequently, a submuscular extraperiosteal tunnel was prepared between the brachialis muscle and humerus with a periosteal elevator. Then, we performed a retrograde advancement of a 4.5 mm narrow plate through this tunnel to identify which obstacles may interfere with the plate advancement during the MIPO procedure (Fig. 3).

All anatomic obstacles were marked with K-wires to determine their levels on the humeral shaft (Fig. 4a). At the end of each procedure, the distances between the anatomic obstacles and lateral epicondyle were measured and recorded. All measurements were performed using a digital caliper (Fig. 4b). Each measurement was repeated 3 times, each time by different investigators (two senior orthopaedic surgeons and one anatomist). The proportions of the distances between the lateral epicondyle and the anatomic obstacles to humeral length were calculated. The interobserver reliability (kappa value) was calculated using IBM SPSS Statistics version 20.

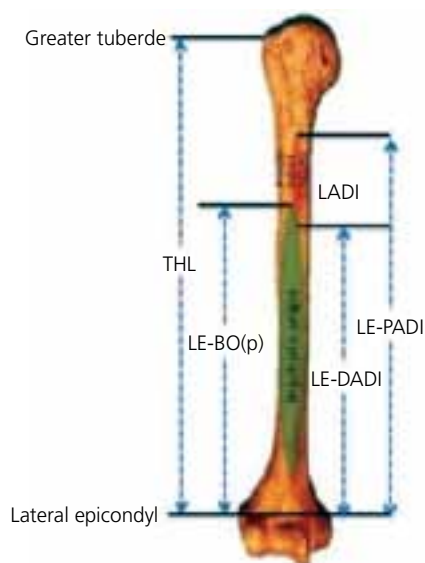
## Results

The average humeral length was 271.8 mm (range: 253.3-287.9 mm) (Table 1). The anatomic obstacles during retrograde plate advancement were detected on the proximal half of the humerus, including the anterior part of the deltoid muscle insertion (Fig. 1b) and the most proximal part of the brachialis origin (Fig. 3). The average length of the anterior aspect of the deltoid

**Table 1.** Morphometric measurements of the specimens.

Cadaver no	1		2		3		4		5		6	
	RA	LA	RA	LA	RA	LA	RA	LA	RA	LA	RA	LA
THL	271.4	273.36	253.3	253.9	287.87	275.8	279.4	287.34	275.3	271.85	267.38	264.2
LE-DADI	137.81	136.61	137.12	133.16	134.75	136.9	148.2	151.15	138.7	138.98	136.56	134.23
LE-PADI	186.53	208.56	183.9	181.9	190.1	191.34	193.52	198.62	181.58	188.82	182.22	178.81
LE-BO (p)	145.71	141.83	148.8	145.33	148.66	151.47	149.62	154.48	145.33	149.98	145.22	142.46
LADI	41.82	39.73	35.7	36.57	41.44	39.57	37.8	39.4	36.25	38.84	38.56	37.27

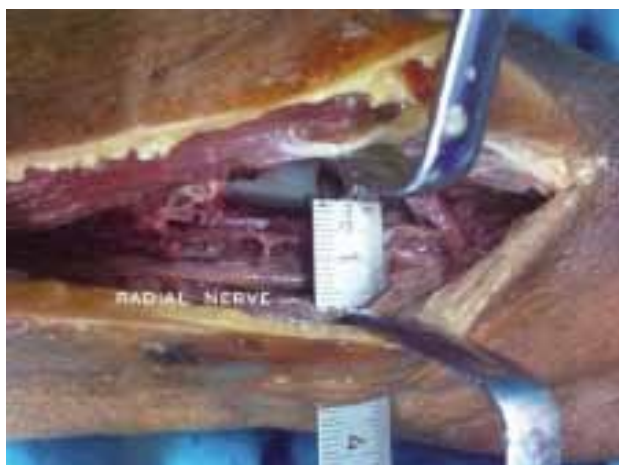THL: Total humeral length; LE-DADI: Lateral epicondyle-Distal of anterior deltoid insertion; LE-PADI: Lateral epicondyle-Proximal of anterior deltoid insertion; LE-BO (p): Lateral epicondyle-Brachialis origin (proximal); LADI: Length of anterior deltoid insertion; RA: Right arm; LA: Left arm.



**Fig. 5.** Anterior view of humerus. Black line: K wire, THL: Total humeral length, LE-DADI: Lateral epicondyle-Distal of anterior deltoid insertion, LE-PADI: Lateral epicondyle-Proximal of anterior deltoid insertion, LE-BO(p): Lateral epicondyle-Brachialis origin (proximal), LADI: Length of anterior deltoid insertion. [Color figure can be viewed in the online issue, which is available at [www.aott.org.tr](http://www.aott.org.tr)]

insertion was 38.6 mm (range: 35.7-41.8 mm). The distance between the lateral epicondyle and anterior deltoid insertion was on average 188.9 mm proximally (range: 178.8-208.6 mm) and 138.7 mm distally (range: 133.2-151.2 mm). The distance between the lateral epicondyle and the most proximal part of the brachialis origin was on average 147.4 mm (141.2-154.4 mm). The proportions of the distances between the lateral epicondyle and proximal of anterior deltoid insertion, lateral epicondyle and distal of anterior deltoid insertion and lateral epicondyle and proximal of brachialis origin to humeral length were 69.4%, 51%, and 54.2%, respectively (Fig. 5).

An interobserver reliability analysis using the Kappa statistic was performed to determine consistency among raters. The interobserver reliability (kappa value) for the measurements of total humeral length (THL), the distance between lateral epicondyle and distal of anterior deltoid insertion (LE-DADI), the distance from lateral epicondyle to proximal of anterior deltoid insertion (LE-PADI), distance between lateral epicondyle and brachialis origin (proximal) LE-BO(p) and the length of anterior deltoid insertion (LADI), were found to be 0.81 ( $p < 0.001$ ), 0.67 ( $p < 0.001$ ), 0.62 ( $p < 0.001$ ), 0.71 ( $p < 0.001$ ) and 0.74 ( $p < 0.001$ ), respectively. These values indicate high interobserver reliability.



**Fig. 6.** Proximity of the radial nerve in the distal one third of the humerus. [Color figure can be viewed in the online issue, which is available at [www.aott.org.tr](http://www.aott.org.tr)]

## Discussion

Although humeral shaft fractures have successfully been treated by conservative means, surgical intervention may also be needed under certain instances.<sup>[3]</sup> Recently some authors proposed the MIPO technique for the management of humeral shaft fractures, however, the proximity of neurovascular structures and anatomic obstacles make the procedure a challenging alternative.<sup>[10,12,14,15]</sup> To our knowledge, both clinical and cadaveric studies have been published in order to define the danger zones of the humeral shaft for screw placement. These studies indicate that improper screw placement can cause damage to the musculocutaneous and radial nerves in the anterior compartment during the MIPO technique; however, the mechanical obstacles in this technique have not been thoroughly studied.<sup>[13,15]</sup> In this study, the anterior part of the deltoid insertion and proximal part of the brachialis origin have been detected as the main obstacles encountered during the retrograde advancement of the plate on the anterior humeral surface in this minimally invasive technique. To our knowledge, this is the first study demonstrating the significance of mechanical obstacles on the anterior surface of the humerus while performing MIPO.

Fixation techniques for humeral shaft fractures have significantly changed over the last two decades.<sup>[16]</sup> Besides the treatment of comminuted fractures of the tibia and femur, the use of minimally invasive techniques for the treatment of humeral fractures has dramatically increased.<sup>[11,17-21]</sup> Several publications have demonstrated the safe and efficient use of MIPO in humeral shaft fractures with insertion of bridge plates. Livani et al. has initially described the biological advantages and satisfactory



clinical outcomes of MIPO for humeral shaft fractures.<sup>[19]</sup> Apivatthakakul et al. have reported the advantages of minimally invasive technique for humerus fractures via anterior approach in a cadaveric study.<sup>[12]</sup> Furthermore Zhiquan et al. have concluded that MIPO is a safe alternative treatment for humeral shaft fractures with less soft tissue dissection, less nonunion rates, less iatrogenic fractures, and low risk of iatrogenic nerve injury.<sup>[11]</sup> This technique also allows early functional treatment and good range of motion in adjacent joints postoperatively.<sup>[4]</sup> These advantages appear to indicate that MIPO may be superior to other fixation techniques.

While inserting the instrument, the mechanical obstacles on the anterior surface of the humerus should be well established for a safer surgery. In our study, two main anatomic structures were observed to be mechanical obstacles on the anterior surface of humerus and posed a threat to interfering with the MIPO approach. The convergence of fascial structures constituted by the anterior part of deltoid insertion and pectoralis major insertion was the first obstacle, and the proximal part of brachialis muscle origin was the second one. The deltoid muscle inserts into the deltoid prominence on the middle of the anterior, lateral and posterior side of the body of the humerus.<sup>[22]</sup> At its insertion, the muscle gives off an expansion to the deep fascia of the arm and combines with the pectoralis muscle fascia. All these fascial structures meeting at the lower limit of the deltoid insertion forms a thick and strong barrier, which may cause plate malposition and necessitate detachment of the anterior deltoid insertion in order to properly, advance the plate on the anterior humeral surface in the retrograde direction.

The brachialis muscle arises from the lower half of the anterior humerus, commencing above at the insertion of the deltoid.<sup>[23]</sup> On either side of the arm, the brachialis fascia gives off a strong intermuscular septum. The lateral intermuscular septum extends from the lower part of the crest of the greater tubercle, along the lateral supracondylar ridge, to the lateral epicondyle; it is blended with the tendon of the deltoid muscle and gives attachment to the brachialis in front. Therefore, the retrograde preparation of the extraperiosteal tunnel between the brachialis muscle and humerus with a periosteal elevator during MIPO may be quite damaging due to the wide origin of brachialis on the anterior surface of humerus.

Furthermore, we also observed that due to the thick insertion of the deltoid on the humerus, release of deltoid anterior insertion was necessary in order to slide the plate on the anterior surface. However, it is well documented that detachment of the deltoid from its ante-

rior part of insertion is a serious and often catastrophic problem. Klepps et al, in a cadaveric study, noted that release of greater than 1/5 of the anterior deltoid insertion could compromise the anterior deltoid, which may cause functional weakness and avulsions.<sup>[22]</sup> Therefore, the anterograde approach might be a reasonable alternative in order to bypass these obstacles and protect the integrity of deltoid insertion.

This study also showed that the distal half of the humerus is the obstacle free area for MIPO, despite the fact that the radial nerve is still at risk (Fig. 6). It must be recognized that regardless of the direction of the plate advancement, particular attention should be paid to avoid neurovascular injuries during MIPO for humeral fractures.

Our study had some limitations. First, the properties of *in vivo* tissues are different from that of cadavers, which limits the direct transfer of the data into clinical practice. Second, because this study used cadaveric specimens, there was no issue with bleeding, which is a clinically significant risk in surgical cases and can make the procedure challenging. In addition, increasing the number of the specimens may improve the limitations of this study, since identification of the anatomic variations requires larger series.

The current study demonstrated that the humeral attachment of both deltoid and brachialis muscles are main mechanical obstacles encountered during retrograde plate advancement through the submuscular tunnel on the anterior surface of the humerus. It also showed that releasing the anterior part of the deltoid insertion is necessary for creating an optimal submuscular tunnel on the humerus. Although the findings reported in the current study may include essential information about minimally invasive plate application and positioning, they have not been addressed previously. In terms of the plate advancement, even an antegrade advancement plate appears to be a reasonable alternative in order to bypass the mechanical obstacles; it was not proven in this study. In the future, regarding the mechanical obstacles, specific plate designs or surgical techniques should be invented in order to enhance the MIPO technique for humerus fractures.

**Conflicts of Interest:** No conflicts declared.

## References

1. Ekholm R, Adami J, Tidermark J, Hansson K, Törnkvist H, Ponzer S. Fractures of the shaft of the humerus. An epidemiological study of 401 fractures. *J Bone Joint Surg Br* 2006;88:1469-73. [CrossRef](#)

2. Toivanen JA, Nieminen J, Laine HJ, Honkonen SE, Järvinen MJ. Functional treatment of closed humeral shaft fractures. *Int Orthop* 2005;29:10-3. [CrossRef](#)
3. Sarmiento A, Zagorski JB, Zych GA, Latta LL, Capps CA. Functional bracing for the treatment of fractures of the humeral diaphysis. *J Bone Joint Surg Am* 2000;82:478-86.
4. Kobayashi M, Watanabe Y, Matsushita T. Early full range of shoulder and elbow motion is possible after minimally invasive plate osteosynthesis for humeral shaft fractures. *J Orthop Trauma* 2010;24:212-6. [CrossRef](#)
5. Marsh JL, Mahoney CR, Steinbronn D. External fixation of open humerus fractures. *Iowa Orthop J* 1999;19:35-42.
6. Lin J, Hou SM. Antegrade locked nailing for humeral shaft fractures. *Clin Orthop Relat Res* 1999;365:201-10.
7. Ajmal M, O'Sullivan M, McCabe J, Curtin W. Antegrade locked intramedullary nailing in humeral shaft fractures. *Injury* 2001;32:692-4. [CrossRef](#)
8. Meekers FS, Broos PL. Operative treatment of humeral shaft fractures. The Leuven experience. *Acta Orthop Belg* 2002;68:462-70.
9. Aksu N, Karaca S, Kara AN, Işıklar ZU. Minimally invasive plate osteosynthesis (MIPO) in diaphyseal humerus and proximal humerus fractures. *Acta Orthop Traumatol Turc* 2012;46:154-60. [CrossRef](#)
10. Jiang R, Luo CF, Zeng BF, Mei GH. Minimally invasive plating for complex humeral shaft fractures. *Arch Orthop Trauma Surg* 2007;127:531-5. [CrossRef](#)
11. Zhiquan A, Bingfang Z, Yeming W, Chi Z, Peiyan H. Minimally invasive plating osteosynthesis (MIPO) of middle and distal third humeral shaft fractures. *J Orthop Trauma* 2007;21:628-33. [CrossRef](#)
12. Apivatthakakul T, Arpornchayanon O, Bavornratanavech S. Minimally invasive plate osteosynthesis (MIPO) of the humeral shaft fracture. Is it possible? A cadaveric study and preliminary report. *Injury* 2005;36:530-8. [CrossRef](#)
13. Apivatthakakul T, Patiyasikan S, Luevitoonvechkit S. Danger zone for locking screw placement in minimally invasive plate osteosynthesis (MIPO) of humeral shaft fractures: a cadaveric study. *Injury* 2010;41:169-72. [CrossRef](#)
14. Livani B, Belangero WD, Castro de Medeiros R. Fractures of the distal third of the humerus with palsy of the radial nerve: management using minimally-invasive percutaneous plate osteosynthesis. *J Bone Joint Surg Br* 2006;88:1625-8.
15. López-Arévalo R, de Llano-Temboury AQ, Serrano-Montilla J, de Llano-Giménez EQ, Fernández-Medina JM. Treatment of diaphyseal humeral fractures with the minimally invasive percutaneous plate (MIPPO) technique: a cadaveric study and clinical results. *J Orthop Trauma* 2011;25:294-9. [CrossRef](#)
16. Perren SM. Evolution of the internal fixation of long bone fractures. The scientific basis of biological internal fixation: choosing a new balance between stability and biology. *J Bone Joint Surg Br* 2002;84:1093-110. [CrossRef](#)
17. Ricci AR, Yue JJ, Taffet R, Catalano JB, DeFalco RA, Wilkens KJ. Less Invasive Stabilization System for treatment of distal femur fractures. *Am J Orthop (Belle Mead NJ)* 2004;33:250-5.
18. Naik MA, Arora G, Tripathy SK, Sujir P, Rao SK. Clinical and radiological outcome of percutaneous plating in extra-articular proximal tibia fractures: a prospective study. *Injury* 2013;44:1081-6. [CrossRef](#)
19. Livani B, Belangero WD. Bridging plate osteosynthesis of humeral shaft fractures. *Injury* 2004;35:587-95. [CrossRef](#)
20. Wagner M. General principles for the clinical use of the LCP. *Injury* 2003;34 Suppl 2:B31-42. [CrossRef](#)
21. Ji F, Tong D, Tang H, Cai X, Zhang Q, Li J, et al. Minimally invasive percutaneous plate osteosynthesis (MIPPO) technique applied in the treatment of humeral shaft distal fractures through a lateral approach. *Int Orthop* 2009;33:543-7. [CrossRef](#)
22. Klepps S, Auerbach J, Calhoun O, Lin J, Cleeman E, Flattow E. A cadaveric study on the anatomy of the deltoid insertion and its relationship to the deltopectoral approach to the proximal humerus. *J Shoulder Elbow Surg* 2004;13:322-7. [CrossRef](#)
23. Leonello DT, Galley IJ, Bain GI, Carter CD. Brachialis muscle anatomy. A study in cadavers. *J Bone Joint Surg Am* 2007;89:1293-7.