



A rare case of primary psoas abscess causing hip pain in a patient with hip replacement

Baljinder S. DHINSA, Hani B. ABDUL-JABAR, Shanmugasundaram RAJKUMAR, Tony KOCHHAR

Queen Elizabeth Hospital, Department of Trauma and Orthopedics, London, United Kingdom

The number of primary hip replacement procedures performed each year has exponentially increased, with a subsequent increase in associated revision procedures. Prosthetic infection is a serious concern for all arthroplasty surgeons. Psoas abscess is a rare condition with unknown etiology, and diagnosis is often missed or delayed, with subsequent increased morbidity, mortality and even possible inappropriate management. We report a patient presenting with a total hip replacement complaining of sepsis and right hip pain. No focus for the infection was isolated and an open washout of the right hip was performed due to suspected prosthesis infection. Investigations identified a psoas abscess with no evidence of prosthesis loosening. The psoas abscess was drained and the patient improved without the need to revise the prosthesis.

Key words: Hip replacement; prosthesis; psoas abscess; septic arthritis.

The National Joint Registry of England, Wales and Northern Ireland (NJR) reported that 65,229 primary hip replacement procedures and 7,136 hip revision procedures were performed in 2009.^[1] Prosthetic hip infection is a serious complication that is most often managed by prosthesis extraction, thorough washout and a period of antibiotics. Revision procedures are a major undertaking and the decision to perform such procedures should not be taken without due consideration.

Due to its relative rarity, primary psoas abscess remains a difficult diagnosis, often leading to delay, inappropriate investigations and confusion with septic arthritis.^[2] We describe a case of psoas abscess following primary hip replacement that highlights the difficulties in diagnosis, as well as the need to rule out other extra-articular causes before embarking on revision procedures for suspected prosthetic infection.

Case report

An 81-year-old male presented to the Accident and Emergency Department with a two-week history of lethargy, right groin pain and progressive fever. The patient had undergone a right cemented total hip replacement 6 years prior to admission that remained asymptomatic until this acute presentation. The pain was localized to the groin and described as constant in nature and exacerbated with all hip movements. The patient had a past medical history of controlled hypertension and hyperlipidemia. Clinical examination revealed a painful right hip joint with inability to weight-bear, limited straight leg raise to 10 degrees and globally reduced range of movements of extension to 5 degrees, flexion to 60 degrees and adduction and abduction to 5 degrees. Plain radiographs of the pelvis demonstrated no obvious lysis or loosening of the hip prosthesis, while serology reported a raised

Correspondence: Baljinder S. Dhinsa, MD, MBBS, MRCS, 16 Yeoman Drive, Darland View, Gillingham Kent ME7 3EL, United Kingdom.

Tel: +44 79 – 7100 0972 e-mail: bsd14@hotmail.com

Submitted: July 24, 2012 **Accepted:** September 17, 2013

©2014 Turkish Association of Orthopaedics and Traumatology

Available online at
www.aott.org.tr

doi: 10.3944/AOTT.2014.2994

QR (Quick Response) Code



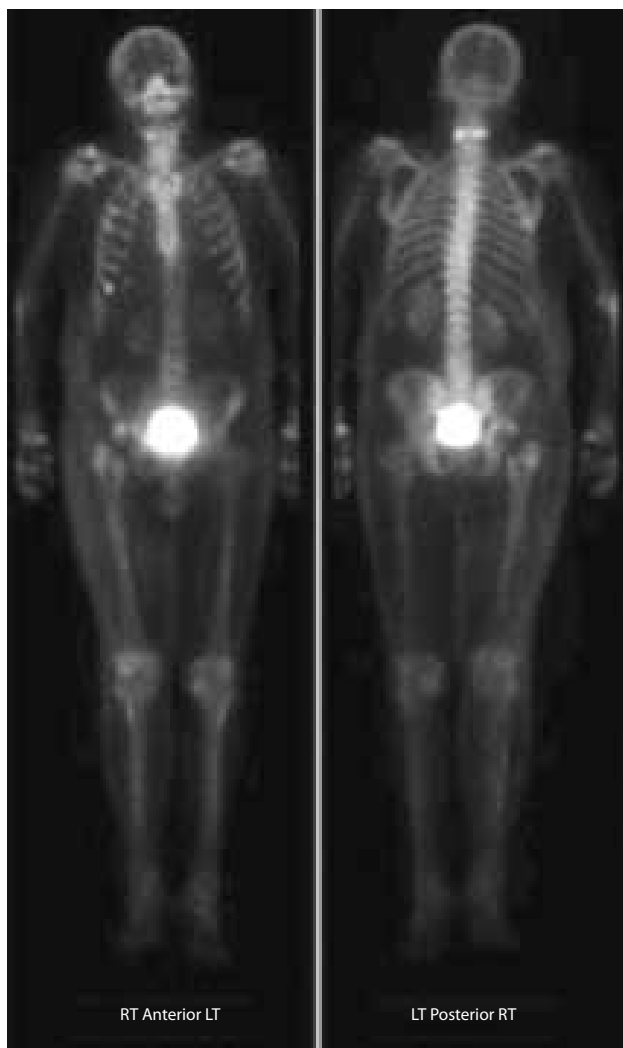


Fig. 1. Bone scan demonstrating increased uptake in the right pelvis and proximal femur.

neutrophil and C-reactive protein count of 246 mg/L (laboratory normal range is less than 5 mg/L). Blood cultures grew scanty *Staphylococcus aureus* sensitive to vancomycin.

As the patient was septic with an unknown source, vancomycin was initiated immediately as per the microbiologist's advice. However, after 48 hours of parenteral antibiotics, there was no improvement in his symptoms or serology. No other source of infection was identified other than a possible right hip implant infection. As the patient was acutely unwell and antibiotics had previously been initiated, an open arthrotomy was performed for both diagnostic and treatment purposes, rather than a diagnostic aspiration.

The patient underwent a right hip arthrotomy and debridement in the operating theater. While a small pocket of serous fluid was found superficial to the greater

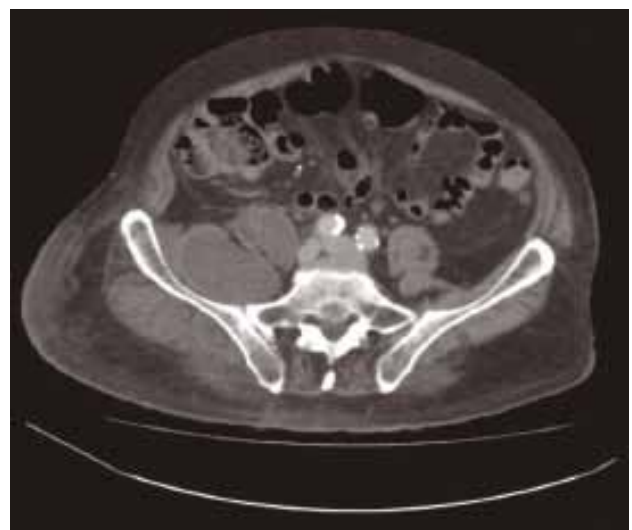

Fig. 2. A CT scan demonstrating a right-sided iliopsoas compartment collection.

trochanter intraoperatively, the hip joint appeared normal with no evidence of intra-articular infection. The hip prosthesis was not checked for stability or loosening. Intraoperative microbiology samples from the previously mentioned pocket grew scanty *Staphylococcus aureus*; empirical flucloxacillin and fusidic acid treatment was initiated following microbiology advice.

Forty-eight hours after surgery, there was no improvement in the patient's clinical symptoms or serological markers. An urgent bone scan was performed which highlighted a slight uptake in the right acetabulum, suggestive of a possible loosening or infection (Fig. 1). The hospital infection control team recommended a staged revision procedure for a likely infected right hip prosthesis. An opinion was sought from a revision hip arthroplasty surgeon (senior author, SR) who felt that the bone scan was inconclusive. On further clinical examination and symptomatic evaluation, he felt that the hip joint was normal and the hip pain was originating from an extra-articular source, such as a potential psoas abscess. A computed tomography (CT) scan was taken to determine the presence of intra-pelvic pathology and clearly reported a right psoas abscess measuring 6x7 cm at the level of the iliac bone extending down to the iliopsoas muscle insertion into the right femur (Fig. 2). The collection did not appear to communicate with the hip joint and remained entirely extra-articular.

An ultrasound-guided drainage of the abscess produced purulent material that grew *Staphylococcus aureus* on culture. The patient improved symptomatically with the current antibiotics. His serology returned to normal values within the week and he was able to bear weight

comfortably. A repeat CT scan revealed complete resolution of the abscess and a plain radiograph demonstrated that the prosthesis is still very well positioned with no evidence of early loosening. The patient completed a 6-week course of oral antibiotics which achieved full elimination of clinical symptoms and led to a full pain-free weight-bearing status and normal gait at the 2nd month follow-up. He continues to be symptom-free and was last seen 2 years after initial acute presentation.

Discussion

The psoas muscle is a retroperitoneal structure originating from the twelfth thoracic vertebra to the fifth lumbar vertebra and inserts on the lesser trochanter of the femur.^[3] It is prone to infection either primarily or secondary to contiguous and hematogenous spread. Psoas abscesses consist of a purulent collection in the iliopsoas compartment resulting in the classical symptoms of fever, iliac fossa pain, hip and lumbar pain, with pain on minimal hip movements.^[3]

Primary psoas abscesses have unknown etiology, with a reported association to either trauma or poor nutrition. The most common organism grown in culture is *Staphylococcus aureus*.^[4] Secondary psoas abscesses develop by hematogenous spread and contiguous infections from Crohn's disease, diverticulitis, osteomyelitis, tuberculosis of the vertebrae, perinephric infections and postoperative unforeseen complications.^[3] The mainstay of psoas abscess treatment has been formal drainage followed by appropriate antibiotic administration. However, in cases with acute hematogenous prosthetic infection, implant removal may be required and a staged procedure is usually planned through a multi-disciplinary approach.^[5] Aspiration of the hip joint with the aid of radiological guidance remains a valuable diagnostic tool in aiding the initial diagnosis and formulation of future management.

The infrequent presentation of psoas abscesses in the adult and pediatric setting remains a clinical challenge and a diagnostic puzzle. The present case was also complicated by the presence of a total hip replacement. Hip pain following total hip arthroplasty is not uncommon and causes are often identifiable. Possible causes include infection, aseptic loosening, dislocation, psoas tendonitis secondary to impingement and nerve root injury, as well as peripheral nerve injury, internal hernia, stress fractures and tissue reactions to wear debris. The ramifications of a potentially infected prosthesis are huge for both the patient and the healthcare provider.

Dauchy et al. reported a 12% association between a psoas abscess and prosthetic hip infections.^[5] Published case series and various case reports within the literature

have demonstrated a similar relationship.^[5,6] The most plausible explanation is that iliac bone insult as a result of acetabular cup screws or previous surgery establishes a communication between the implant and iliopsoas compartment.^[5] In our case, the primary psoas abscess presented as hip pain in a patient with a previously well-functioning cemented total hip replacement implant and was mistaken for a prosthetic infection.

It is vital that such patients are thoroughly investigated to rule out both intra- and extra-articular causes of hip pain in a previously well-fixed and functioning hip implant. A CT scan is often deferred due to the difficulties in interpretation caused by the suspected artifact from the prosthesis. However, scans with metal artifact reduction sequences can address this problem. Ultrasound has been proven to be effective in demonstrating the presence of an abscess as well as hip joint effusion. However, it cannot be used in the diagnosis of prosthetic infection,^[7] for which a bone scan is an added useful tool. Magnetic resonance imaging (MRI) scans also have a role in evaluating possible soft tissue infection, collection and neoplasm.

The present case highlighted the impact of a number of mistakes made in formulating a diagnosis and subsequent management. Empirical antibiotics were initiated on the advice of the microbiologists based on the septic state of the patient and blood culture results. However, given the history and clinical examination, it would have been appropriate to perform an urgent diagnostic hip aspiration on admission prior to starting antibiotics to aid diagnosis and microbiology if the aspiration was positive. The senior surgeon did not feel it was an appropriate investigation at that stage given the possible further delay, as the patient was acutely unwell and antibiotics had been initiated. An open arthrotomy was performed, as it could be diagnostic as well as aid management if intra-articular infection was present. Prior to any intervention, further imaging should be considered, such as a CT scan or ultrasound, to assess for any abdominal/extra-articular collection. These measures would have prevented an unnecessary invasive procedure being performed and would be compliant with expected diagnostic tree for such presentations.

In conclusion, the management of choice for psoas abscess remains an initial accurate diagnosis, formal drainage and initiation of antibiotics once microbiology samples have been obtained. This case highlights the importance of thorough clinical examination and added radiological evaluation to rule out other rare intra- and extra-articular causes of hip pain. Full intraoperative assessment of the prosthesis stability through an open

arthrotomy remains crucial in preventing unnecessary revision procedures.

Conflicts of Interest: No conflicts declared.

References

1. National Joint Registry Centre. National Joint Registry for England and Wales: 7th Annual Report 2010. National Joint Registry Centre [Internet]. 2011 [cited 11 December 2011]. Available from: <http://www.njrcentre.org.uk/NjrCentre/Portals/0/NJR%207th%20Annual%20Report%202010.pdf>.
2. Toren A, Ganel A, Lotan D, Graif M. Delayed diagnosis of a primary psoas abscess mimicking septic arthritis of the hip. *J Pediatr Surg* 1989;24:227-8. [CrossRef](#)
3. Sathyamoorthy P. Primary psoas abscess: case report and review of the literature. *Singapore Med J* 1992;33:201-3.
4. Gordin F, Stamler C, Mills J. Pyogenic psoas abscesses: noninvasive diagnostic techniques and review of the literature. *Rev Infect Dis* 1983;5:1003-11. [CrossRef](#)
5. Dauchy FA, Dupon M, Dutronc H, de Barbeyrac B, Lawson-Ayayi S, Dubuisson V, et al. Association between psoas abscess and prosthetic hip infection: a case-control study. *Acta Orthop* 2009;80:198-200. [CrossRef](#)
6. Buttaro M, González Della Valle A, Piccaluga F. Psoas abscess associated with infected total hip arthroplasty. *J Arthroplasty* 2002;17:230-4. [CrossRef](#)
7. Song J, Letts M, Monson R. Differentiation of psoas muscle abscess from septic arthritis of the hip in children. *Clin Orthop Relat Res* 2001;391:258-65. [CrossRef](#)