



Tuberculosis tenosynovitis of the flexor tendons in the wrist: a case report

Michel N'guessan ANOUMOU¹, Maurice KOUAME¹, Thomas DAIK², Armand YEPIE¹

¹Department of Orthopedics and Traumatology, University Hospital of Treichville, Abidjan, Côte d'Ivoire;

²Department of Pneumophthysiology, University Hospital of Treichville, Abidjan, Côte d'Ivoire

Extra-pulmonary tuberculosis is a rare form of tuberculosis that can pose diagnostic and therapeutic challenges. We report a case of extra-articular tuberculosis tenosynovitis in a 45-year immunocompetent patient. The symptoms of the patient mimicked De Quervain's disease and carpal tunnel syndrome. Following pathological confirmation of the diagnosis, the patient recovered following a six-month antitubercular chemotherapy.

Key words: Tenosynovitis; mycobacterium tuberculosis; flexor tendons; wrist.

Tuberculosis is an endemic disease in tropical regions, and its outbreak is related to many promoting factors, such as immunosuppression due to HIV infection. In 2007, the World Health Organization (WHO) reported the incidence of the tuberculosis as 206/100000 inhabitants per year, with 9.3 million new cases per year.^[1] While extra-pulmonary form of the tuberculosis is rare, the involvement of the tendon sheaths is more unusual.^[2] Flexor tendons are more commonly involved than the extensor tendons.^[3] We report a case of extra-articular tuberculosis tenosynovitis in an immunocompetent patient.

Case report

A 45-year old woman presented with a painful swelling on the anterior aspect of her left wrist in October 2009. This tumefaction had been gradually developed in the last few months and the patient had not benefited from six consecutive betamethasone injections. On physical examination, there was edema, inflammation and paresthesia on the affected area. There was a flexion con-

tracture in the last four fingers and a thumb movement was painful. Finkelstein test and Tinel's sign were positive. X-rays of the wrist did not reveal any abnormality. However, sonographic examination revealed a heterogeneous hypoechogenic lesion in both the palmar side of the wrist and the hand suggesting a phlegmon. The magnetic resonance imaging showed increased intensity around the flexor tendons suggesting inflammatory infiltration (Fig. 1). The C Reactive Protein was within normal limits and erythrocyte sedimentation rate was high at the first and second hour. The tuberculin skin test was normal and the chest x-ray did not show any parenchyma lesion. The HIV test was negative. An open surgical biopsy was performed. During surgery, there was a fusiform inflammatory swelling around the flexor tendons, without phlegmon formation. There was also swelling on the median nerve (Fig. 2).

The swollen inflammatory tissue was removed for bacteriological and histological examination. Also transverse carpal ligament was released. Histological exami-

Correspondence: Michel N'guessan Anoumou, MD. Department of Orthopedics and Traumatology, University Hospital of Treichville, Abidjan, Côte d'Ivoire.

Tel: +225 21249122 e-mail: anoumoumichel@yahoo.com

Submitted: January 23, 2013 **Accepted:** May 14, 2013

©2014 Turkish Association of Orthopaedics and Traumatology

Available online at
www.aott.org.tr
doi: 10.3944/AOTT.2014.3168
QR (Quick Response) Code



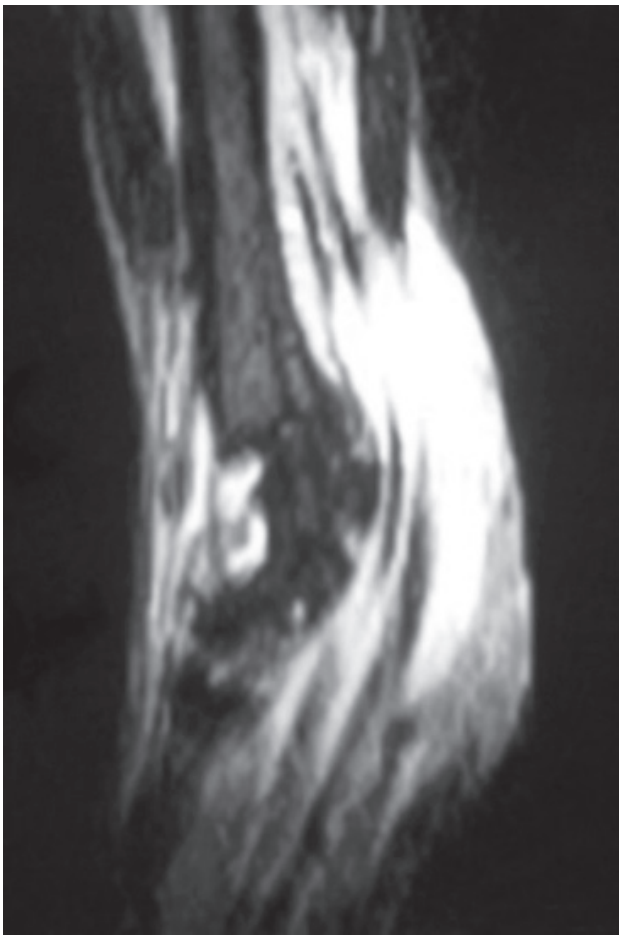


Fig. 1. The magnetic resonance imaging showed increased intensity around the flexor tendons suggesting inflammatory infiltration.

nation revealed epithelioid granulomas and giant cells with central caseous necrosis confirming the diagnosis of tuberculosis (Fig. 3). Bacteriological cultures remained sterile. The patient had a 6-month anti-tubercular treatment consisting of rifampicin, isoniazid, pyrazinamide, and ethambutol (ETM) for the first two months followed by a combination of rifampicin and isoniazid for the last 4 months. There was no side effect except paresthesia on the median nerve sensory area, which disappeared later. At the last follow-up, the patient reached her old activity level with normal hand functions.

Discussion

The infection of the tendinous sheath by the mycobacterium tuberculosis is a rare form of the extra-pulmonary tuberculosis. This infection of the tendinous sheath frequently occurs on the wrist, the hand, the foot and the ankle. The tuberculous tenosynovitis represents for less than 5% of the cases with musculoskeletal involvement.^[4,5] The diagnosis of the tuberculous tenosynovitis may

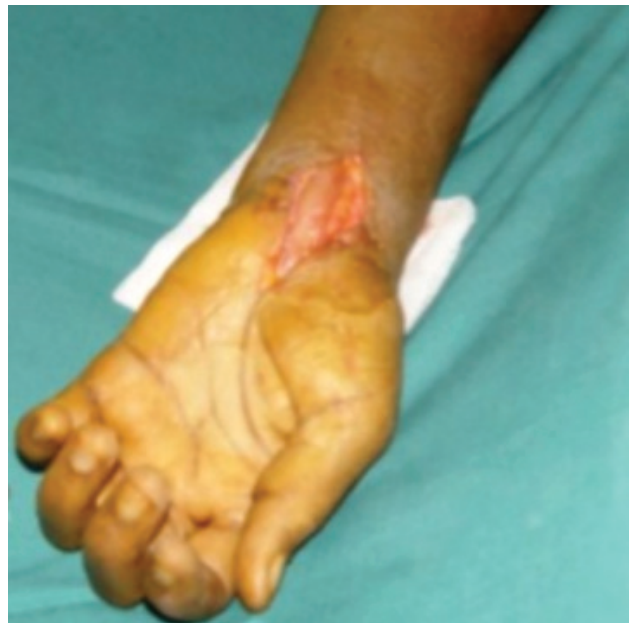

Fig. 2. During surgery there was a fusiform inflammatory swelling around the flexor tendons, without phlegmon formation. There was also swelling on the median nerve. [Color figure can be viewed in the online issue, which is available at www.aott.org.tr]

be either difficult or delayed due to its non specific symptoms as well as its insidious onset.^[6] The inflammatory tenosynovitis around the carpal tunnel may compress the median nerve, mimicking the symptoms of canal carpal syndrome due to a mechanical cause.^[7,8] Lee reported that carpal tunnel syndrome is frequent in tuberculous tenosynovitis of the flexor tendons in the wrist.^[7]

Wallach and Masmejean stated that the tuberculosis is an important infectious etiology for secondary carpal

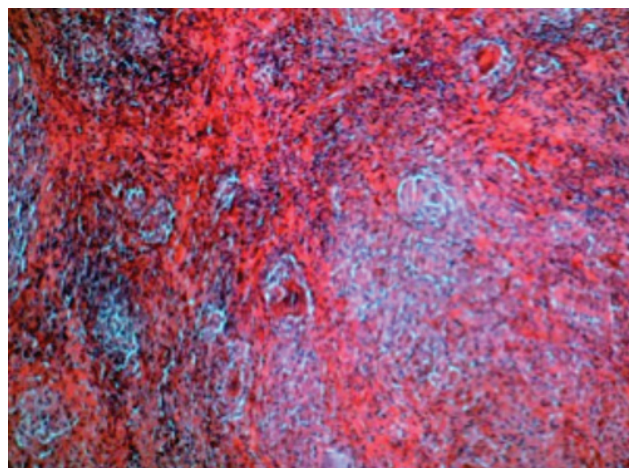


Fig. 3. Histological examination revealed epithelioid granulomas and giant cells with central caseous necrosis confirming the diagnosis of tuberculosis. [Color figure can be viewed in the online issue, which is available at www.aott.org.tr]

tunnel syndrome.^[9] Chen and Eng reported that tuberculous tenosynovitis may also mimic De Quervain's tenosynovitis.^[10] Kang et al., in their systematic histological analysis of the space occupying lesions in the carpal tunnel, reported a high incidence of 25% for tuberculous lesions.^[11] Therefore, the incidental finding may be supposed to be the most common presentation for tuberculous tenosynovitis. The infection of the tendon sheath may result from the hematogenous dissemination of the bacillus.^[12] However, direct inoculation of the tendon sheath by the Koch bacillus were also reported.^[13]

In our case, repeated corticosteroid injections were performed before his initial presentation. Laulan et al. reported the role of local steroid injections on nonspecific fibrous tenosynovitis, whereas the key role of the local corticoid injections in joints and tissues is still unknown.^[14] However the possibility of a tuberculous tenosynovitis should be considered before performing a steroid injection.^[15] In our case while the physical examination and chest x-ray were normal, but the sonographic examination revealed significant findings suggesting the disease.

The wrist x-ray may not show any abnormality, except chronic cases with sequel. The magnetic resonance imaging usually confirms the chronic tenosynovitis, but not the specific origin of the disease. It also helps to plan surgical strategies for treatment.^[15] Magnetic Resonance is essential for a complete examination of the whole tendon, exploring any tendon lesion or joint involvement. The definitive diagnosis of the tuberculosis unavoidably depends on histopathological analysis of the tissue sampling showing epithelioid granulomas and giant cells with central caseous necrosis. Kanavel reported three stages in tendinous tuberculosis.^[13] Stage I is characterized by the presence of a serous exudation with thickening of tendon sheaths, followed by stage II, the proliferative stage with granuloma tissues made of "seed of rice" aspects, and the stage III is characterized by the presence of massive necrosis. Our case was characterized by the increase in the tendon thickness and serous exudation, corresponding to stage I of Kanavel.

The treatment of the tuberculous tenosynovitis is typically medical based on standard protocols, which should be performed in specialized health centers under regular monitoring conditions because of the potential side effects of the chemotherapy.

Primary surgical treatment should be recommended only in stage II lesions and tendon tears. Similarly, Benchakroum et al. believe that surgery should be performed not only in case of complications (i.e. abscesses, neurological complications) but also when the medical treatment fails.^[6] After the surgical treatment, functional

rehabilitation should be introduced as soon as the histological proof and the cicatrization were obtained. The functional rehabilitation allowed our patient to recover completely with full wrist and hand function.

Conflicts of Interest: No conflicts declared.

References

1. World Health Organization. Global tuberculosis control-epidemiology, strategy, financing. WHO report 2009 (WHO/HTM/TB/2009(p.411)).
2. Gester. Affections des gaines synoviales. *Encycl.Med. Chir.*1987 Appareil locomoteur, 15153 A10,9:8.
3. De Vuyst D, Vanhoenacker F, Gielen J, Bernaerts A, De Schepper AM. Imaging features of musculoskeletal tuberculosis. *Eur Radiol* 2003;13:1809-19. [CrossRef](#)
4. Fnini S, Ouarab M, Rafai M, Cohen D, Largab A, Trafefh M. An uncommon occupational accident: tuberculous tenosynovitis of the extensor tendons of the hand. [Article in French] *Chir Main* 1999;18:309-12. [Abstract]
5. Dumontier C, Maylin V, Sautet A, Lenoble E, Urban T, Apoil A. Rupture of the flexor tendon of the hand caused by tuberculosis. [Article in French] *Rev Chir Orthop Reparatrice Appar Mot* 1996;82:668-71. [Abstract]
6. Benchakroum M, El Bardouni A, Zaddoug O, Kharmaz M, El Yaacoubi M, Ouadghiri M, et al. Tuberculosis of the wrist. Symptoms and outcome in eleven cases. [Article in French] *Rev Chir Orthop Reparatrice Appar Mot* 2004;90:337-45. [Abstract] [CrossRef](#)
7. Lee KE. Tuberculosis presenting as carpal tunnel syndrome. *J Hand Surg (Am)* 1998;13:574-6.
8. Kang HJ, Park SY, Shin SJ, Kang ES, Hahn SB. Tuberculous tenosynovitis presenting as carpal tunnel syndrome. *J Korean Soc Surg Hand* 2009;5:137-41.
9. Wallach F, Mamejean E. Carpal tunnel syndrome. When to operate? *La revue du praticien-medicine générale* 2006;20:716-7.
10. Chen WS, Eng HL. Tuberculous tenosynovitis of the wrist mimicking de Quervain's disease. *J Rheumatol* 1994;21:763-5.
11. Kang HJ, Jung SH, Yoon HK, Hahn SB, Kim SJ. Carpal tunnel syndrome caused by space occupying lesions. *Yonsei Med J* 2009;50:257-61. [CrossRef](#)
12. Latil F, Magalon G, Dreant J, Roffe JL, Decaillet JM, Bureau H. Current aspects of tuberculous tenosynovitis. A report of six cases. [Article in English, French] *Ann Chir Main* 1982;1:336-41. [Abstract] [CrossRef](#)
13. Kanavel AB. Tuberculosis tenosynovitis of the hand: A report of fourteen cases of tuberculosis tenosynovitis. *Surg Gynecol Obstet* 1923;37:635-47.
14. Laulan J, Jeannou J, Goupille P. Tendinitis of the hand and the wrist. *Rev Rheum* 2001;68:497-504. [CrossRef](#)
15. Pertuiset E. Tuberculis of bone and joint members. *EMC-Rheumatologie Orthopédie* 2004;463-86.