



Long-term follow-up of long and flat bone eosinophilic granulomas managed only with biopsy

Bülent EROL¹, Ömer SOFULU¹, Mert Osman TOPKAR¹, Emrah ÇALIŞKAN¹, Hüseyin Kemal TÜRKÖZ²

¹Marmara University, Pendik Training and Research Hospital, Department of Orthopaedics and Traumatology, İstanbul, Turkey;

²Marmara University, Pendik Training and Research Hospital, Department of Pathology, İstanbul, Turkey

Objective: We evaluated long-term clinical and radiological follow-up results of patients with long and flat bone eosinophilic granulomas managed only with biopsy.

Methods: Seventeen patients [11 male, 6 female; average age 8.5 years (range: 3.5 to 14 years)] with long and flat bone eosinophilic granulomas were followed after biopsy. Involved bones were femur (5), tibia (3), humerus (2), ulna (1), pelvis (3), scapula (1) and clavicle (1). After confirmation of diagnosis by biopsy, no further surgical intervention was performed. Clinical follow-up was done with preoperative and postoperative MSTS and VAS scores. The healing process was followed with periodic radiographs. Limb-length discrepancy, deformity, and lesion progression or recurrence were recorded. Average follow-up was 65 months (range: 28 to 115 months).

Results: Average preoperative MSTS score was 45% (range: 30 to 56.6%), while postoperative 6, 12 and 24 months scores were measured as 76% (range: 70 to 83.3%), 88% (range: 73.3 to 93.3%) and 94% (range: 86.6 to 100%) respectively. Average VAS score, which was 8.4 (range: 6 to 10) preoperatively, had a tendency to decrease postoperatively, and was measured as 3.5 (range: 2 to 5), 2.2 (range: 1 to 3.5) and 1.1 (range: 0 to 2) at 3, 6, and 12 months. Even though the majority of lesions demonstrated complete radiographic healing at 12 months, the healing process extended to 24 months for flat bones. No patients experienced limb-length discrepancy or deformity. All lesions regressed following biopsy and no recurrence was seen.

Conclusion: Eosinophilic granuloma has a spontaneous healing potential, and confirming the diagnosis by biopsy is sufficient to obtain good functional and radiological results without any further intervention.

Keywords: Eosinophilic granuloma; langerhans cell histiocytosis.

Langerhans cell histiocytosis (LCH) is a rare childhood disease characterized by accumulation of histiocytes in various tissues of the body, but most commonly in the skeleton, skin, and lymph nodes. It has been described as including three conditions: eosinophilic granuloma, Hand-Schüller-Christian disease and Letterer-Siwe dis-

ease. While the etiology of the disease remains unclear, theories have included a disorder of immune regulation and a neoplastic process. The role of viruses in initiating this disease remains under study.^[1]

Skeletal manifestations of eosinophilic granuloma most often involve the flat bones, with more than 50%

Correspondence: Ömer Sofulu, MD. Marmara Üniversitesi Pendik Eğitim ve Araştırma Hastanesi, Ortopedi ve Travmatoloji Kliniği, İstanbul, Turkey.

Tel: +90 216 – 625 45 45 / 7521 e-mail: omersofulu@hotmail.com

Submitted: March 26, 2014 **Accepted:** August 01, 2014

©2015 Turkish Association of Orthopaedics and Traumatology

Available online at
www.aott.org.tr

doi: 10.3944/AOTT.2015.14.0116

QR (Quick Response) Code



found in the skull, spine, mandibula, ribs, and pelvis.^[2,3] Long bone involvement usually is limited to the diaphysis and metaphysis of the femur, tibia, and humerus. The disease is usually monostotic, but polyostotic involvement has been reported in 10% of patients.^[4] Radiological findings of eosinophilic granuloma are highly variable and may mimic primary bone tumors or bone infections. Due to extensive marrow involvement and soft tissue abnormalities on magnetic resonance (MR) imaging, lesions may frequently be confused with malignant bone tumors.

The clinical course of patients with eosinophilic granuloma is generally benign. Osseous lesions usually do not require treatment other than biopsy to confirm diagnosis. Additional local therapy may be considered only for painful lesions, lesions in weight-bearing bones with a risk of pathological fracture, or lesions that could result in unacceptable dysfunction or deformity. In this retrospective study, long-term clinical and radiological follow-up results of 17 patients with long and flat bone eosinophilic granulomas were evaluated. The patients were managed with biopsy to confirm diagnosis, and none required an additional intervention during follow-up.

Patients and methods

Between 2003 and 2012, 17 patients who had an eosinophilic granuloma of a long or flat bone were treated in the

authors' hospital. All children had a solitary bone lesion. There were 11 boys and 6 girls with an average age of 8.5 years (range: 3.5 to 14 years). The average follow-up was 65 months (range: 28 to 115 months). None of the patients underwent an additional procedure other than a biopsy (15 closed, 2 open), which was performed under general anesthesia. The patients were followed clinically and radiologically. Clinical evaluation included extremity function scoring of the Musculoskeletal Tumor Society (MSTS) and Visual Analogue Scale (VAS). Data was obtained from our extensive orthopaedic oncology files, which include clinical and radiological evaluations at presentation and during follow-up, and operative and pathology reports. In addition, face-to-face conversations or telephone calls were made with the patients and/or relatives, when required.

The imaging studies, including conventional radiography, MR imaging and Tc-99 MDP whole-body bone scintigraphy, were done prior to biopsy. MR imaging demonstrated the intra- and extra-osseous extensions of the lesions. Bone scintigraphy and radiographic bone survey confirmed solitary involvement in all patients. The lesions were located in long (12 patients; 71%) and flat (5 patients; 29%) bones (Table 1).

Localized pain was the most common complaint, present in all patients. The children with lower extremity and pelvic involvement frequently had mild to mod-

Table 1. Demographic data and preoperative and postoperative MSTS and VAS scores of the patients.

No	Age	Gender	Localization	MSTS scores		VAS scores	
				Preoperative (%)	Postoperative (24. months)	Preoperative (%)	Postoperative (12. month)
1	9	Male	Ulna	53.3	100	6	0
2	9	Male	Tibia	40	90	10	2
3	7	Male	Femur	36.6	86.6	10	2
4	11	Male	Pelvis	43.3	96.6	9	1
5	14	Male	Femur	33.3	86.6	10	2
6	12	Male	Femur	43.3	90	9	2
7	9	Male	Pelvis	50	100	8	1
8	5	Female	Scapula	46.6	96.6	9	1
9	12	Female	Humerus	56.6	100	6	0
10	11	Female	Tibia	30	86.6	10	2
11	4	Male	Clavicle	53.3	100	7	0
12	3.5	Male	Femur	56.6	96.6	6	0
13	4	Female	Pelvis	50	96.6	8	1
14	11	Male	Fibula	46.6	90	9	1
15	7	Female	Tibia	40	93.3	9	2
16	7	Male	Femur	33.3	90	10	2
17	9	Female	Humerus	53.3	100	7	0
Average	8.5	-	-	45	94	8.4	1.1

erate limping or inability to walk. The upper extremity and shoulder girdle lesions were associated with limited motion of the affected arm. Complete blood count, liver function tests and coagulation tests were obtained pre-operatively in order to reveal the systemic spread of the disease. None of the patients in this series had constitutional symptoms such as fever, leukocytosis or increased sedimentation rate. One patient with a proximal femoral lesion had a nondisplaced pathological fracture, which was followed in spica cast for 6 weeks.

The radiographic appearance was highly variable (Fig. 1a-d, Fig. 2a-c). Ten patients with long bone involvement had radiolucent lesions with well-defined margins without sclerosis. These lesions demonstrated geographic type of destruction. The remaining 7 patients had poorly-defined lesions with permeative destruction. Endosteal

scalloping of the cortex was associated with all long and flat bone lesions. Cortical destruction was observed in 2 patients with pelvic and clavicle eosinophilic granulomas. A slightly thickened continuous periosteal reaction (sometimes lamellar type) was associated with long bone lesions in 5 patients. Based on radiographic examination, the lesions were categorized as Enneking Stage 1-latent (8 patients), Stage 2-active (6 patients), and Stage 3-aggressive (3 patients) benign bone tumors.^[5]

MR imaging demonstrated extensive bone marrow and soft-tissue involvement in the majority of patients. The lesions were hypo- or isointense on T1-weighted images and hyperintense on T2-weighted images. MR images showed cortical destruction and extra-compartmental extension in 3 cases. A diffuse edema in the medullary canal and around the bone was associated with all lesions.

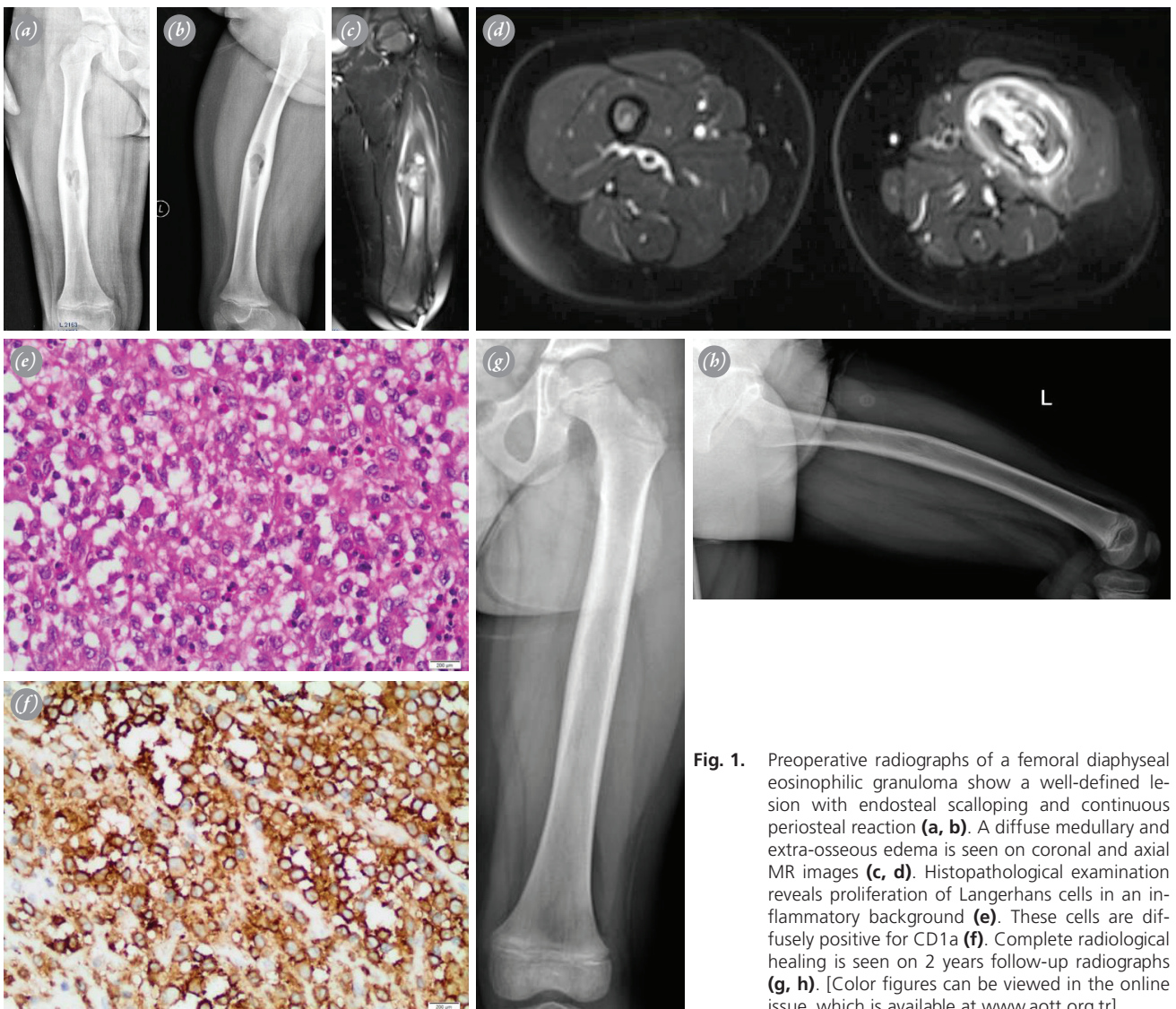

Fig. 1. Preoperative radiographs of a femoral diaphyseal eosinophilic granuloma show a well-defined lesion with endosteal scalloping and continuous periosteal reaction (**a, b**). A diffuse medullary and extra-osseous edema is seen on coronal and axial MR images (**c, d**). Histopathological examination reveals proliferation of Langerhans cells in an inflammatory background (**e**). These cells are diffusely positive for CD1a (**f**). Complete radiological healing is seen on 2 years follow-up radiographs (**g, h**). [Color figures can be viewed in the online issue, which is available at www.aott.org.tr]

The diagnosis of Langerhans cell histiocytosis/eosinophilic granuloma was confirmed histologically in all patients. Microscopic examination revealed proliferation of Langerhans cells in an inflammatory background (Fig. 1e-f). Tumor cells had moderate amounts of eosinophilic cytoplasm and nuclear features of deep clefts and coffee bean-like longitudinal grooves. Immunohistochemical phenotyping showed that Langerhans cells reacted positively for CD1a.

Early motion of the involved extremity and toe touch weight-bearing with crutches were started immediately after lower extremity and pelvic bone biopsies. The patients were allowed to mobilize with a single crutch at 4 weeks, and without any support at 8 weeks. Physical therapy was initiated following fracture healing in 1 patient with pathological femur fracture, and a similar protocol was followed. A sling was used for 4 to 6 weeks following biopsy of the upper extremity and shoulder girdle lesions. Shoulder, elbow, wrist and finger motion was started when tolerated and gradually increased.

After diagnosis was confirmed by biopsy, the patients

were followed clinically and radiologically at 3-month intervals in the first year, 6-month intervals in the second year, and then annually. Functional evaluation was done with MSTS scoring;^[6] preoperative, and postoperative 6- 12- and 24-month MSTS scores were measured for both upper and lower extremities. In addition, preoperative, and postoperative 3- 6- and 12-month VAS scores [between 0 to 10; 0 (no pain), 10 (severe pain)] were recorded. Radiological healing was demonstrated by conventional radiographs taken at periodic follow-ups.

Surgical complications of the biopsy procedure were researched. Complications including limping, limb-length discrepancy, deformity, and progression or recurrence of the lesions were recorded. The Wilcoxon test was used for statistical analysis; difference between preoperative and postoperative MSTS and VAS scores, measured at certain time intervals, were analyzed. A p value <0.05 was considered significant.

Results

Preoperative and postoperative MSTS and VAS scores

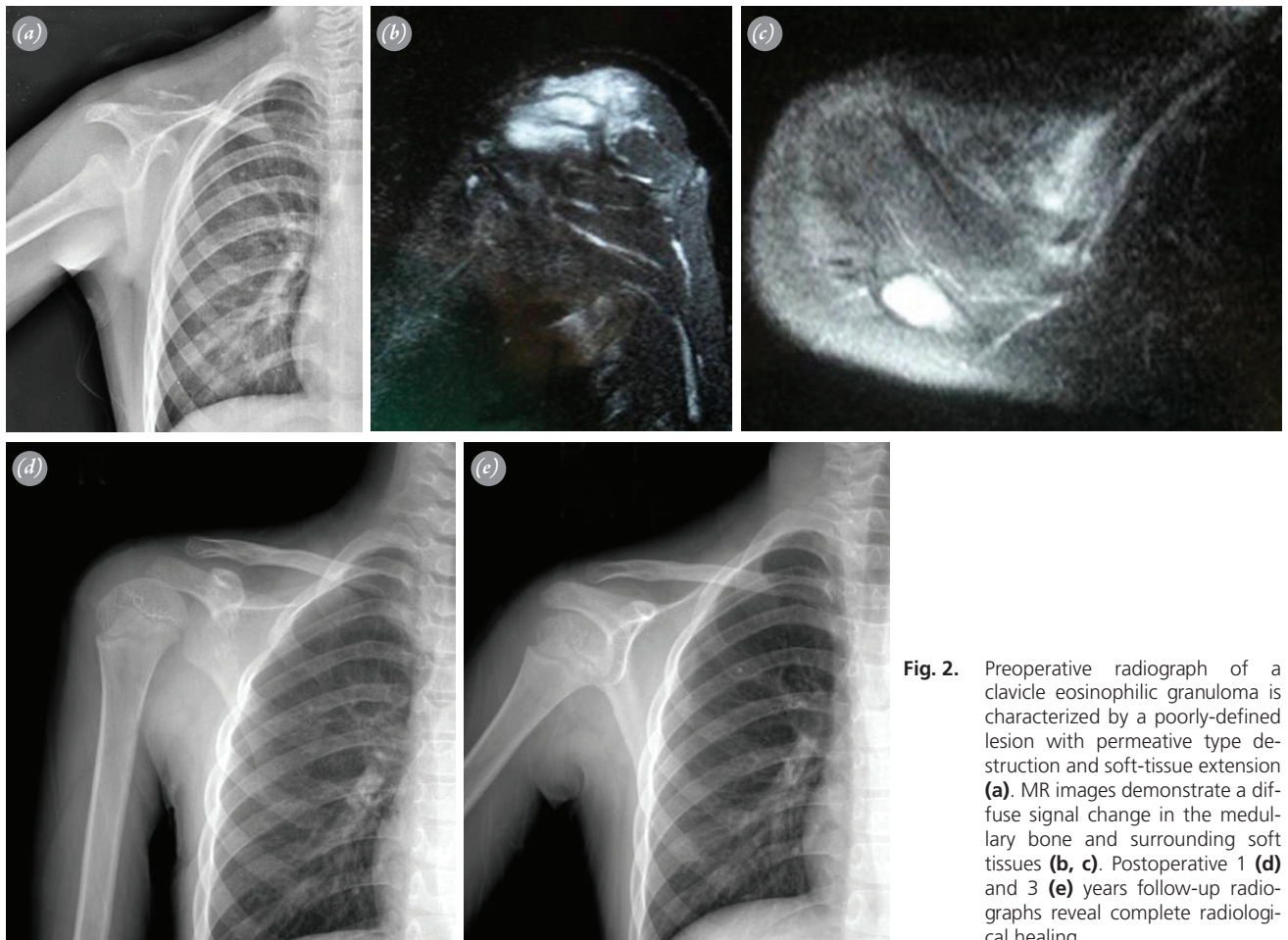


Fig. 2. Preoperative radiograph of a clavicle eosinophilic granuloma is characterized by a poorly-defined lesion with permeative type destruction and soft-tissue extension **(a)**. MR images demonstrate a diffuse signal change in the medullary bone and surrounding soft tissues **(b, c)**. Postoperative 1 **(d)** and 3 **(e)** years follow-up radiographs reveal complete radiological healing.

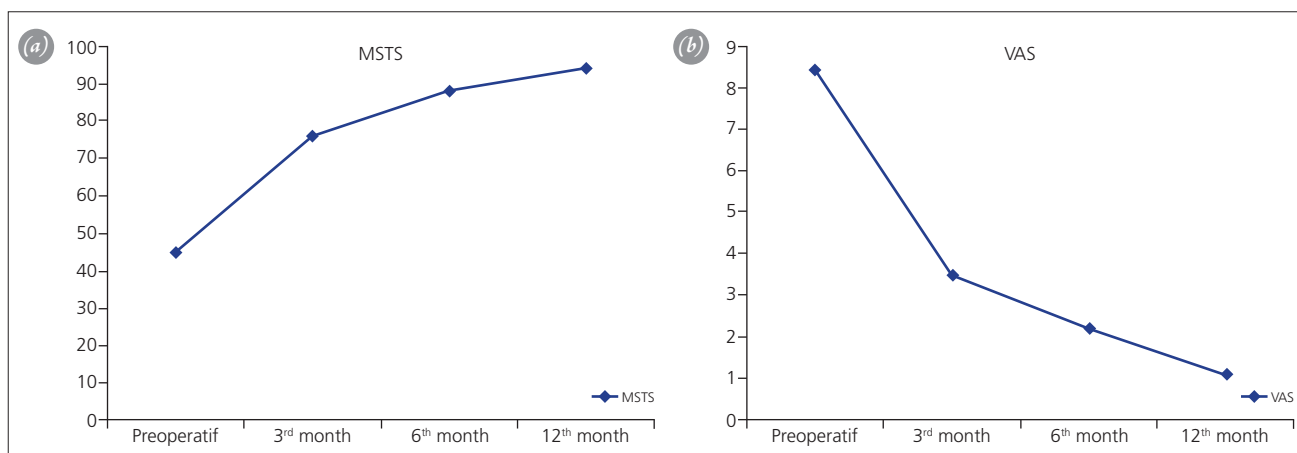


Fig. 3. Graphics showing preoperative and postoperative MSTS (a) and VAS (b) scores of the patients. [Color figure can be viewed in the online issue, which is available at www.aott.org.tr]

are summarized in Table 1. The average preoperative MSTS score was 45% (range: 30 to 56.6%). Postoperatively, MSTS scores increased progressively, with 6-12- and 24-month follow-up scores measured as 76% (range: 70 to 83.3%), 88% (range: 73.3 to 93.3%) and 94% (range: 86.6 to 100%) respectively. The increments in MSTS scores between preoperative and postoperative 6 months, and postoperative 6 and 12 months were statistically significant ($p < 0.05$ for both time intervals). The difference between 12 and 24 months MSTS scores was insignificant ($p > 0.05$) (Fig. 3a).

Localized pain, present in all patients preoperatively, started to regress 1 month after operation. The average VAS score, which was 8.4 (range: 6 to 10) preoperatively, decreased postoperatively, and was measured as 3.5 (range: 2 to 5), 2.2 (range: 1 to 3.5) and 1.1 (range: 0 to 2) at 3, 6 and 12 months respectively. A statistically significant decrease ($p < 0.05$) was detected between the preoperative and postoperative 3-month scores (Fig. 3b). Even though decreased VAS scores were obtained at subsequent periodic follow-ups (6 and 12 months), the difference was not significant statistically ($p > 0.05$).

Radiolucent areas of lesions with geographic or permeative destruction started to be replaced by normal bone at 6 months. At 12 months, complete radiological recovery was achieved in patients with long bone involvement. Radiological healing of flat bone lesions continued until the end of 24 months (Fig. 1g, h, Fig. 2d, e).

None of the patients had a complication due to biopsy procedure. Limping, limb-length discrepancy or deformation was not observed at 6, 12, 24 months and final follow-up visits. Follow-up radiographs did not reveal progression of the lesion or recurrence in any patient.

Discussion

Langerhans cell histiocytosis is a syndrome complex with an unknown etiology.^[7] The two main prognostic factors for the disease are age of patient at time of diagnosis and extent of organ involvement.^[8] Extent of organ involvement and local damage determine whether the disease is treated by surgical or conservative means.^[9,10] Management by conservative methods is associated with fewer complications compared to surgical interventions.

Eosinophilic granuloma lesions have varied and non-specific radiographic appearances; hence, the term, 'the great imitator'.^[11] The tumor should be included in the differential diagnosis of primary bone tumors and osteomyelitis. In addition, MR imaging is nonspecific initially, and may provide an aggressive appearance. In the radiological differential diagnosis of eosinophilic granuloma, the two main considerations are Ewing's sarcoma and subacute hematogenous osteomyelitis. All these conditions may involve a large metadiaphyseal bone segment in children, and have permeative or moth-eaten type of bone destruction with periosteal reaction. In addition, MR imaging is characterized by diffuse signal change in the medullary bone and surrounding soft tissues. Soft tissue involvement is usually characterized by a diffuse extra-osseous edema in eosinophilic granuloma. This feature distinguishes the tumor from Ewing's sarcoma, which is frequently associated with a large soft-tissue component. The differential diagnosis of eosinophilic granuloma and Ewing's sarcoma, both round cell tumors, and osteomyelitis can be made based on histopathological analysis. Bone lymphoma, another round cell tumor, may present as a destructive lesion in the long bone diaphysis or pelvis, and therefore should be included in the differential diagnosis of eosinophilic granuloma.^[12]

The patients in this series were referred to our hospital with the preliminary diagnosis of a malignant bone tumor or a bone infection. Exaggerated appearance on MR imaging caused the lesions to be confused with bone cancers. Except for rare cases with cortical destruction and soft tissue extension, the lesions remained within the bone compartment and created a diffuse edema around the bone. Even though this extra-osseous edema, instead of a soft-tissue component of bone malignancy, supported the preliminary diagnosis of eosinophilic granuloma, all patients underwent a biopsy to confirm the diagnosis. Microbiologic examination was also performed.

Radiation treatment has been used in the management of selected cases of eosinophilic granuloma. Low-dose radiation may be considered for lesions that have the potential to compromise vital structures such as the optic nerve and spinal cord,^[13] and for painful and progressive lesions with a risk of pathological fracture. However, due to the possibility of inducing a post-radiotherapy sarcoma and physal damage, the role of radiation treatment is limited in children.^[14]

Painful lesions in accessible bones may respond to intralesional steroid injections. Egeler et al.^[15] obtained pain regression within a week following steroid injection in patients with eosinophilic granuloma, but 25% of their cases required repeat injections. The authors also reported osteomyelitis in 2 patients. Capanna et al.^[16] observed localized inflammatory reaction in 2 (18%) of 11 patients who underwent methylprednisolone injection after biopsy. In a series of 66 patients reported by Mavrogenis et al.^[17] clavicle fracture and trochanteric bursitis developed in 2 patients following intralesional methylprednisolone injection. Even though intralesional steroid injection is an alternative for the management of painful lesions, local complications limit its use in this benign lesion which has a spontaneous remission potential.

Curettage and grafting have been used for lesions in weight-bearing bones with a risk of pathological fracture, or lesions that could result in unacceptable dysfunction or deformity.^[7,9,18] Osteosynthesis has also been recommended when required. However, considering the potential morbidity of surgical treatment, conservative measures or simply follow-up seem to be more appropriate for eosinophilic granuloma lesions with spontaneous remission potential.

The effect of chemotherapy is not clear in eosinophilic granuloma. Some authors have recommended chemotherapy for lesions in weight-bearing bones with a large soft tissue component.^[7,9,19] However, while chemotherapy may protect visceral function by preventing rapid progression of the disease, it does not affect the

process of histiocytosis.^[10]

Eosinophilic granuloma generally follows a benign clinical course. Clinical and radiological healing can be achieved by confirming diagnosis by biopsy and observing the patient without any additional treatment.^[2,7] Summeit et al.^[20] reported rapid regression of the disease-related findings after biopsy. The authors also obtained better results with observation compared to surgical treatment, in terms of restoration of vertebral corpus height in patients with spinal involvement. The healing process of osseous lesions may take several years in eosinophilic granuloma. In this series, 17 patients with extra-spinal eosinophilic granulomas were followed for an average of 65 months, and functional and radiological healing were achieved spontaneously after biopsy. None of the patients required additional surgical intervention. Radiological recovery was more rapid in long bones compared to flat bones.

The initial presentation of patients with eosinophilic granuloma may be clinically and radiologically aggressive. It is very common for these patients to be referred to a specialized orthopaedic oncology center with preliminary diagnosis of a bone malignancy. The role of the orthopaedic surgeon in the treatment of eosinophilic granuloma should remain modest because of the frequent tendency towards spontaneous healing.

Conflicts of Interest: No conflicts declared.

References

1. Glotzbecker MP, Carpentieri DF, Dormans JP. Langerhans cell histiocytosis: a primary viral infection of bone? Human herpes virus 6 latent protein detected in lymphocytes from tissue of children. *J Pediatr Orthop* 2004;24:123–9. [CrossRef](#)
2. Erol B, States L, Pawel BR, Tamai J, Dormans JP. Musculoskeletal tumors in children. In: Dormans JP, editor. *Pediatric Orthopaedics and Sports Medicine: The Requisites in Pediatrics*. Philadelphia: Mosby; 2004. p. 299–336.
3. Greenspan A, Remagen W. Round Cell Lesions. In: Greenspan A, Remagen W, editors. *Differential Diagnosis of Tumors and Tumor-Like Lesions of Bones and Joints*. Philadelphia: Lippincott-Raven Publishers; 1998. p. 247–88.
4. Lieberman PH, Jones CR, Steinman RM, Erlandson RA, Smith J, Gee T, et al. Langerhans cell (eosinophilic) granulomatosis. A clinicopathologic study encompassing 50 years. *Am J Surg Pathol* 1996;20:519–52. [CrossRef](#)
5. Enneking WF. A system of staging musculoskeletal neoplasms. *Clin Orthop Relat Res* 1986;204:9–24. [CrossRef](#)
6. Enneking WF, Dunham W, Gebhardt MC, Malawar M, Pritchard DJ. A system for the functional evaluation of reconstructive procedures after surgical treatment of tumors

- of the musculoskeletal system. *Clin Orthop Relat Res* 1993;286:241–6. [CrossRef](#)
7. Velez-Yanguas MC, Warriar RP. Langerhans' cell histiocytosis. *Orthop Clin North Am* 1996;27:615–23.
 8. Lahey ME. Prognostic factors in histiocytosis X. *Am J Pediatr Hematol Oncol* 1981;3:57–60.
 9. Bollini G, Jouve JL, Gentet JC, Jacquemier M, Bouyala JM. Bone lesions in histiocytosis X. *J Pediatr Orthop* 1991;11:469–77. [CrossRef](#)
 10. Sessa S, Sommelet D, Lascombes P, Prévot J. Treatment of Langerhans-cell histiocytosis in children. Experience at the Children's Hospital of Nancy. *J Bone Joint Surg Am* 1994;76:1513–25.
 11. Meyer JS, De Camargo B. The role of radiology in the diagnosis and follow-up of Langerhans cell histiocytosis. *Hematol Oncol Clin North Am* 1998;12:307–26. [CrossRef](#)
 12. Erol B, Segal L, Huff D, States L, Dormans JP. Low back pain in a 13-year-old girl. *Clin Orthop Relat Res* 2003;413:323–31. [CrossRef](#)
 13. Broadbent V, Gardner H. Current therapy for Langerhans cell histiocytosis. *Hematol Oncol Clin North Am* 1998;12:327–38. [CrossRef](#)
 14. Womer RB, Raney RB Jr, D'Angio GJ. Healing rates of treated and untreated bone lesions in histiocytosis X. *Pediatrics* 1985;76:286–8.
 15. Egeler RM, Thompson RC Jr, Voûte PA, Nesbit ME Jr. Intralesional infiltration of corticosteroids in localized Langerhans' cell histiocytosis. *J Pediatr Orthop* 1992;12:811–4.
 16. Capanna R, Springfield DS, Ruggieri P, Biagini R, Picci P, Bacci G, et al. Direct cortisone injection in eosinophilic granuloma of bone: a preliminary report on 11 patients. *J Pediatr Orthop* 1985;5:339–42. [CrossRef](#)
 17. Mavrogenis AF, Abati CN, Bosco G, Ruggieri P. Intralesional methylprednisolone for painful solitary eosinophilic granuloma of the appendicular skeleton in children. *J Pediatr Orthop* 2012;32:416–22. [CrossRef](#)
 18. Komp DM, Born LP. Langerhans cell histiocytosis. In: Moosa AR, Schimpff SC, Robson MC, editors. *Comprehensive textbook of oncology*. 2nd ed. Baltimore: Williams & Wilkins; 1991. p. 1582–6.
 19. Starling KA. Chemotherapy of histiocytosis-X. *Hematol Oncol Clin North Am* 1987;1:119–22.
 20. Sumeet GBA, Dormans JP. Primary Tumors of the Spine in Children: A Review from the Pediatric Musculoskeletal Tumor Program at the Children's Hospital of Philadelphia. *The University of Pennsylvania Orthopaedic J* 2003;16:19–29.