



Spinal gas accumulation causing lumbar discogenic disease: a case report

Giyas AYBERK¹, Mehmet Faik ÖZVEREN², Timur YILDIRIM³

¹Department of Neurosurgery, Atatürk Training and Research Hospital, Ankara, Turkey;

²Department of Neurosurgery, Medical Park Hospital Bahçelievler, Istanbul, Turkey;

³Department of Neurosurgery, Faculty of Medicine, Ordu University, Ordu, Turkey

Vacuum disc phenomenon is seen frequently with degenerative disc disease and is characterized by the collection of gas in the disc space. Although the accumulation of gas within the disc space does not have clinical significance, symptoms may develop when occurring within the spinal canal. We present a 60-year-old female patient with low back and left leg pain occurring for 3 months before admission to our clinic. Straight leg raise test was 50 degrees in the left leg. Magnetic resonance imaging showed a narrowing of the L5-S1 disc space with vacuum disc phenomenon and hypointense cystic mass in T1 and T2-weighted images. The decision for surgery was made and left L5-S1 hemilaminectomy and foraminotomy was performed. The cyst wall was adherent to the root and dura mater and was partially excised. The patient was pain-free on the first postoperative day. In cases of gas accumulation in the spinal canal, discogenic pain may occur. Surgical therapy is still an acceptable method for the treatment of vacuum disc phenomenon and accumulation of gas within the spinal canal.

Key words: Gas accumulation; sciatica; spinal canal; vacuum phenomenon.

Vacuum disc phenomenon is a condition seen frequently with degenerative disc disease and is characterized by the collection of gas in the disc space.^[1,2] It is also known as 'phantom nucleus.'^[3] Accumulation of gas may be either intradiscal or spread into the intraspinal canal. Although the accumulation of gas within the disc space does not have clinical significance, clinical symptoms may be observed when it occurs within the spinal canal.^[1] Gas accumulation in the spinal canal may be trapped in a simple cystic structure or associated with a disc herniation.^[4] Ball-valve type connection may cause an increase in the pressure of gas inside the gas containing disc or cyst in the epidural space.^[1] Typical symptoms include

increased pain when standing and walking.^[5]

We present an unusual case of symptomatic intraspinal gas accumulation associated with vacuum disc phenomenon treated with L5-S1 hemilaminectomy and foraminotomy.

Case report

A 60-year-old female with back and left leg pain for 5 months was admitted to our clinic. The patient had not responded to conservative management with a non-steroidal anti-inflammatory drug and muscle relaxant for 3 weeks. The patient had neurogenic claudication in the left leg. Back and leg pain increased when standing and

Correspondence: Giyas Ayberk, MD. Gökdere Sokak, 3/10, 06550 Y. Ayrancı, Ankara, Turkey.

Tel: +90 505 – 253 82 81 e-mail: giyas67@hotmail.com

Submitted: January 30, 2012 **Accepted:** September 24, 2012

©2015 Turkish Association of Orthopaedics and Traumatology

Available online at

www.aott.org.tr

doi: 10.3944/AOTT.2015.2827

QR (Quick Response) Code



decreased when lying down and leaning forward. The straight leg raise test was 50 degrees on the left leg. Routine laboratory investigations were normal. Direct radiographies showed narrowing of the L5-S1 disc space. In magnetic resonance imaging (MRI), there was a narrowing of the L5-S1 disc space with vacuum disc phenomenon and a hypointense cystic mass on T1 (Figs. 1a and b) and T2-weighted images (Figs. 1c and d). A left L5-S1 laminotomy was performed. The nerve root was pushed posteriorly by the cystic mass. The cyst wall was adherent to the root and dura mater and was released after removal of the gas using a syringe inside the cyst wall. The cyst wall was excised partially from the root and dura mater. The degenerated disc was evacuated and foraminotomy was performed. Pathology of the cyst wall was reported as a simple cyst. The patient was pain-free on the first postoperative day and follow-up MRI revealed the absence of the gas containing cystic mass.

Discussion

Biomechanical insufficiency of the disc tissue leads to a cleft in the disc annulus and the gas around the surrounding tissue accumulates in this cleft due to its negative pressure.^[4] Gas in the disc space may spread into the vertebrae by way of the subchondral bone or into the spinal canal.^[1] While the incidence of the vacuum disc phenomenon is around 1 to 20% as detected on direct radiography, this rate increases to 25 to 46% with computed tomography (CT).^[5,6] Although CT is the most reliable diagnostic tool for displaying the gas accumulation in the lumbar spine, Berns et al.^[7] claimed that a gradient echo sequence MRI is as sensitive as CT. The MRI of our patient revealed vacuum disc phenomenon

at the L5-S1 disc level and a gas-filled cystic mass which was hypointense on T1 and T2-weighted images related to the L5-S1 disc space. While a vacuum disc phenomenon in a herniated disc is surrounded by a soft tissue mass with an irregular outline, a gas-filled cyst in the epidural space is distinguished by its regular outline.^[4] The cystic mass in our patient was regular in appearance, and the pathology report did not reveal any disc tissue.

Gas-containing disc herniation occurs by two mechanisms; herniation of a gas-containing disc or the spreading of gas into the disc tissue by the ball-valve mechanism.^[8] Intraspinal gas accumulation reported cases has been associated with the intradiscal vacuum phenomenon,^[1,2] indicating the relationship between the disc space and intraspinal canal gas accumulation. If the fibrous ring of the disc tears, the gas inside the disc moves towards the epidural space. The motion of the vertebrae may cause pressure between the disc and epidural space, provoking the movement of the gas inside the disc toward the epidural space. The symptoms in our case increased during walking and in extension but decreased in flexion and when leaning forward. This points out to the effect of the ball-valve mechanism in the occurrence of symptoms. Trauma, infection, neoplasm, osteonecrosis, spinal injection procedures and spinal surgery are reported as other causes of gas accumulation in the spinal canal.^[4]

The treatment of intraspinal gas accumulation varies from conservative to surgical exploration.^[4] Although spontaneous regression of intraspinal gas accumulation has been reported,^[8] Mortensen et al.^[5] claimed that gas accumulation in the disc space and intraspinal canal cannot be absorbed due to the absence of a vascular network in the surrounding tissue. Therefore, examinations

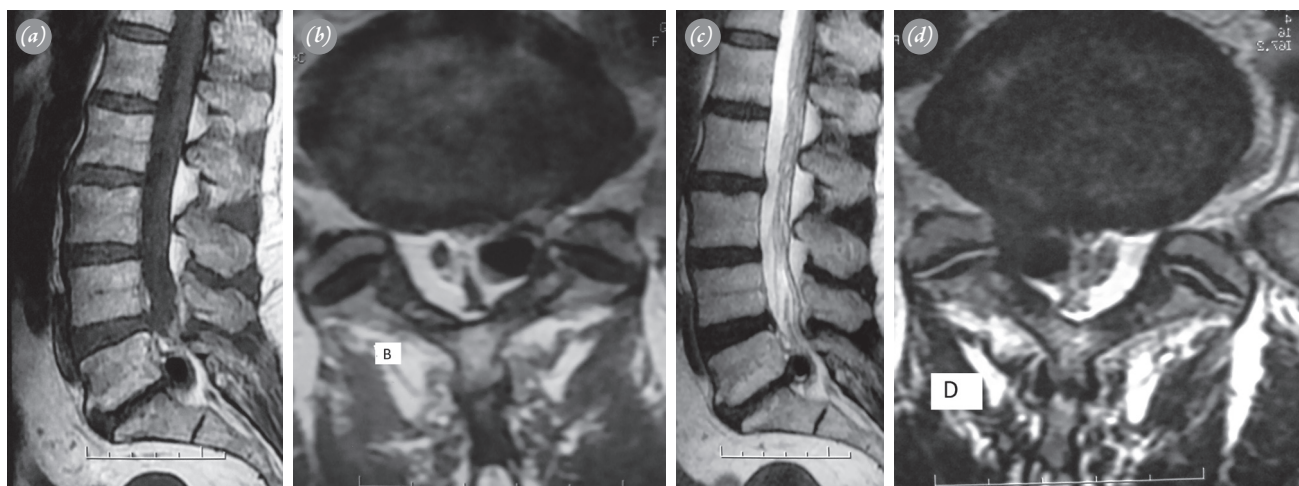


Fig. 1. (a) Sagittal and (b) axial T1-weighted images showing the vacuum disc phenomenon and hypointense cystic mass in the spinal canal. (c) Sagittal and (d) axial T2-weighted images showing the hypointense cystic mass compressing the left L5 root.

must be repeated before any invasive procedure.^[9] While Bosser et al.^[10] proposed needle aspiration under CT guidance, recurrence rates are high.

In conclusion, when the underlying pathophysiologic mechanism is considered, surgery is the best treatment when adequate conservative treatment fails for vacuum disc phenomenon and accumulation of gas within the spinal canal.

Conflicts of Interest: No conflicts declared.

References

1. Tamburrelli F, Leone A, Pitta L. A rare cause of lumbar radiculopathy: spinal gas collection. *J Spinal Disord* 2000;13:451-4. [CrossRef](#)
2. Yoshida H, Shinomiya K, Nakai O, Kurosa Y, Yamaura I. Lumbar nerve root compression caused by lumbar intraspinal gas. Report of three cases. *Spine (Phila Pa 1976)* 1997;22:348-51. [CrossRef](#)
3. Ozgen S, Konya D, Toktas OZ, Dagcinar A, Ozek MM. Lumbar disc herniation in adolescence. *Pediatr Neurosurg* 2007;43:77-81. [CrossRef](#)
4. Kakitsubata Y, Theodorou SJ, Theodorou DJ, Yuko M, Ito Y, Yuki Y, et al. Symptomatic epidural gas cyst associated with discal vacuum phenomenon. *Spine (Phila Pa 1976)* 2009;34:784-9. [CrossRef](#)
5. Mortensen WW, Thorne RP, Donaldson WF 3rd. Symptomatic gas-containing disc herniation. Report of four cases. *Spine (Phila Pa 1976)* 1991;16:190-2. [CrossRef](#)
6. Pierpaolo L, Luciano M, Fabrizio P, Paolo M. Gas-containing lumbar disc herniation. A case report and review of the literature. *Spine (Phila Pa 1976)* 1993;18:2533-6.
7. Berns DH, Ross JS, Kormos D, Modic MT. The spinal vacuum phenomenon: evaluation by gradient echo MR imaging. *J Comput Assist Tomogr* 1991;15:233-6. [CrossRef](#)
8. Coulier B. The spectrum of vacuum phenomenon and gas in spine. *JBR-BTR* 2004;87:9-16.
9. Norman ER, Beall DP, Kitley CA, Ly JQ. Intervertebral disk cyst: a case report. *J Comput Assist Tomogr* 2006;30:313-5. [CrossRef](#)
10. Bosser V, Dietemann JL, Warter JM, Granel de Solignac M, Beaujeux R, Buchheit F. L5 radicular pain related to lumbar extradural gas-containing pseudocyst. Role of CT-guided aspiration. *Neuroradiology* 1990;31:552-3.