



# Recurrent anterior hip dislocation in a patient with myasthenia gravis: a case report

Gökhan ÖZKAZANLI<sup>1</sup>, Özgür KARAMAN<sup>1</sup>, Kubilay BENG<sup>2</sup>, Hasan Hilmi MURATLI<sup>1</sup>

<sup>1</sup>Department of Orthopedics and Traumatology, Fatih Sultan Mehmet Training and Research Hospital, Istanbul, Turkey;

<sup>2</sup>Department of Orthopedics and Traumatology, Metin Sabancı Baltalimanı Bone Diseases Training and Research Hospital, Istanbul, Turkey

Traumatic anterior hip dislocation is a rare condition compared to posterior dislocation and recurrent anterior hip dislocation is encountered even less. Myasthenia gravis is a chronic autoimmune neuromuscular disease characterized by various degrees of muscle weakness. Closed reduction is the first choice of treatment for traumatic, non-recurring hip dislocation. We report a 59-year-old female with myasthenia gravis who underwent surgical intervention for recurrent anterior hip dislocation after failure of closed reduction. To our knowledge, this is the first case with recurrent anterior hip dislocation and myasthenia gravis in the literature.

**Key words:** Closed reduction; myasthenia gravis; recurrent anterior hip dislocation.

Traumatic hip dislocation is an emergency condition with impaired joint integrity and circulation.<sup>[1]</sup> Traumatic anterior hip dislocation is a rare condition and accounts for 9% of overall traumatic dislocations.<sup>[2,3]</sup> The literature concerning treatment methods for recurrent anterior hip dislocation and their outcomes is limited to case reports.<sup>[4-9]</sup>

Myasthenia gravis (MG) is a chronic autoimmune neuromuscular disease with an incidence of 1 in 10000 to 50000 people.<sup>[10]</sup> Autoantibodies against postsynaptic acetylcholine receptors are considered to be responsible for its pathology. The voluntary muscles innervated by brain stem motor nuclei in particular are involved. Studies have reported that diseases like thymoma, diabetes mellitus, thyroid diseases, neoplasms and rheumatoid arthritis may accompany MG.<sup>[10]</sup> This is the first reported case of recurrent anterior hip dislocation in the course of MG.

## Case report

A 59-year-old female patient was diagnosed with MG 36 years prior after presenting with impaired speech, difficulty in swallowing (dysphagia), ptosis and diplopia. She underwent thymus resection surgery for the treatment of MG.

Six years previously, the patient first experienced sudden-onset severe pain and motion restriction in her hip as she turned her body to the right side while her left lower extremity was fixed on the floor and her overall weight was on the left side. She was diagnosed with anterior dislocation in the left hip and treated at the emergency service of another hospital with closed reduction followed by skin traction and hip abduction device.

The patient had no further hip complaint during her follow-up but become unable to walk due to severe pain

**Correspondence:** Gökhan Özkazanlı, MD. Bağdat Caddesi, Sibel Apt., B Blok D:13, Altuntepe, Maltepe, Istanbul, Turkey.

Tel: +90 532 – 403 01 20 e-mail: drgokhan@hotmail.com

**Submitted:** October 02, 2012 **Accepted:** November 28, 2013


©2015 Turkish Association of Orthopaedics and Traumatology

Available online at

www.aott.org.tr

doi: 10.3944/AOTT.2015.3055

QR (Quick Response) Code



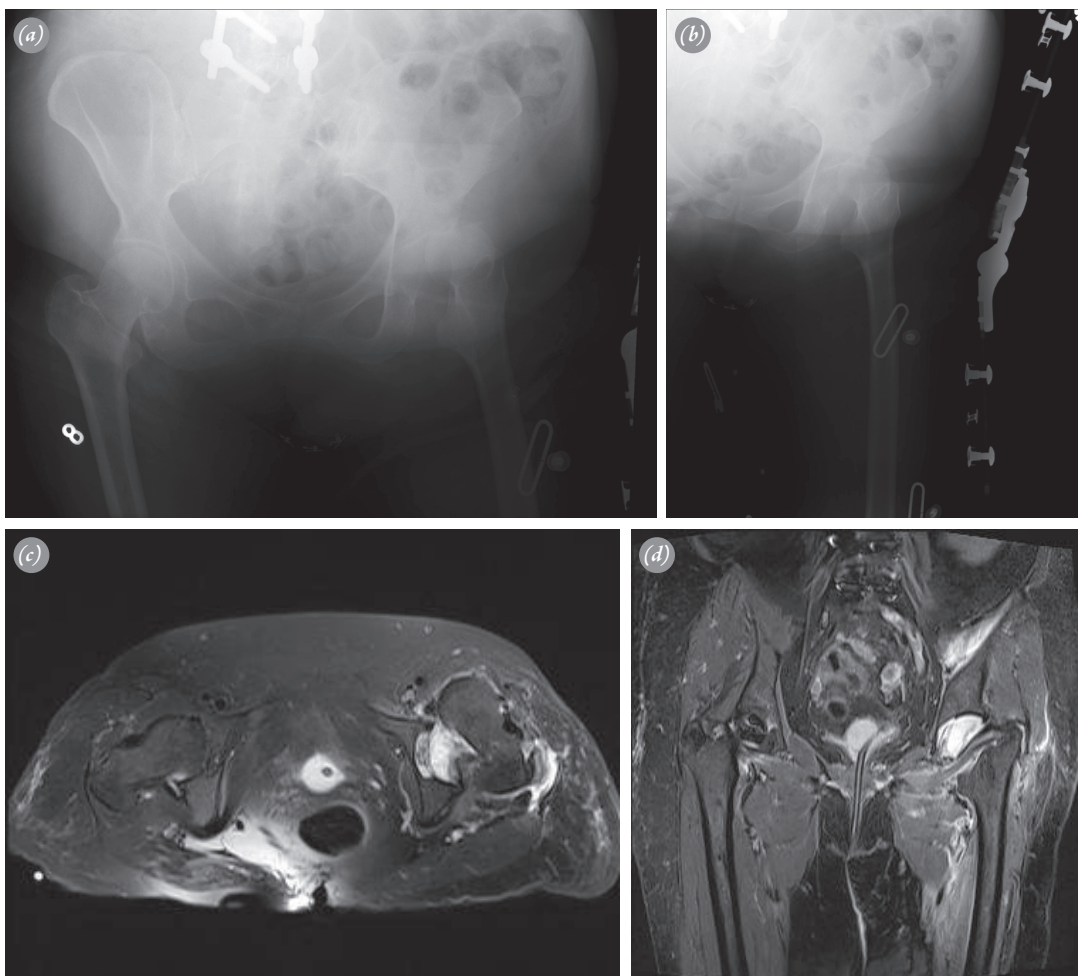
in her left hip caused by abduction and external rotation of the hip joint resulted from twisted left ankle while walking after 4 years. The patient again underwent closed reduction for an anterior dislocation of the left hip. Six week bed rest was recommended. The patient was able to walk first with a walker and then unsupported.

In January 2012, the patient applied to a private hospital due to sudden pain and motion restriction in her left hip while trying to move on a step of a stairway. She underwent closed reduction under general anesthesia and was discharged after staying for a night. Hip dislocation was diagnosed at the follow-up and one week later, closed reduction was reattempted unsuccessfully. The patient was then brought to our emergency service.

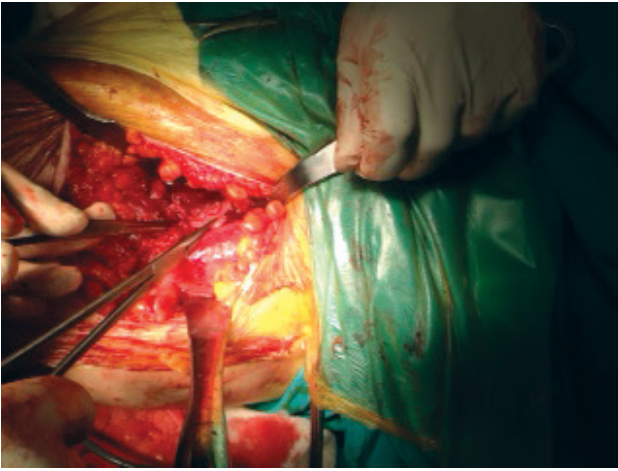
On physical examination, the left lower extremity was in external rotation and shorter than the other extremity. No neurovascular injury was detected. It was learned that the patient had undergone surgical intervention for spondylolisthesis in 2006. Direct radiographic ex-

amination of both hips and magnetic resonance imaging (MRI) were performed (Figs. 1).

Analyses and graphs revealed anterior dislocation of the left hip. On MRI, avulsion fracture was detected in the anterior wall of the acetabulum in addition to anterior hip dislocation. The patient was prepared for surgery under general anesthesia in the supine position. Closed reduction was first tried. However, a concentric and stable reduction could not be achieved and open reduction was then attempted. The left hip was accessed via a Watson-Jones incision from the anterior aspect. The labrum was segregated together with an avulsed bone fragment and the labrum laceration and widened capsule were considered to be the obstacles preventing successful reduction of the hip joint and was repaired using a 5-mm metal suture anchor. However, stability could not be achieved as while the integrity of the joint capsule was provided, it remained loose. The capsule was longitudinally opened, the femoral head reduced and the capsule



**Fig. 1.** Anteroposterior radiograph of (a) both hips and (b) the left hip alone. T2-weighted MR (c) axial and (d) coronal section of both hips showing anterior dislocation of the left hip.



**Fig. 2.** Plication of the joint capsule. [Color figure can be viewed in the online issue, which is available at [www.aott.org.tr](http://www.aott.org.tr)]

was plicated over itself (Fig. 2).

An abduction brace was applied after the surgery. Postoperative examination, radiography (Fig. 3a) and computed tomography (Fig. 3b) demonstrated central

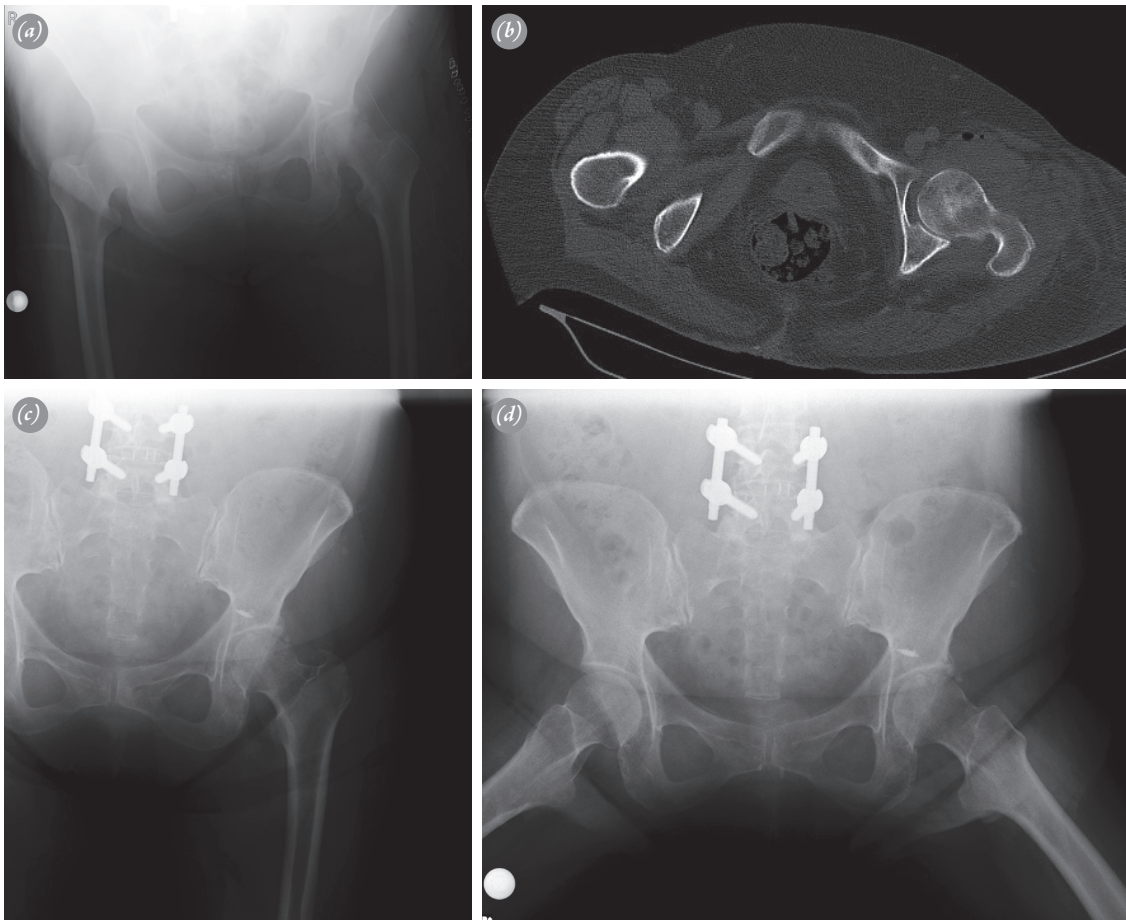
reduction of the hip joint. Supported walking was allowed on the 6<sup>th</sup> week.

The patient was able to walk without support and the brace was removed at the 3<sup>rd</sup> postoperative month. Control radiographs were taken (Figs. 3c and d). Hip flexion was 130°, internal rotation 30°, and external rotation 50°. Harris hip score was 95.

By the 1st year postoperative follow-up, dislocation had not recurred and the patient was able to walk without support. Final hip flexion was 140°, internal rotation was 30° and Harris hip score 95. Flexion of the uninjured side was 140°, internal rotation 40°, and external rotation 50°. The Trendelenburg test was negative in each hip. No difference was detected on comparable muscle strength tests of both hips. Muscle strength was 5/5 for each hip.

### Discussion

The hip joint is quite stable owing to its anatomical structure. Traumatic anterior dislocation is a very rare condition. Of overall hip dislocations, 9% have been



**Fig. 3.** (a) Postoperative anteroposterior radiograph. (b) Postoperative tomography. (c, d) Postoperative 3<sup>rd</sup> month radiographs.

reported to be anterior.<sup>[11]</sup> The number of cases with recurrent hip dislocation reported in the literature is quite limited.<sup>[4-9]</sup> Identification of potential factors for recurrent dislocation may direct the treatment and likely causes of recurrent dislocation, such as acetabular dysplasia, femur head dysplasia, connective tissue diseases and labrum laceration should be investigated.

Data about the treatment of recurrent anterior hip dislocation are limited to case reports. Dall et al. reported a case in which they performed 45° femoral osteotomy together with iliopsoas transfer to the trochanter major.<sup>[5]</sup> Shigenobu et al. performed capsulorrhaphy and acetabular rotational osteotomy in a case with acetabular dysplasia and reported successful outcomes.<sup>[6]</sup> Guyer and Levinsohn detected laceration in the anterior aspect of the capsule on arthrography performed after reduction in a case with recurrent anterior hip dislocation.<sup>[7]</sup> Epstein et al. successfully performed arthroscopic surgery in a case and reported anterior capsular insufficiency as the cause of recurrent dislocation.<sup>[8]</sup> Schweitzer et al. found the joint capsule to be intact but loose and performed open reduction; they obtained successful outcome after capsulorrhaphy and femoral derotational osteotomy.<sup>[9]</sup>

In MG, neuromuscular conduction is inadequate due to motor endplate abnormalities. The prevalence of disease is 1 in 10000 to 50000 people and 90% of the patients are adults.<sup>[10]</sup> Muscle tiredness that improves after resting and variable muscle weaknesses are the characteristics of the disease. Minimal or no atrophy is seen in involved muscles.<sup>[10]</sup> Antibodies against nicotinic acetylcholine receptors found in muscular motor endplate is specific to the disease. Muscle weakness results from recurrent movements that occur due to motor endplate conduction defect and improves with resting. The most common signs are ptosis and diplopia. Post-activity weakness in the lower extremity, particularly in the muscles around the hip joint, is seen in 10% of cases.<sup>[10]</sup> Diagnostic tools include edrophonium test, detection of acetylcholine receptor antibodies, EMG and muscle biopsy. Although there is no exact treatment for the disease, it can be controlled by drug therapy. Periodic resting, activity planning, preparing meals by sitting on a chair in the kitchen and bathing in a sitting position are recommended to fight against activity-related muscle weakness.

Recurrent anterior hip dislocation with MG has not been formerly defined in the literature. Based on the current data, it is not possible to determine if MG leads to hip dislocation. Although Pouwels et al.<sup>[12]</sup> reported no association between an increased risk of fracture and MG; when compared with healthy subjects, we think

that patients with MG might be more exposed to traumas which have the potential to cause hip dislocation because of the increased risk for losing balance, falls and twisting the ankle due to muscle weakness enhanced by activity. The present case experienced her first hip dislocation while preparing a meal in the kitchen in a standing position, the second by twisting her ankle after a long walking and the third after climbing stairs.

In conclusion, we are of the opinion that the risk for dislocation is enhanced in patients with MG as the result of recurrent traumas and falls due to muscle weakness. In the present case, the anterior aspect of the hip joint was macroscopically detected to be loose and required plication and the labrum was segregated together with a small, avulsed fragment. The dislocation was reduced using open reduction methods as previous closed methods were unsuccessful due to the loss of capsular stability.

**Conflicts of Interest:** No conflicts declared.

## References

1. Altay M, Yağmurlu F, Heybeli M, Muratlı HH, Tabak Y, Biçimoğlu A. Simultaneous asymmetric bilateral traumatic hip dislocation: a case report. *Acta Orthop Traumatol Turc* 2003;37:182-6. [Article in Turkish]
2. Azar N, Yalçınkaya M, Akman YE, Uzümçügil O, Kabukçuoğlu YS. Asymmetric bilateral traumatic dislocation of the hip joint: a case report. *Eklemler Hastalıkları Cerrahisi* 2010;21:118-21. [Article in Turkish]
3. Graham B, Lapp RA. Recurrent posttraumatic dislocation of the hip. A report of two cases and review of the literature. *Clin Orthop Relat Res* 1990;256:115-9. [CrossRef](#)
4. Scudese VA. Traumatic anterior hip redislocation. A case report. *Clin Orthop Relat Res* 1972;88:60-3. [CrossRef](#)
5. Dall D, Macnab I, Gross A. Recurrent anterior dislocation of the hip. *J Bone Joint Surg Am* 1970;52:574-6.
6. Shigenobu T, Yasunaga Y, Omoto O, Ikuta Y, Kido K. Recurrent anterior dislocation of the hip joint--a case report. *Acta Orthop Scand* 2000;71:422-4. [CrossRef](#)
7. Guyer B, Levinsohn EM. Recurrent anterior dislocation of the hip: case report with arthrographic findings. *Skeletal Radiol* 1983;10:262-4. [CrossRef](#)
8. Epstein DM, Rose DJ, Philippon MJ. Arthroscopic management of recurrent low-energy anterior hip dislocation in a dancer: a case report and review of literature. *Am J Sports Med* 2010;38:1250-4. [CrossRef](#)
9. Schweitzer D, Breyer JM, Córdova M, Fica G. Recurrent anterior dislocation of the hip. A case report. *J Bone Joint Surg Am* 2004;86-A:581-3.
10. Donald B, Howard S, Howard JF. Disorders of The Neuromuscular Transmission. In: Bradley WG, Darof RB, Fenichel GM, Marsden CV, editors. *Neurology in Clini-*

- cal Practice. Boston: Butterworth Heinemann Company; 2000. p. 2167-85.
11. Thompson VP, Epstein HC. Traumatic dislocation of the hip; a survey of two hundred and four cases covering a period of twenty-one years. *J Bone Joint Surg Am* 1951;33-A:746-78.
  12. Pouwels S, de Boer A, Javaid MK, Hilton-Jones D, Verschuuren J, Cooper C, et al. Fracture rate in patients with myasthenia gravis: the general practice research database. *Osteoporos Int* 2013;24:467-76. [CrossRef](#)