



Anatomical relations between anterior coracoscapular ligament and suprascapular neurovascular structures and a proposal for classification

Ilke Ali GÜRSES, Özcan GAYRETLİ, Osman COŞKUN, Aysin KALE, Adnan ÖZTÜRK

Istanbul University, Istanbul Faculty of Medicine, Department of Anatomy, Istanbul, Turkey

Objective: Although suprascapular nerve entrapment is rare, the most common site of compression is the suprascapular notch. The anterior coracoscapular ligament (ACSL), which lies inferior to the superior transverse scapular ligament (STSL), may also be a cause of entrapment. We aimed to investigate the presence of ACSL and its relations to the suprascapular nerve and vessels.

Methods: We dissected 50 shoulders of 26 cadavers. We excluded 2 shoulders due to previous shoulder surgery. We observed the course of the suprascapular nerve, artery, and vein(s), and examined whether they passed between STSL and ACSL or under ACSL. We classified the anatomical relations between neurovascular structures, STSL, and ACSL. In Type I, the suprascapular nerve passed between STSL and ACSL; in Type IIa, the suprascapular nerve and a single suprascapular vein passed between STSL and ACSL; in Type IIb, a suprascapular vein passed under ACSL and the suprascapular nerve passed between STSL and ACSL; in Type III, the suprascapular artery, vein, and nerve passed between STSL and ACSL.

Results: ACSL was present in 16 shoulders (32%). The suprascapular nerve passed between STSL and ACSL in all cases. We observed Type I, Type IIa, Type IIb, and Type III anatomical relations in 14%, 12%, 2%, and 4% of cases, respectively.

Conclusion: Vascular structures that pass under STSL may cause suprascapular nerve entrapment. Presence of ACSL with vessel(s) passing under it and/or between it and STSL may increase the risk of nerve entrapment.

Keywords: Anterior coracoscapular ligament; nerve entrapments; suprascapular nerve; vascular relations.

The suprascapular nerve is a mixed nerve originating from the upper trunk of the brachial plexus.^[1,2] It provides motor innervation to the supraspinatus and infraspinatus muscles as well as sensory innervation to the glenohumeral and acromioclavicular joints.^[1,2]

Suprascapular nerve entrapment is relatively rare, but it can often be misdiagnosed because it contributes to only 1%–2% of all cases of shoulder pain.^[1,2] Early symptoms are shoulder pain and weakness which are similar

to symptoms of other shoulder pathologies. Supraspinatus or infraspinatus muscle atrophy may accompany if the condition progresses.^[1,2] Rarely, when a cutaneous branch is present, physical examination may reveal numbness over the shoulder.^[3] The suprascapular nerve is prone to entrapment as it passes under the superior transverse scapular ligament (STSL)^[2,4–6] The sharp inferior margin of STSL damages the nerve with a “sling effect” at the scapular notch.^[1] Recent studies have also


Correspondence: İlke Ali Gürses, MD. İstanbul Üniversitesi İstanbul Tıp Fakültesi, Anatomi Anabilim Dalı, İstanbul, Turkey.

Tel: +90 212 – 414 21 76 e-mail: iagurses@gmail.com

Submitted: September 18, 2014 **Accepted:** January 3, 2015

©2015 Turkish Association of Orthopaedics and Traumatology

Available online at
www.aott.org.tr
doi: 10.3944/AOTT.2015.14.0333
QR (Quick Response) Code



shown that vascular structures that pass under STSL may also cause suprascapular nerve entrapment.^[7,8]

Avery et al.^[9] identified a ligament inferior to STSL at the suprascapular notch that may cause entrapment and named it the anterior coracoscapular ligament (ACSL). Similarly, Polguy et al.^[10] observed that the area between STSL was significantly decreased if ACSL was present. The prevalence of ACSL differs among populations. It was reported as 60% by Avery et al.^[9] in the American population, approximately 51% by Polguy et al.^[10,11] in the Polish population, 28% by Piyawinijwong&Tantipoon^[12] in the Thai population, and 18.8% by Bayramoğlu et al.^[13] in the Turkish population.

Although the anatomy of the suprascapular region is well studied, no reports have investigated the anatomical relations of the suprascapular vessels to STSL and the presence of ACSL. We investigated the presence of ACSL and its relations with the neighboring neurovascular structures with the aim of outlining the detailed anatomy of the suprascapular region and the possible effects of ACSL on suprascapular nerve entrapment.

Materials and methods

We studied 26 cadavers embalmed in formaldehyde-ethanol-glycerin-phenol solution (5 females, 21 males) used for routine dissections by second-year medical students. We excluded 2 shoulders because of prior shoulder surgery. Therefore, we investigated 50 shoulders. Using 2.5× loop magnification (Univet Co., Italy), we identified the suprascapular nerve and vessels from

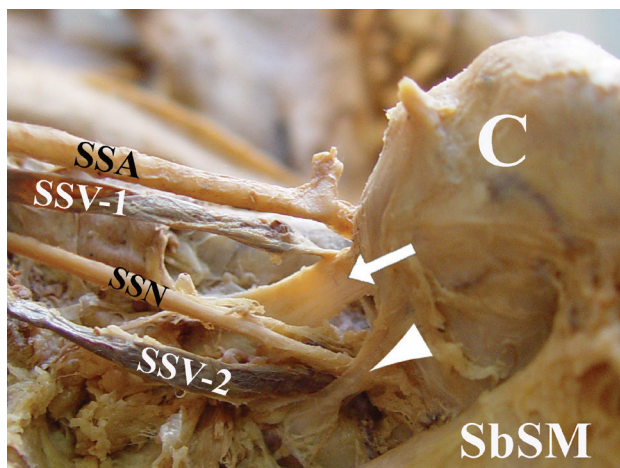


Fig. 1. Anterior view of a left shoulder depicting a Type IIa anatomical relations, where a suprascapular vein passes between STSL and ACSL with the suprascapular nerve. C: coracoid process, SSA: suprascapular artery, SSV: suprascapular vein, SSN: suprascapular nerve, SbSM: subscapularis muscle, arrow: STSL, arrowhead: ACSL. [Color figure can be viewed in the online issue, which is available at www.aott.org.tr]

their origins and traced their course until they reached the suprascapular notch. After identifying STSL, we investigated the presence of ACSL. We classified ACSL morphology according to the classification of Polguy et al.^[11] We evaluated the anatomical relations of the suprascapular nerve, artery, and vein(s) with both the ligaments. Type I indicated a single suprascapular nerve that passed between STSL and ACSL. Type II indicated the presence of a single suprascapular vein passing under STSL. Type II was further split into 2 groups: Type IIa indicated that the suprascapular vein and nerve passed between STSL and ACSL, whereas Type IIb indicated that the suprascapular vein passed under ACSL and the suprascapular nerve passed between STSL and ACSL. Type III indicated the suprascapular artery, vein, and nerve all passed between STSL and ACSL.

Results

STSL was present in all shoulders, whereas ACSL was present in only 16 shoulders (32%). The suprascapular nerve passed between STSL and ACSL in all shoulders with ACSL. Seven cadavers (1 female, 6 males) had ACSL bilaterally and 2 cadavers (2 males) had ACSL unilaterally. ACSL morphology was uniformly fan shaped in 4 shoulders (25%), band shaped in 11 shoulders (68.7%), and vestigial in 1 shoulder (6.3%). A single suprascapular nerve passed between STSL and ACSL (Type I) in 7 shoulders (14%). We observed that the vascular structures passed under STSL with the suprascapular nerve in 9 shoulders (18%). A single suprascapular vein with suprascapular nerve passed between STSL and ACSL (Type IIa) in 6 shoulders (12%) (Figure 1). A single suprascapular vein passed under ACSL (Type IIb) in 1 shoulder (2%) (Figure 2). A suprascapular ar-

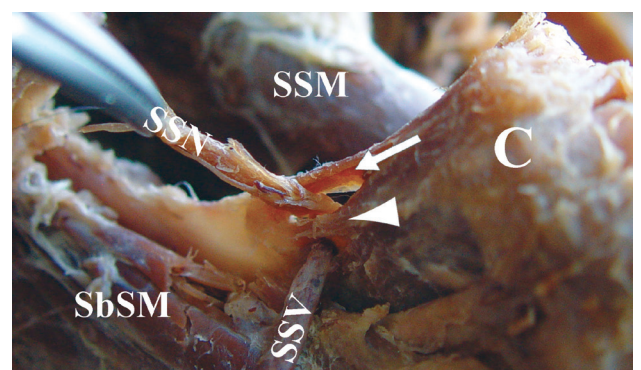


Fig. 2. Anterior view of a left shoulder showing a Type IIb anatomical relation. A single suprascapular vein passes under ACSL. C: coracoid process, SSV: suprascapular vein, SSN: suprascapular nerve, SSM: supraspinatus muscle, SbSM: subscapularis muscle, arrow: STSL, arrowhead: ACSL. [Color figure can be viewed in the online issue, which is available at www.aott.org.tr]

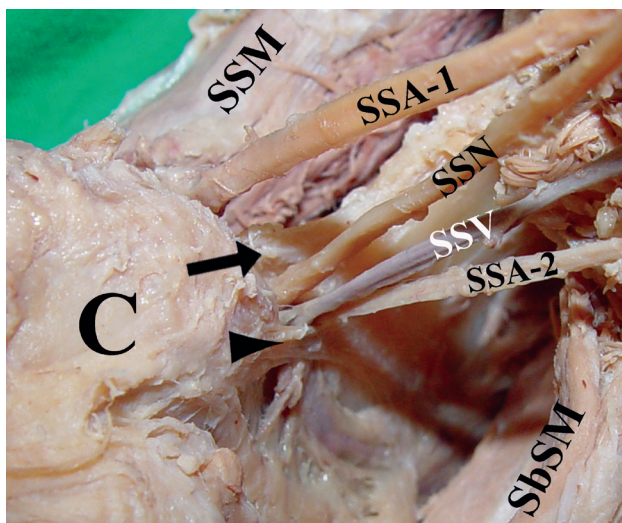


Fig. 3. Anterior view of a right shoulder illustrating a Type III anatomical relation. The suprascapular artery, vein, and nerve passes between STSL and ACSL. C: coracoid process, SSA: suprascapular artery, SSV: suprascapular vein, SSN: suprascapular nerve, SSM: supraspinatus muscle, SbSM: subscapularis muscle, arrow: STSL, arrowhead: ACSL. [Color figure can be viewed in the online issue, which is available at www.aott.org.tr]

tery, vein, and nerve passed between STSL and ACSL (Type III) in 2 shoulders (4%) (Figure 3). The classification and their frequencies are outlined in Table 1.

Discussion

In most individuals, the sling effect of STSL compromises the suprascapular nerve at the scapular notch.^[1,2] The suprascapular artery under STSL may also be responsible for entrapment by occupying space within the scapular foramen.^[7,8] Therefore, the presence of ACSL may cause nerve entrapment by further decreasing the space under STSL.^[1,2] The anatomical relations between neurovascular structures around STSL as well as the effects of ACSL on the same have not been in-

vestigated before. We observed that the suprascapular vessels may pass between STSL and ACSL or pass under ACSL in 18% of the shoulders in our study sample (Types IIa, IIb, and III). We believe that these anatomical relations may predispose to suprascapular nerve entrapment.

Previous studies have reported widely variable ACSL prevalence across different populations, with a values ranging from 18.8% to 60%.^[9-13] We observed ACSL prevalence of 32% in our study.

Polguy et al.^[11] provided a detailed classification of ACSL morphology and observed 4 types: Type I (7%) was fan shaped, Type II (62.8%) was uniform band shaped, Type III (11.6%) was bifid, and Type IV (18.6%) was vestigial. In our sample, ACSL was fan shaped in 25%, band shaped in 68.7%, and vestigial in 6.3%. We did not observe a bifid ACSL (Type III) in our study. The difference in the frequencies of morphological types in our study may be related to our small sample size.

Avery et al.^[9] observed that the suprascapular nerve passed under ACSL if the ligament was present. In contrast, Polguy et al. observed this, in 2 separate studies,^[10,11] only in 2 of 43 and 3 of 44 shoulders, respectively. Piyawinijwong&Tantipoon^[12] and Bayramoğlu et al.^[13] reported that the suprascapular nerve passed between STSL and ACSL in all cases. The suprascapular nerve passed between STSL and ACSL in all shoulders with ACSL in our study sample.

The presence of ACSL may lead to suprascapular nerve entrapment in 2 ways. First, it may decrease the area of the scapular foramen.^[9] Polguy et al.^[10] demonstrated that the area of the scapular foramen was significantly reduced when it was formed by ACSL and a band shaped or bifid STSL. This suggest that the presence of ACSL increases the risk of suprascapular nerve entrapment by decreasing the area of the scapular foramen.

Table 1. Classification for anatomical relations of suprascapular neurovascular structures and their frequencies.

	Type I	Type II		Type III
		IIa	IIb	
Anatomic relations	A. + V. + (V.)	A. + V.	A. + V.	V.
STSL	N.	N. + V.	N.	N. + A. + V.
ACSL			V.	
Scapula				
Results (n)	7 (14%)	6 (12%)	1 (2%)	2 (4%)

STSL: Superior transverse scapular ligament; ACSL: Anterior coracoscapsular ligament. A: Suprascapular artery; V: Suprascapular vein(s); N: Suprascapular nerve.

The second way that the presence of ACSL may impact suprascapular nerve entrapment is that if any other structures pass between ACSL and STSL, it will further decrease the area of the scapular foramen. It is well known that the suprascapular artery and vein(s) pass under STSL infrequently.^[5,6,14] However, these studies do not mention the anatomical relations between the suprascapular vessels and ACSL. We observed that in 18% of the shoulders in our study sample, the suprascapular vessels passed between STSL and ACSL or under ACSL. Our proposed classification outlines possible anatomical scenarios that may lead to suprascapular nerve entrapment.

In Type IIa of our classification, a single suprascapular vein accompanied the suprascapular nerve between STSL and ACSL, was observed in 12% of the shoulders in our sample. In the literature, only Avery et al.^[9] reported the same anatomical variant with a frequency of 19%. We also observed that in 4% of shoulders in our sample, a suprascapular artery accompanied the suprascapular nerve and vein between STSL and ACSL (Type III). Reineck&Krishnan^[7] reported the first 3 cases in which the suprascapular artery passed under STSL and caused suprascapular nerve entrapment. They released STSL with an endoscopic approach but did not provide any follow-up information.^[7] Houtz&McCulloch^[8] treated a similar case whose electromyographic results improved after endoscopic release of STSL with no signs of denervation and was symptom free after 1 year. These studies did not investigate whether ACSL was present or contributed to nerve entrapment. Similarly, we did not observe a case in which a suprascapular artery accompanied the suprascapular nerve without the suprascapular vein between STSL and ACSL. Nevertheless, when suprascapular vein and/or artery pass under STSL, the presence of ACSL would decrease the space under STSL and may lead to nerve entrapment. The presence of an artery may be more likely to lead suprascapular nerve entrapment.^[7,8]

In Type IIb (2%), we observed that a single suprascapular vein, which was either dilated or varicose, passing under ACSL. Although venous pathologies have not been reported as possible causes of entrapment at the suprascapular notch, suprascapular nerve entrapment due to varicose veins at the spinoglenoid notch have been reported.^[15,16] Among the 7 cases reported, only 1 had a history of varicectomy of the lower limbs that may explain the development of varicose veins at the spinoglenoid notch. We believe that the decreased space under ACSL may compress and dilate the vein, which may then lead to nerve entrapment.

A limitation of our study is that we did not evaluate the area between STSL and ACSL and the area under ACSL. Unfortunately, we are unable to support the increased risk of nerve entrapment with a statistically significant methodology. Another limitation is that this was a cadaveric study with a relatively small sample size; therefore we could not verify nerve entrapment in the shoulders in our study sample. Our results are experimental and should not be taken as definitive. Finally, the clinical applications related to the anatomy of ACSL are limited. Although its presence may have a role in suprascapular nerve entrapment, this will not affect patient management unless the nerve passes under this ligament. However, we believe that our study presents novel anatomical insight to the anatomy of the suprascapular region and the suprascapular nerve entrapment.

Acknowledgments

We thank our donor-cadavers and their immediate families for their invaluable gifts and for making this research possible. We also wish to thank David F. Chapman (BSc.) for editing the English of our manuscript.

Conflicts of Interest: No conflicts declared.

References

1. Rengachary SS, Burr D, Lucas S, Hassanein KM, Mohn MP, Matzke H. Suprascapular entrapment neuropathy: a clinical, anatomical, and comparative study. Part 2: anatomical study. *Neurosurgery* 1979;5:447–51.
2. Zehetgruber H, Noske H, Lang T, Wurnig C. Suprascapular nerve entrapment. A meta-analysis. *Int Orthop* 2002;26:339–43.
3. Harbaugh KS, Swenson R, Saunders RL. Shoulder numbness in a patient with suprascapular nerve entrapment syndrome: cutaneous branch of the suprascapular nerve: case report. *Neurosurgery* 2000;47:1452–6.
4. Rengachary SS, Neff JP, Singer PA, Brackett CE. Suprascapular entrapment neuropathy: a clinical, anatomical, and comparative study. Part 1: clinical study. *Neurosurgery* 1979;5:441–6.
5. Duparc F, Coquerel D, Ozeel J, Noyon M, Gerometta A, Michot C. Anatomical basis of the suprascapular nerve entrapment, and clinical relevance of the supraspinatus fascia. *Surg Radiol Anat* 2010;32(3):277–84.
6. Yang HJ, Gil YC, Jin JD, Ahn SV, Lee HY. Topographical anatomy of the suprascapular nerve and vessels at the suprascapular notch. *Clin Anat* 2012;25:359–65.
7. Reineck JR, Krishnan SG. Subligamentous suprascapular artery encountered during arthroscopic suprascapular nerve release: a report of three cases. *J Shoulder Elbow Surg* 2009;18:1–3.
8. Houtz C, McCulloch PC. Suprascapular vascular anomaly.

- lies as a cause of suprascaphular nerve compression. *Orthopedics* 2013;36:42–5.
9. Avery BW, Pilon FM, Barclay JK. Anterior coracoscaphular ligament and suprascaphular nerve entrapment. *Clin Anat* 2002;15:383–6.
 10. Polguy M, Jędrzejewski K, Podgórski M, Majos A, Topol M. A proposal for classification of the superior transverse scaphular ligament: variable morphology and its potential influence on suprascaphular nerve entrapment. *J Shoulder Elbow Surg* 2013;22:1265–73.
 11. Polguy M, Jędrzejewski K, Topol M. Variable morphology of the anterior coracoscaphular ligament - a proposal of classification. *Ann Anat* 2013;195:77–81.
 12. Piyawinjiwong S, Tantipoon P. The anterior coracoscaphular ligament in Thais: possible etiological factor of suprascaphular nerve entrapment. *Siriraj Med J* 2012;64(Suppl I):12–4.
 13. Bayramoğlu A, Demiryürek D, Tüccar E, Erbil M, Aldur MM, Tetik O, et al. Variations in anatomy at the suprascaphular notch possibly causing suprascaphular nerve entrapment: an anatomical study. *Knee Surg Sports Traumatol Arthrosc* 2003;11:393–8.
 14. Cummins CA, Anderson K, Bowen M, Nuber G, Roth SI. Anatomy and histological characteristics of the spinoglenoid ligament. *J Bone Joint Surg Am* 1998;80:1622–5.
 15. Carroll KW, Helms CA, Otte MT, Moellken SM, Fritz R. Enlarged spinoglenoid notch veins causing suprascaphular nerve compression. *Skeletal Radiol* 2003;32:72–7.
 16. Van Meir N, Fourneau I, Debeer P. Varicose veins at the spinoglenoidal notch: an unusual cause of suprascaphular nerve compression. *J Shoulder Elbow Surg* 2011;20:21–4.