

# Comparison of ST-Segment Duration and Morphology between Clinically Healthy and Diarrheic Holstein Dairy Calves

Aliasghar CHALMEH\*, Mehrdad POURJAFAR, Mojtaba NAGHIB

Department of Clinical Sciences, School of Veterinary Medicine, Shiraz University, Shiraz, Iran

\*Corresponding Author: Aliasghar CHALMEH Shiraz University, School of Veterinary Medicine,  
Department of Clinical Sciences, Shiraz, Iran

e-mail: achalmeh81@gmail.com

Geliş Tarihi / Received: 25.05.2013

## ABSTRACT

Several diarrheic (n=52) and clinically healthy (n=21) calves were randomly selected and assigned into 3 age groups, comprising newborn calves (18 to 72 hours; n=31), 15 (n=30) and 30 days old (n=12). Electrocardiograms were recorded on a bipolar base apex lead, using limb lead I and duration, amplitude and morphology of the ST-segment were assessed from successive beats. Serum concentration of sodium, potassium, magnesium and ionized calcium were also determined in all studied animals. ST-segment duration had not significant differences among any groups. Elevation of ST-segment was detected in 75% of healthy newborn calves (amplitude was  $0.10\pm 0.03$  mV in elevated ST-segments). The ST-segment was elevated in a percent of diarrheic calves; there was elevation in 78.9% ( $0.14\pm 0.04$  mV), 34.6% ( $0.11\pm 0.04$  mV) and 57.1% ( $0.11\pm 0.04$  mV) in newborn, 15 and 30 days old diarrheic calves, respectively. Serum potassium, calcium and magnesium concentrations in all studied diarrheic calves were higher than healthy calves, significantly. It may be stated the electrolyte imbalances in diarrheic calves can induce alterations in ST-segment morphology and the results of the current study may interpret the alterations of ST-segment morphology in diarrheic calves.

**Key Words:** ST-segment, diarrhea, electrolyte imbalance, calves.

## ÖZET

### KLİNİK AÇIDAN SAĞLIKLI VE İSHALLİ SİYAH ALACA IRKI BUZAĞILARDA ST SEGMENTİNİN SÜRESİNİN KARŞILAŞTIRILMASI

Çeşitli ishalleri (n=52) ve klinik açıdan sağlıklı buzağular rastgele seçilmiştir ve yeni doğan (18-72 saatler arasında, n=31), 15 (n=30) ve 30 (n=12) günlük buzağuları içeren 3 farklı grup oluşturulmuştur. Elektrokardiyografiler bipolar taban-apeks derivasyonu kullanılarak kaydedildi, bacak derivasyon I ve zamanı, ST segmentinin morfolojisi ve amplitüde ardaşık atımlardan belirlendi. Çalışmaya katılan bütün hayvanlardaki serum sodyum, potasyum, magnezyum ve iyonize kalsiyum konsantrasyonları belirlendi. Gruplar arasında ST segmenti süresi belirgin değişikliklere sahip değildi. Sağlıklı yenidoğan buzağuların %75'inde ST segmentinin artışı belirlendi (artan ST segmentlerindeki amplitüt  $0,10\pm 0,03$  mV). İshalleri buzağuların bir kısmında da ST segmentinde artış oldu. Yeni doğan, 15 ve 30 günlük buzağuların sırasıyla, %78,9 ( $0,14\pm 0,04$  mV), %34,6 ( $0,11\pm 0,04$  mV) ve %57,1 ( $0,11\pm 0,04$  mV)'de olmuştur. Çalışmadaki bütün ishalleri buzağulardaki serum potasyum, kalsiyum ve magnezyum konsantrasyonları sağlıklı olanlara göre önemli derecede yüksektir. İshalleri buzağulardaki elektrolit dengesizliği ST segment morfolojisindeki bu değişimlere sebep olduğu ve yapılan bu çalışma ile ishalleri buzağulardaki ST segmentinin morfolojisindeki değişimlerin yorumlanabileceği belirtilebilir.

**Anahtar Kelimeler:** ST segmenti, ishal, elektrolit dengesizliği, buzağı

## Introduction

Electrocardiography can diagnose and classify the cardiac arrhythmias, conduction abnormalities and assess the responses to therapeutic regimens in large animals (Radostits et al., 2007). The electrocardiogram (ECG) provides a record and measure of the time varying potential difference which occurs over the surface of the body as the result of electrical activity within the heart. This is associated with depolarization and repolarization of the myocardium that occurs in a definite pattern and sequence and then the ECG can be used to measure and time these events (Radostits et al., 2007).

The potential use of bovine electrocardiography is well recognized (Deroth, 1980) and the ST-segment duration in cattle is reported by some researchers (Deroth, 1980; GhiĀā et al., 2008a; GhiĀā et al., 2008b; Mendes et al., 2001; Pourjafar et al., 2012). The ST-segment connects the QRS complex and the T wave (Gertsch, 2009). Morphological assessment of ST-segment in human is one of the diagnostic parameters in some of the cardiac (HaĀgmark et al., 2005) and non-cardiac (Gertsch, 2009) problems. Elevation and depression of this segment in human beings represent the disorders such as ischemia and infarction, electrolyte imbalances, conduction abnormalities, cardiac cavities and valves problems and etc. (HaĀgmark et al., 2005; Gertsch, 2009). Knowledge of morphology of ST-segment may help veterinarians to detect some of the patient problems from the observation of ECGs. According to the author's knowledge, there is only one research on bovine ST-segment morphology in clinically healthy calves (Pourjafar et al., 2012) and there is no study on this electrocardiographic parameter in diarrheic ones. Since electrolyte imbalance is one of the common causes of ST-segment elevation or depression in human beings (Gertsch, 2009; HaĀgmark et al., 2005), we assessed the effect of diarrhea, as an agent which alters normal serum electrolyte profile, on ST-segment morphology in diarrheic newborn calves. Hence, the present study compared the ST-segment duration and

morphology along with the serum electrolyte concentrations in clinically healthy and diarrheic Holstein dairy calves in three age groups.

## Materials and Methods

### Animals

The present study was carried out from July 2009 till February 2010 on 73 Holstein dairy calves around Shiraz (latitude 29°33'N and longitude 052°36'E, 1486 m above sea level), southwest Iran. Several diarrheic (n=52) and clinically healthy (n=21) calves were randomly selected. Diarrheic calves before any treatment were clinically examined and fecal consistency was assessed. The diarrheic and healthy animals were assigned into 3 age groups, comprising newborn calves (18 to 72 hours; n=31), 15 (n=30) and 30 days old (n=12).

### Electrocardiographic examinations

The ECGs were recorded on a bipolar base apex lead, using limb lead I. Animals were kept in a right lateral recumbency position in a stock without sedation and minimal restraint. No clipping or shaving was carried out for electrode attachment. When the animals were thought to be in a quiet state, the ECGs were recorded, using alligator-type electrodes which were attached to the skin after cleaning it with ethanol and applying electrocardiographic jelly. The positive electrode (left arm) of lead I was attached to the skin of the left thorax at the fifth intercostal space, immediately caudal to the olecranon, and the negative electrode (right arm) was placed on the jugular furrow in the caudal third of the left neck (Radostits et al., 2007). All ECGs were obtained on a single channel electrocardiographic machine (Kenzline EKG 110, Suzuken Co., Ltd., Japan) with the paper speed 25 mm/sec. and calibration of 10 mm equal to 1 mV. Duration and morphology of the ST-segment were assessed from successive beats following the usual conventions. By this method of measuring, the precision of duration was 0.02 sec. and amplitude was 0.05 mV.

### Serum electrolytes determination

Blood samples were collected from all calves through the jugular vein. Immediately after collection, the serum was separated by centrifugation (for 10 min at 3,000×g) and stored at -22°C until assayed. Finally, serums were sent to laboratory to determine sodium, potassium, magnesium and ionized calcium concentrations. The serum samples were analyzed for sodium and potassium by automatic electrolyte analyzer (Convergys ISE NG, GmbH, Germany) and concentrations of calcium and magnesium were assayed by atomic absorption spectrophotometry (Shimadzo AA- 670, Kyoto, Japan).

### Definitions

Evaluation of fecal consistency was performed using following criteria: 0 or 'normal': firm consistency, brown colour, perineum and tail of the calf is clean and dry; 1: a paste-like consistency, yellow colour and perineum and/or tail of the calf is smeared with feces; 2: watery consistency, perineum and/or tail of the calf is smeared with watery feces. Fecal score 1 and 2 were considered as diarrheic. The P wave, QRS complex and T wave are the recognizable deflections of the ECG tracing and indicate atrial depolarization (P), ventricular depolarization (QRS), and ventricular repolarization (T). The ST-segment is the portion of the tracing falling between the QRS complex and the T wave. During this time, the ventricle is contracting, but no electricity is flowing. The ST-segment is therefore usually even with the baseline (line drawn from P start to T end). It represents the period of slow repolarization of the ventricles. ST-segment may be horizontal, elevated or depressed (Gertsch, 2009).

### Statistical analysis

Mean and standard deviation (SD) were calculated for ST-segment duration, amplitude, serum sodium, potassium, calcium and magnesium in different groups. The comparison of these parameters between clinically healthy and diarrheic calves in each group was done by

two independent samples t-test. Each parameter in all age groups was analyzed by the one way ANOVA, using SPSS software (SPSS for Windows, version 11.5, SPSS Inc, Chicago, Illinois).  $P < 0.05$  was considered statistically significant.

### Results

The standard electrocardiographic ST-segment durations (Mean±SD) of base apex lead in different ages of two groups were shown in Tables 1. ST-segment duration had not significant differences among any groups. The morphological assessments of ECGs showed that healthy calves had normal isoelectric (horizontal) ST-segment, except newborns. Elevation of ST-segment was detected in 75% of healthy newborn calves (amplitude was  $0.10 \pm 0.03$  mV in elevated ST-segments). The ST-segment was elevated in a percent of diarrheic calves; there was elevation in 78.9% ( $0.14 \pm 0.04$  mV), 34.6% ( $0.11 \pm 0.04$  mV) and 57.1% ( $0.11 \pm 0.04$  mV) in newborn, 15 and 30 days old diarrheic calves, respectively.

The results of the serum electrolytes evaluation, showed that serum potassium, calcium and magnesium concentrations in all studied diarrheic calves were higher than healthy calves, significantly. There were no significant differences in serum concentration of sodium between healthy and diarrheic calves ( $P > 0.05$ ).

### Discussion

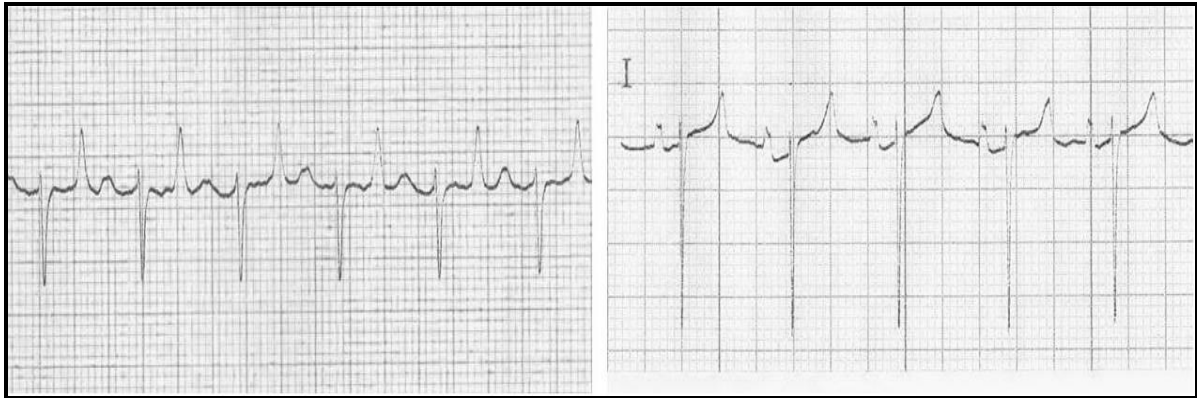
Evaluating cardiac problems can perform by electrocardiography as the clinical method of choice (Santamarina et al., 2001). There is little information on neonatal bovine electrocardiography and studies on some electrocardiographic parameters such as ST-segment duration and morphology has been scarcely touched (Deroth, 1980; GhiŃă et al., 2008a; GhiŃă et al., 2008b; Pourjafar et al., 2012). Pourjafar et al. (2012) reported ST-segment duration and morphology in different ages of clinically healthy Holstein dairy cattle. But, the present study compared this segment between healthy and diarrheic Holstein dairy calves.

**Table 1.** ST-segment duration, incidence of ST-segment elevation and serum concentrations of electrolytes in clinically healthy and diarrheic Holstein dairy calves in 3 age groups.

**Tablo 1.** Üç farklı yaş grubundaki klinik açıdan sağlıklı ve ishalleri Siyah Alaca buzağlarındaki serum elektrolit konsantrasyonları, ST segment yüksekliğinin insidensi ve ST segment zamanı.

	Na (mEq/L)	K (mEq/L)	Ca (mg/dL)	Mg (mg/dL)	ST-duration (sec)	ST-elevation (%)
Healthy newborn (n=12)	141.5±3.5	5.0±0.2 <sup>a</sup>	2.7±0.3 <sup>a</sup>	0.8±0.1 <sup>a</sup>	0.11±0.02	75%
Diarrheic newborn (n=19)	141.8±7.0	8.0±0.3 <sup>b</sup>	5.8±1.0 <sup>b</sup>	2.1±1.1 <sup>b</sup>	0.10±0.02	78.9%
Healthy 15 days (n=4)	133.0±1.6	5.1±0.0 <sup>a</sup>	2.5±0.2 <sup>a</sup>	0.8±0.2 <sup>a</sup>	0.09±0.03	----
Diarrheic 15 days (n=26)	134.4±10.2	8.3±1.0 <sup>b</sup>	4.8±0.7 <sup>b</sup>	1.9±0.2 <sup>b</sup>	0.12±0.02	34.6%
Healthy 30 days (n=5)	137.2±1.0	5.1±0.3 <sup>a</sup>	2.7±0.2 <sup>a</sup>	0.8±0.1 <sup>a</sup>	0.13±0.03	----
Diarrheic 30 days (n=7)	138.2±6.8	9.1±0.3 <sup>b</sup>	4.4±0.5 <sup>b</sup>	1.6±0.0 <sup>b</sup>	0.11±0.02	57.1%

Different letters indicate significant differences ( $P<0.05$ ) in each column.



**Figure 1.** Left: Horizontal ST-segment in electrocardiogram tracing from a clinically healthy 15 days old Holstein dairy calf; Right: Elevation of ST-segment in electrocardiogram tracing from a newborn diarrheic Holstein dairy calf (base apex lead, paper speed 25 mm/sec, sensitivity 10 mm/mV).

**Şekil 1.** Sol: Klinik açıdan sağlıklı 15 günlük Siyah Alaca ırkı buzağının elektrokardiyogramdaki horizontal ST segmenti; Sağ: Yeni doğan ishalleri Siyah Alaca ırkı buzağında elektrokardiyogramdaki ST segmenti artışı.

The results of the present study showed that ST-segment duration was not significantly different among any healthy and diarrheic groups. The length of the ST-segment shortens with increasing heart rate (Milhorn, 2005) and since the heart rate of calves is higher than adult cows, the duration of ST-segment in calves may be shorter than adults. Mean of the ST-segment length in our study traced by base apex lead was 0.11±0.02 sec. in healthy newborns. However, the magnitude of this parameter in healthy newborn calves, reported by other

researcher in different leads, other than base apex, was 0.12±0.02 sec. (standard bipolar, augmented unipolar and unipolar chest leads) (Mendes et al., 2001) and 0.11±0.00 sec. (3 bipolar and 3 unipolar leads) (GhiŃă et al., 2008a). The results of our study showed that mean of ST-segment duration was 0.13±0.03 sec. in 1 month old healthy calves. Mendes et al. (2001) also reported a level of 0.13±0.02 sec. for ST-segment duration in 1 month old Holstein calves in other leads than base apex

(standard bipolar, augmented unipolar and unipolar chest leads).

Upward or downward shifts in the ST-segment were evaluated in this study. Our findings showed that elevation of ST-segment was seen in healthy newborns and a percent of diarrheic calves (Table 1). Pourjafar et al. (2012) reported 64.2% elevation of ST-segment in healthy newborn Holstein dairy calves. They suggested that electrolyte imbalances in clinically healthy newborn calves during parturition can induce ST-segment elevation. In our study, 75% of clinically healthy newborn calves showed ST-segment elevation.

Elevation of the ST-segment from baseline in human beings, can indicate right or left bundle branch block, left ventricular hypertrophy, acute myocardial infarction, myocardial contusion, pericarditis, left ventricular aneurysm, acute myocarditis, right ventricular infarction, dissecting aortic aneurysm, acute pulmonary embolism, various central and autonomic nervous system abnormalities, thiamine deficiency, hypercalcaemia, hyperthyroidism, hyperkalaemia and compression of right ventricular outflow tract by metastatic tumour (Gertsch, 2009; Haeggmark et al., 2005). In some healthy young adult humans, a form of ST-segment elevation can be normal (Wang et al., 2003) and the mechanisms of ST-segment changes have not yet been fully clarified (Hashimoto et al., 1983); however, such literatures mention that the ST-segment elevation is the result of an epicardium to endocardium voltage gradient during the early repolarization phases of the action potential (Grant, 2001).

The results of the present study showed that concentrations of serum ionized calcium in diarrheic calves were higher than healthy calves in all groups significantly. It seems that the alternation in the calcium flow during the action potential phase may be involved in ST-segment changes. It has been suggested that alteration of the slow inward calcium currents is involved in the configurational changes in the action potential by incomplete electrical restitution (Hashimoto et al., 1983). ST-elevation

secondary to hypercalcemia has been described as one of the common cause of ST-segment elevation (Nishi et al., 2006).

The concentrations of serum magnesium in healthy calves were significantly lower than diarrheics. Several literatures mention magnesium significantly attenuated the ST-segment elevation and ventricular conduction slowing caused by myocardial infarction in human beings (Nattel et al., 1991). Our findings showed that both high magnesium concentrations and ST-segment elevation were presented in diarrheic calves together. It may be stated that hypercalcemia in diarrheic calves masked the paradoxical effects of high serum magnesium concentrations in elevation of ST-segment.

The results of our study showed that concentrations of serum sodium in healthy calves were approximately similar to diarrheic calves and no significant differences were shown in this electrolyte in any groups. Some studies have shown that administration of a sodium channel blocker results in induction of ST-elevation. It has been suggested that genetic sodium channel dysfunction can explain the ST-elevation and the occurrence of ventricular arrhythmia, which are exaggerated by administration of the sodium channel blocker (Antzelevitch, 2001; Chen et al., 1998; Towbin, 2001; Yan and Antzelevitch, 1999), since decreasing serum sodium concentrations, induces elevation of ST-segment.

Hyperkalemia is a common problem associated with the acid-base and electrolyte disturbances that occur in neonatal calves having dystocia (Nagy, 2009). In human beings, hyperkalemia is also well recognized as a cause of ST-segment elevation (Wang et al., 2003). Based to our results, there were significant differences between serum potassium concentrations of healthy and diarrheic calves in all age groups and the ST-segment elevation may be due to hyperkalemia in diarrheic calves.

In conclusion, it may be stated the electrolyte imbalances in diarrheic calves can induce alterations in ST-segment morphology. Since, electrocardiographic studies of ST-

segment, may aid veterinarians to diagnose and treatment of some electrolyte imbalances in calves. The results of the current study may interpret the alterations of ST-segment morphology in diarrheic calves.

### Acknowledgment

The authors would like to sincerely thank Mr. Reza Chalmeh for statistical analysis of our data.

### REFERENCES

- Antzelevitch, C., 2001.** The Brugada syndrome: diagnostic criteria and cellular mechanisms. *European Heart Journal* 22, 356-363.
- Chen, Q., Kirsch, G.E., Zhang, D., Brugada, R., Brugada, J., Brugada, P., Potenza, D., Moya, A., Borggrefe, M., Breithardt, G., Ortiz-Lopez, R., Wang, Z., Antzelevitch, C., O'Brien, R.E., Schulze-Bahr, E., Keating, M.T., Towbin, J.A., Wang, Q., 1998.** Genetic basis and molecular mechanisms for idiopathic ventricular fibrillation. *Nature* 392, 293-296.
- Deroth, L., 1980.** Electrocardiographic parameters in the normal lactating Holstein cow. *Canadian Veterinary Journal* 21, 271-277.
- Gertsch, M., 2009.** Electrolyte imbalance and disturbances, In: *The ECG Manual: An Evidence-Based Approach*. Springer, pp. 177-190.
- GhiÑã, M., Cotor, G., Brãslasu, C., 2008a.** The values of ECG parameters in newborn calves. *Bulletin UASVM, Veterinary Medicine* 65, 473.
- GhiÑã, M., Cotor, G., Brãslasu, C., 2008b.** The values of some ECG components in dairy cows, using Dubois leads. *Bulletin UASVM, Veterinary Medicine* 65, 474.
- Grant, A.O., 2001.** Molecular biology of sodium channels and their role in cardiac arrhythmias. *American Journal of Medicine* 110, 296-305.
- Ha"ggmark, S., Haney, M.F., Jensen, S.M., Johansson, G., Na'slund, U., 2005.** ST-segment deviations during pacing-induced increased heart rate in patients without coronary artery disease. *Clinical Physiology and Functional Imaging* 25, 246-252.
- Hashimoto, H., Suzuki, K., Miyake, S., Nakashima, M., 1983.** Effects of calcium antagonists on the electrical alternans of the ST segment and on associated mechanical alternans during acute coronary occlusion in dogs. *Circulation* 68, 667-672.
- Mendes, L.C.N., Camacho, A.A., Alves, A.L.G., Borges, A.S., Souza, R.C.A., Ferreira, W.L., 2001.** Standard electrocardiographic values in Holstein calves. *Arquivo Brasileiro de Medicina Veterinária e Zootecnia* 53, 641-644.
- Milhorn, H.T., 2005.** The electrocardiogram. In: *Electrocardiography for the Family Physician, the Essentials*. Brown Walker Press 11.
- Nagy, D., 2009.** Resuscitation and critical care of neonatal calves. *Veterinary Clinics of North America: Food Animal Practice* 25, 1-11.
- Nattel, S., Turmel, N., Macleod, R., Solymoss, B.C., 1991.** Actions of intravenous magnesium on ventricular arrhythmias caused by acute myocardial infarction. *The Journal of Pharmacology and Experimental Therapeutics* 259, 939-946.
- Nishi, S.P., Barbagelata, N.A., Atar, S., Birnbaum, Y., Tuero, E., 2006.** Hypercalcemia-induced ST-segment elevation mimicking acute myocardial infarction. *Journal of Electrocardiology* 39, 298-300.
- Pourjafar, M., Badie, K., Chalmeh, A., 2012.** Evaluation of ST-segment duration and morphology of standard base apex lead electrocardiograms in different age groups of apparently healthy Holstein cattle. *Journal of the Faculty of Veterinary Medicine Istanbul University* 38, 51-57.
- Radostits, O.M., Gay, C.C., Hinchcliff, K.W., Constable, P.D., 2007.** Diseases of the cardiovascular system, In: *Veterinary Medicine: A Text Book of the Diseases of Cattle, Horses, Sheep, Pigs and Goats*. 10<sup>th</sup> ed., Elsevier, pp. 399-438.
- Santamarina, G., Espino, L., Suarez, L.M., 2001.** Electrocardiographic parameters of free-ranging roe deer (*Capreolus capreolus*). *Journal of Zoo and Wild Life Medicine* 32, 441-446.
- Towbin, J.A., 2001.** Ventricular tachycardia or conduction disease: what is the mechanism of death associated with SCN5A? *Journal of Cardiovascular Electrophysiology* 12, 637-688.
- Wang, K., Asinger, R.W., Marriott, H.J.L., 2003.** ST-segment elevation in conditions other than acute myocardial infarction. *The New England Journal of Medicine* 349, 2128-2135.
- Yan, G.X., Antzelevitch, C., 1999.** Cellular basis for the Brugada syndrome and other mechanisms of arrhythmogenesis associated with ST-segment elevation. *Circulation* 100, 1660-1666.