

# Journal of Pediatric Sciences

## **SPECIAL ISSUE : “*Pediatric Oncology*”**

Editor:

**Jan Styczynski**

Department of Pediatric Hematology and Oncology  
Collegium Medicum, Nicolaus Copernicus University, Bydgoszcz, Poland

### *Osteosarcoma: diagnosis and treatment*

*Milan Samardziski, George Zafiroski, Vesna Janevska, Olivera Muratovska,  
Sofijanka Glamocanin, Violeta Vasilevska-Nikodinovska*

Journal of Pediatric Sciences 2010;2(3):e29

#### **How to cite this article:**

**Samardziski M., Zafiroski G., Janevska V., Muratovska O., Glamocanin S.,  
Vasilevska-Nikodinovska V. Osteosarcoma: diagnosis and treatment.  
Journal of Pediatric Sciences. 2010;2(3):e29**

## REVIEW ARTICLE

## Osteosarcoma: diagnosis and treatment

Milan Samardziski<sup>1</sup>, George Zafiroski<sup>1</sup>, Vesna Janevska<sup>2</sup>, Olivera Muratovska<sup>3</sup>, Sofijanka Glamocanin<sup>3</sup>, Violeta Vasilevska-Nikodinovska<sup>4</sup>

**Abstract:**

*Osteosarcoma is an aggressive and malignant bone tumor most commonly appearing around the knee and shoulder in adolescents and young adults. The tumors can be generally divided into those arising inside the bone and those arising on the surface of the bone. The course of the disease and its prognosis can be different. Multidisciplinary approach in diagnosis and treatment is mandatory. Surgical resection with wide margins after neoadjuvant chemotherapy and adjuvant chemotherapy after surgery is a current standard of care. Applying modern chemotherapy regimen and performing limb-salvage surgery calls for responsible, trained and highly engaged medical staff. If the treatment and management principles of osteosarcoma are followed, limb-sparing with 60-80% survival rates can be achieved. Basic science is making continuous advance in molecular mechanisms and biologic pathways that may yield more specific agents, less-toxic drugs that will further improve overall long-term survival rates.*

**Keywords:** osteosarcoma, children, diagnosis, therapy

**Received:** 28/03/2010; **Accepted:** 29/03/2010

**Introduction**

Osteosarcoma is a relatively rare bone tumor characterized by production of osteoid and bone by malignant mesenchymal spindle cells. The incidence is 1-4 cases per 1.000.000 inhabitants with no significant association to an ethnic group or race. It is most frequently seen in the second decade of life (60% of the patients are under the age of 25), at skeletal sites with rapid bone turnover (distal femur, proximal tibia or proximal humerus) [1,2]. Most cases of osteosarcoma are sporadic, with very few associated to known inherited defects in cell cycle regulation. Even so, 70% of osteosarcoma tumor specimen demonstrate a chromosomal abnormality. Genetic predisposition commonly involves mutations in tumor - suppressor genes (resulting in uncontrolled cell proliferation) or in DNA helicases (forming double-strained DNA for replication and alteration of the genes) [3]. In spite of advances of basic science, etiology of the osteosarcoma remains unknown [4].

Depending on clinical, radiological, and histological features, osteosarcoma is classified into intramedullary subtypes (conventional, teleangiectatic, low-grade

Milan Samardziski<sup>1</sup>, George Zafiroski<sup>1</sup>, Vesna Janevska<sup>2</sup>, Olivera Muratovska<sup>3</sup>, Sofijanka Glamocanin<sup>3</sup>, Violeta Vasilevska-Nikodinovska<sup>4</sup>

<sup>1</sup> Department of Musculoskeletal Tumours, University Clinic for Orthopedic Surgery, Skopje, Macedonia

<sup>2</sup> Institute of Pathology, Faculty of Medicine, Skopje, Macedonia

<sup>3</sup> Department of Pediatric Oncology, University Pediatric Clinic, Skopje, Macedonia

<sup>4</sup> Radiology Department, Clinic for Surgery "St. Naum Ohridski", Skopje, Macedonia

**Corresponding Author: Milan Samardziski, MD, MSc**

Department of Musculoskeletal Tumours, University Clinic for Orthopedic Surgery University "Ss. Cyril and Methodius", Vodnjanska 17, 1000 Skopje, Republic of Macedonia.

Tel. /fax: + 389 2 3176 137

E-mail: milan\_samardziski@yahoo.com

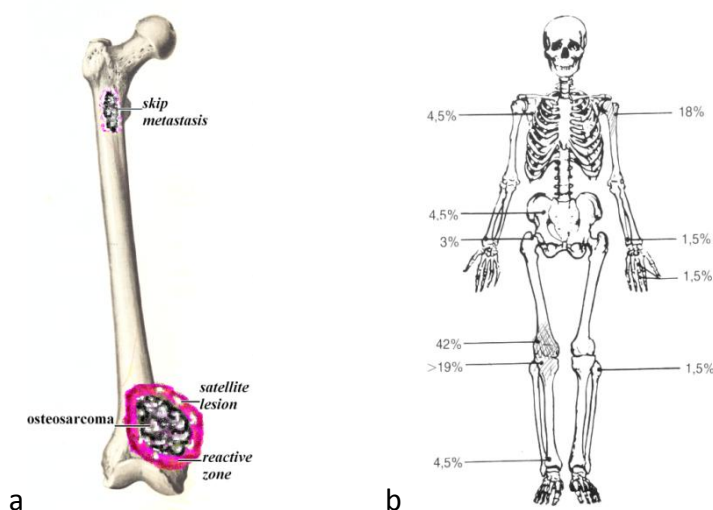
intramedullary and small-cell osteosarcoma) and surface types (parosteal, periosteal and high-grade surface osteosarcoma). More than 85% of osteosarcoma cases are categorized as primary osteosarcoma [5].

Before 1970, amputation was the primary treatment for high-grade osteosarcoma and 80% of the patients died of lung metastatic disease[6]. Dramatic changes over the past three decades have happened introducing neoadjuvant (preoperative) and adjuvant (postoperative) polychemotherapy protocols. This improves the ability to perform safe limb-sparing resection of the tumor in more than 90% of the osteosarcoma patients. Today, 60-80% of

the patients with extremity localized non metastatic osteosarcomas are long term survivors [7,8,9].

### Biologic behavior of osteosarcoma

An osteosarcoma grows as ball-like mass, mostly around the knee or shoulder. Penetrating tumor destroys the bony cortex and compresses the surrounding tissue and muscles, forming a pseudo capsular layer known as “reactive zone”. Fast growing tumor often forms nodules as micro extensions into the reactive zone, termed “satellites”. Therefore, radical or wide surgical margins must be achieved to ensure removal of all gross tumor [10].



**Figure 1. a)** Tumor growth pattern in osteosarcoma with radial growth at the origin, compressing surrounding tissue and forming a “reactive zone” as pseudo capsular layer. This zone contains “satellite” extensions of the tumor. To achieve radical excision the entire tumor mass (tumor + reactive zone) must be removed. Regional metastases within the same bone are referred as “skip metastases”.

**b)** Osteosarcoma can be seated anywhere on the skeleton, but predilection sites are distal femur, proximal tibia and proximal humerus (accounting for 70-80% of skeletal localizations).

The tumor may metastasize regionally (within the same extremity) or systemically (to the other organs, such as lungs). The spread of osteosarcoma cells almost always occurs haematogenously and very early. Locally or regionally tumor nodules grow outside the reactive zone, but within the same bone or a neighboring joint they are “skip” lesions (Figure 1a). Systemic metastases have high predilection for the lungs (in 80-85% of patients). Bones are second most common site of metastases and usually become involved after pulmonary metastases (second burst of metastases) [11]. Metastases are clinically detectable in approximately 20% of patients on initial presentation. Extremely rare sites of metastases include liver, lymph nodes, central nervous system, muscle or skin. With detected metastases prognosis worsens dramatically and

distant bony metastases represent the last stage of the disease and they are associated with poorest prognosis [12].

Depending on cytological or histopathological features of the tumor matrix or tumor cells and in course having rationale and particle approach to the therapy, osteosarcomas are divided into two groups. In the first group there are patients with *low-grade osteosarcoma* and surgery alone has the primary role of treatment. In the second group there are patients with *high-grade osteosarcoma*. In this group of patients “sandwich therapy” is strongly preferred (neoadjuvant chemotherapy - surgery - adjuvant chemotherapy) [13,14,15].

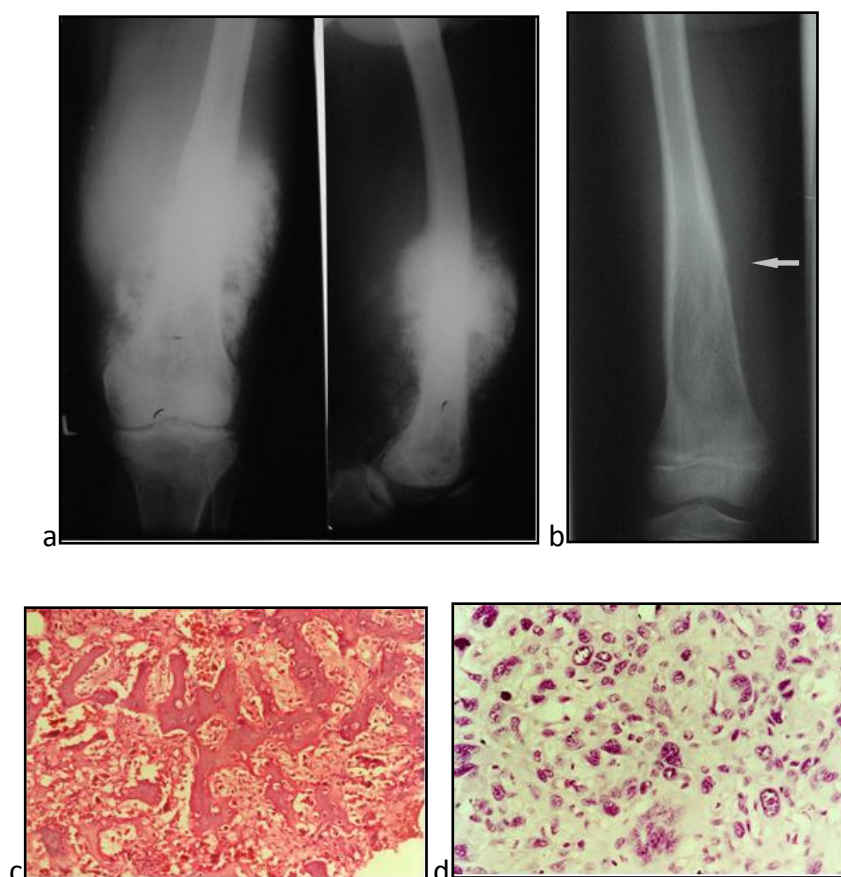
## Osteosarcoma subtypes

### Intramedullary osteosarcoma

*Conventional or "classic"* osteosarcoma is the most prevalent type in children and adolescents (continuing up to 80% of all cases). This type of osteosarcoma originates from intramedullary cavity and is typically high-grade (Figure 2a). Osteoblastic and/or osteolytic lesion with vast cortical destruction and various amount of soft tissue extension dominates on X-rays. Histopathologic examination demonstrates malignant mesenchymal cells, spindle to polyhedral in shape, with pleomorphic nuclei and occasional mitotic figures. Evidence of direct bone or osteoid production from the mesenchyma is crucial for diagnosis (Figure 2b, 2c). World Health Organization has further subcategorized high-grade intramedullary osteosarcoma since 2002, depending on the predominant extra cellular matrix on: *osteoblastic* (approximately 50% of cases), *chondroblastic* (25% of cases) or *fibroblastic* (25% of cases) [5].

*Teleangiectatic* osteosarcoma is a rare variant accounting for approximately 4% of all osteosarcoma cases in children and adolescents. Very often they are with pathological fracture on the first presentation. Eccentric osteolytic lesion on the metaphysis, with destruction and expansion of the eroded cortex dominates on radiography (Figure 2b). Histopathologic examination reveals malignant tumor with multiple dilated hemorrhagic sinuses with scarce amount of high-grade osteosarcoma cells and rare osteoid formation within the septa. This radiographic and histopathologic features resemble a lot to an aneurismal bone cyst and engrave the diagnosis [16].

*Low-grade* intramedullary osteosarcoma constitutes 1 to 2% of all osteosarcoma cases and generally affects patients in the third or fourth decade. Lesions most commonly affect the distal femur and proximal tibia, with relatively unaggressive radiographic appearance, resembling fibrous dysplasia ("fibrous dysplasia-like" osteosarcoma). Histopathological features confirm well-differentiated



**Figure 2.** a) Radiography of conventional intramedullary osteosarcoma (osteoblastic lesion with vast cortical destruction and soft tissue edema visible on x-rays); b) Radiography of teleangiectatic osteosarcoma with osteolytic lesion on the metaphysis of distal femur, destruction, expansion of the eroded cortex and Codman's periosteal reaction (arrow); c) Typical histopathological feature of osteosarcoma is osteoid formations directly from the mesenchyma; d) Atypical osteoid formation in high-grade anaplastic osteosarcoma is engraving the diagnosis.

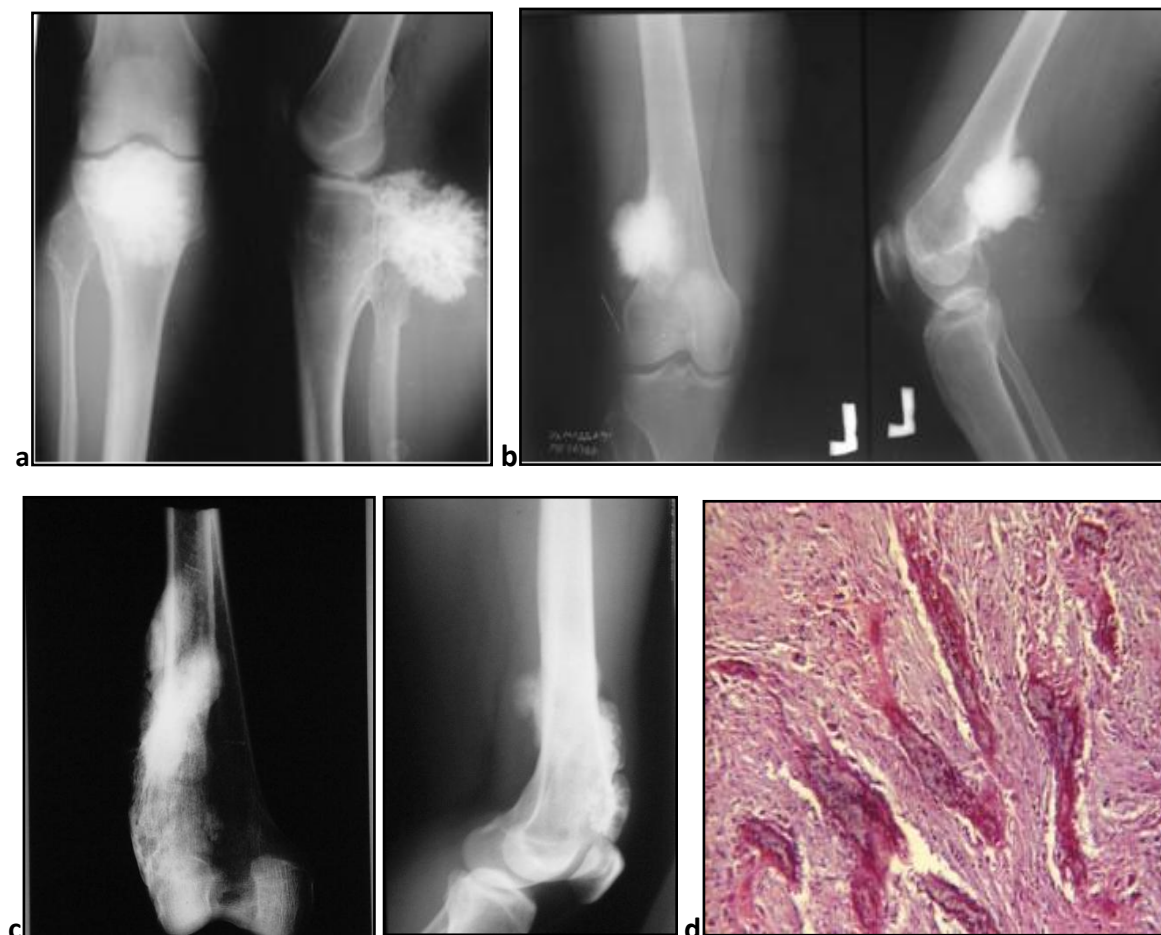
cells dispersed within woven microtrabeculae of bone and fibrous stroma. Small amount of osteoid, mitotic atypia and mitoses can also be seen [5]. *Small-cell* osteosarcoma is a rare variant constituting <1.5% of all osteosarcoma cases. This subtype is similar to the high-grade osteosarcoma, with the same site or age distribution and aggressive biologic behavior. The lesion is osteolytic with destruction of cortex and variable sclerosis. MRI reveals large spindle or circumferential tumor mass, similar to Ewing sarcoma. Small, round, malignant cells within an osteoid matrix make the histopathological diagnosis problematic. To differentiate this osteosarcoma from Ewing sarcoma, direct mesenchymal production of osteoid must be found, because this osteosarcoma is positive to CD 99 immunohistochemical stains [5].

A few osteosarcomas (less than 1% of all cases) have so many giant cells that can be mistaken for giant cell tumors. Cytological atypia of the mononuclear cells can be very

subtle and rare. It is important to remember the possibility of *giant cell-rich osteosarcoma* when giant cell tumor-like lesion occurs in unusual location and age, such as metaphysis in children [17].

### Surface osteosarcomas

*Parosteal osteosarcoma* arises on the outer surface of the long bone metaphysis, sparing the medullar canal (Figure 3a). The peak incidence is in the second and third decade, affecting more females than males.<sup>(10)</sup> Parosteal osteosarcoma is most commonly seen juxtacortical variety and constitutes 1 to 6% of all osteosarcoma cases. Radiographs classically shows densely ossified and lobulated mass on the posterior surface of the femur. Sometimes slow-growing tumors may encircle the bone.<sup>(18)</sup> Low-grade, well differentiated fibrous stroma with osseous components are regularly seen on the histopathologic examination.



**Figure 3.** a) Frontal and lateral radiography of the periosteal osteosarcoma of right distal femur; b) Radiography in frontal and lateral view of parosteal osteosarcoma of the proximal tibia; c) Frontal and lateral radiography of high-grade surface osteosarcoma on the right distal femur; d) Parosteal osteosarcoma showing parallel osteoid trabeculae embedded in fibroblastic stroma (HE, x100)



Parallel orientation of trabeculae sometimes with additional cartilaginous differentiation is very common (Figure 3d) [5,16].

*Periosteal osteosarcoma* constitutes 1 to 2% of all osteosarcoma cases and usually is more aggressive than the parosteal variant. Radiolucent lesion is located on the distal femur or proximal tibia, sparing the medullary cavity (Figure 3b). Codman triangle and “sunburst” periosteal reaction are common radiographic features. Histopathologic evaluation demonstrates intermediate-grade tumor, reach with cartilaginous matrix and rare osteoid fields [5,17].

*High-grade surface osteosarcoma* constitutes <1% of all osteosarcomas with predominant site around the knee. Radiographic analysis shows surface lesion with partial mineralization and tumor extension into surrounding soft tissues. In earlier stages of the disease destruction of the underlying cortex is absent, but with lesion advance affection of medullary cavity is possible (Fig. 3c). The histologic features are those of high-grade osteosarcoma, demonstrating spindle cells with atypia and varying amount of osteoid [5]. A high-grade surface osteosarcoma can not be differentiated from a conventional osteosarcoma on histologic findings alone [17,18].

### Clinical presentation

First symptoms in osteosarcoma patients are non specific, commonly with rapid onset, blunt pain of 2 to 4 months duration. Typical chronic “night-pain” usually disrupts sleep. On the examination a painful palpable or visible tumor mass is present. Adjacent joint may be affected to a different degree. Sudden increase in severity of the pain may correlate with tumor penetration in the bone cortex, periostium or pathologic fracture. Localized warmth, erythema and pathological vascularisation of the skin are not unusual [16]. Approximately 5-10% of undiagnosed osteosarcomas have pathological fractures of a bone on the first presentation [19]. Advanced stage of the disease includes: weight loss (usually more than 5-10 kg in a short period of time), general malaise and fever. There is ongoing dilemma of trauma etiology of the osteosarcoma. Many patients have a history of a minor injury, sprain of muscle pull during a play or participating in a sport. Lymph node metastasis is unusual in osteosarcoma patient [20]. Regional enlargement and tenderness of the adjacent lymph nodes to the involved site with pathological lesion are more suggestive of osteomyelitis and must be considered in the differential diagnosis [4,6,10,11,16]. The highest incidence of osteosarcoma is in patients 10 to 20 years of age. Approximately 20 to 30% of the patients

already have lung metastases on the first presentation [7,12,21,22].

### Laboratory tests

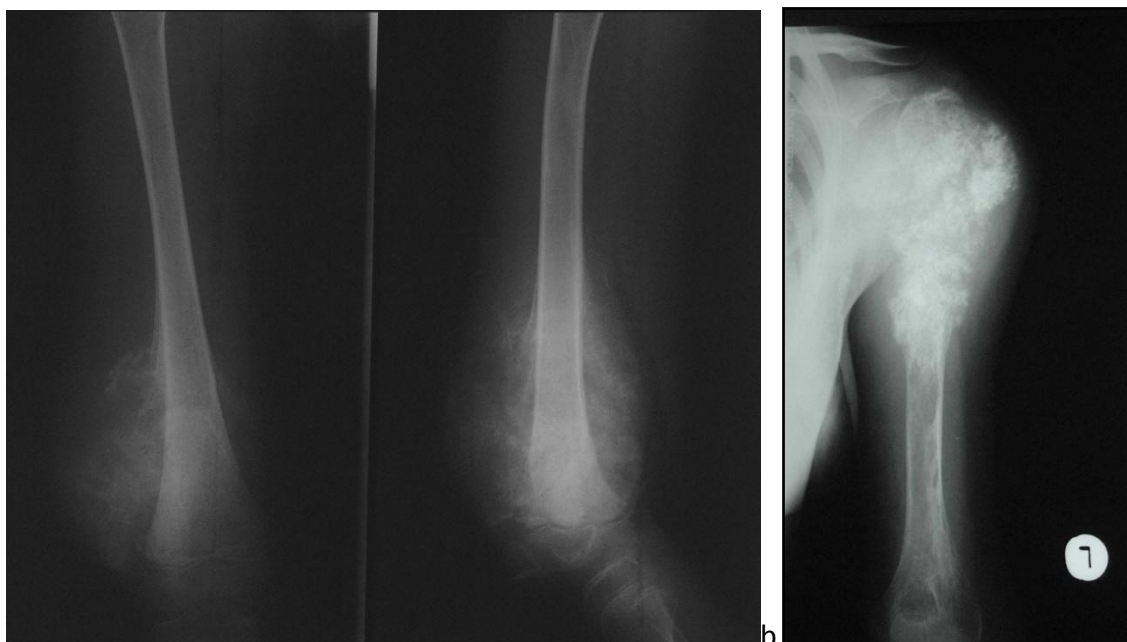There are no specific laboratory tests for osteosarcoma, yet. Once the suspicion of osteosarcoma is established, increased levels of alkaline phosphatase and lactate dehydrogenase are helpful for monitoring osteoblastic and osteoclastic activity. Some authors consider their elevated levels for a poorer outcome of the disease.<sup>(7, 13, 23)</sup> Basic laboratory tests to assess general health or organ function before initiation of chemotherapy are obligatory. These include complete blood count with erythrocyte sedimentation and differential, basic metabolic panel, renal and liver function values, and urine analysis. Before doxorubicin is added in chemotherapy, baseline cardiac function monitoring with electrocardiography is mandatory [16].

The so called “tumor markers” (as cell membrane, DNA or RNA receptors) did not approve as specific features for bone sarcoma as they did for carcinoma. Many of the following: CD 99, osteonectin, osteocalcin, cytokeratin, epithelial membrane antigen (EMA), S-100 protein, neurofilament protein (NF), CD 57, synaptophysin, neuron specific enolase (NSE), CD 31, CD 34, factor VII antigen and CD 68 are cytological and immunohistological markers used as additional help for differential diagnosis in histopathological laboratories [5,24].

### Imaging modalities for evaluation of osteosarcoma and detection of metastases

There are various radiological imaging techniques to achieve correct diagnosis and staging of osteosarcoma and to detect local recurrence or distant metastases. Most commonly used are: plain-film radiographs (as “golden” standard), Tc-99m bone scintigraphy, CT of the affected site or of the lungs and CT or conventional angiography. Positron emission tomography (PET-scan) and Thallium scintigraphy have been seldom used due to questionable results in evaluating early osteosarcoma metastases or due to high-cost of the techniques [16].

Plain-film radiographs in two orthogonal planes show mixed osteosclerotic and osteolytic tumor, affecting metaphysis of the bone (although primarily sclerotic or lytic osteosarcomas can occur). The lesion is ill defined of the surrounding bone, affecting and destructing the cortex, with typical small, irregular, confluent, cloud-like densities. If the cortex is completely eroded the lesion



**Figure 4. a) Radiograph in two orthogonal planes of typical mixed sclerotic end lytic osteosarcoma of the distal femur. Tumor has penetrated bone and formed soft tissue mass with Codman's triangles. b) Frontal plane radiograph of osteosarcoma sited on proximal humerus with small, confluent cloud-like densities, destructing the bone completely.**

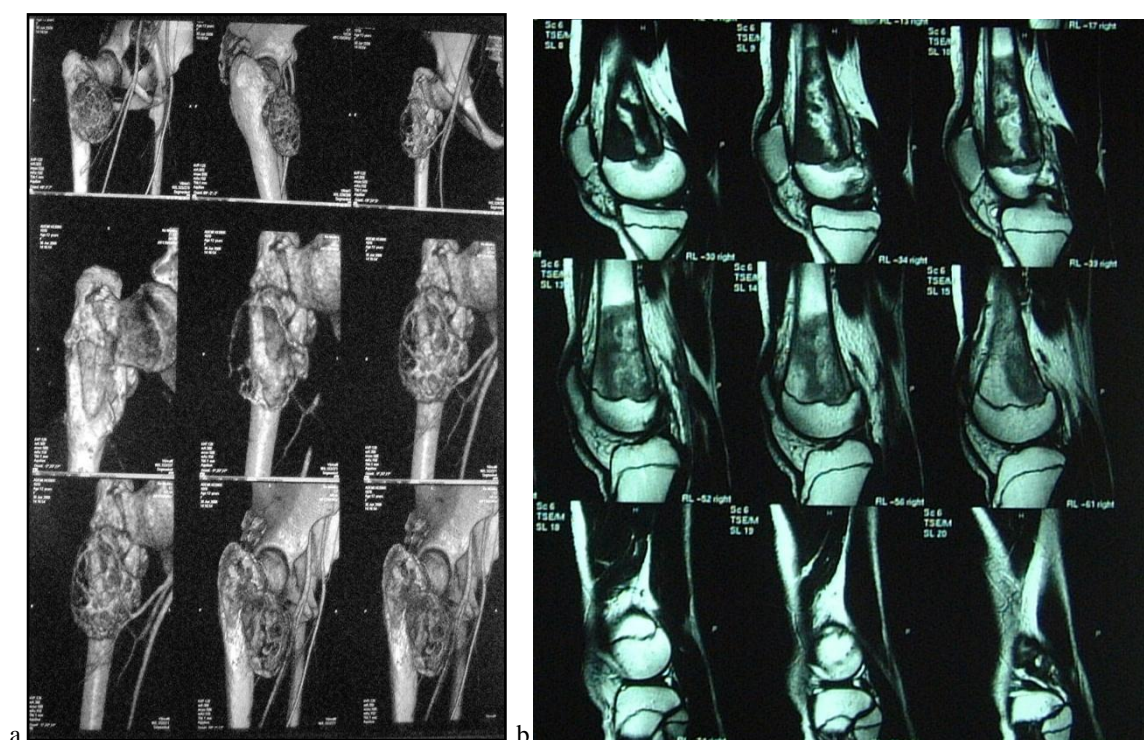
forms a soft tissue mass extruding from the bone into the surrounding tissue and may demonstrate ossification detectable on the radiographs (Fig. 4). The destruction may be so advanced that pathological fractures or complete bone erosion could be present (Fig. 4b). There is typical periosteal reaction due to aggressive expansion of the tumor, forming hairy, sun ray or velvet-like specula of neoplastic bone. In some cases "Codman's triangles" (arrows on Fig. 4a) are present [6,10,25]. Plain-film radiographs are used in correlation with bone scintigraphy and CT to detect local recurrence or bone and lung metastases. Additional data for diagnosis and decision-making process can be obtained using "computer assisted diagnosis" in analysis of the radiographs [25,26].

Computer tomography (CT) scanning of the affected extremity is useful in visualization of the intra and extraosseous extent of the tumor, especially when extensive necrosis and surrounding edema are present. In these cases CT may be superior to MRI. High-definition CT scans can obtain three dimensional view of the tumor in correlation with adjacent neurovascular structures, especially when contrast medium is used (Fig. 5a). All patients with osteosarcoma should undergo CT scanning of the chest and lungs for detection of pulmonary metastases in the

process of diagnosis and staging. After surgery has been performed in patients with nonmetastatic osteosarcoma, CT scans of the lung should be repeated every three to six months for two years [10].

With magnetic resonance imaging (MRI), standard T<sub>1</sub> and T<sub>2</sub>-weighted and fat-suppressed images are obtained to visualize the affected bone and surrounding tissue with osteosarcoma. Based on MRI studies, intraosseous and extraosseous extent of the tumor is visible as well as reactive zone and tissue edema (Fig. 5b). Neurovascular structures and especially neurovascular encasement can be determined that will help in the process of planning the definite method of treatment. (If encasement is present, amputation or wide resection with vascular reconstruction is obligatory).

Obtaining an MRI study at the time of surgical resection permits accurate planning of the osteotomy and gross tumor excision (together with the reactive zone) for achieving a wide surgical margin. Skip metastases on MRI are easily detectable in the same bone or in the adjacent joint and then most extensive resection is required.<sup>(26)</sup> MRI studies are inferior to high-definition CT scans for lung metastases detection.



**Figure 5. a)** CT scans of proximal femur osteosarcoma, with visualization of the superficial and deep femoral artery **b)** T<sub>2</sub>-weighted MRI image of distal femur osteosarcoma with no extrasosseus extension.

### Biopsy

In spite of the risk for tumor spreading, biopsy is the key step in the diagnosis and respectfully, the treatment of osteosarcoma. Improperly performed biopsy may start a life treating adventure for the patient. Most accurate planning is necessary to place the biopsy in the line of definite surgical approach for osteosarcoma resection. Specimen taken from the necrosis or only from reactive zone (around the osteosarcoma) may be non informative. Percutaneous large needle biopsy is sometimes preferable, because it is less invasive, with lower risk for skin necrosis, infection and pathological fracture. If no representative osteosarcoma tissue is obtained, another biopsy will increase the risk of complications or local spreading of the tumor. The best results are achieved when all the biopsy samples are obtained by the same orthopedic oncologist (surgeon) who will perform the definite surgical procedure [27,28].

### Staging

The American National Comprehensive Cancer Network recommends plain radiographs of the lesion and lungs, MRI scan of the extremity, CT scan of the tumor site and of the lungs, and radionuclide bone scan. Technetium Tc-99 methylene diphosphonate scintigraphy will reveal

increased metabolic activity at the site of the tumor but also at the site of distant skip or bone metastases. Thallium Tl 201 is potassium analog, actively transported by the sodium-potassium adenosine triphosphatase (ATP) pump. This radioisotope is well accumulated in benign or malignant tumors, reflecting tumor activity. Nevertheless, Thallium scanning is mostly used for monitoring the response to neoadjuvant chemotherapy (especially when MRI is not helpful).

Osteosarcoma can be divided into high-grade or low-grade variants, depending of cellularity, pleomorphism, anaplasia and number of mitoses. This fact and the data for presence or absence of osteosarcoma metastases will be enough to do the Enneking's surgical staging (Table 1) [29,30]. This staging system, first used by American Musculoskeletal Tumor Society and International Symposium on Limb-Salvage is widely accepted. An alternative system, established by American Joint Committee on Cancer, can be parallelly used with Enneking's one, concerning staging.

### Treatment

A multidisciplinary approach is obligatory in the diagnoses and treatment of osteosarcoma patients. To achieve high standards in treatment there is a need of specialized radiologists, pathologists, orthopedic and other surgeons



Table 1. Enneking's surgical staging system			
Stadium	Grade	Localisation	Metastases
IA	G <sub>1</sub> Low-grade	T <sub>1</sub> Intraosseus	M <sub>0</sub> No metastases
IB		T <sub>2</sub> Extraosseus	M <sub>0</sub> No metastases
IIA	G <sub>2</sub> High-grade	T <sub>1</sub> Intraosseus	M <sub>0</sub> No metastases
IIB		T <sub>2</sub> Extraosseus	M <sub>0</sub> No metastases
IIIA	G <sub>1-2</sub>	T <sub>1</sub> Intraosseus	M <sub>1</sub> With metastases
IIIB	G <sub>1-2</sub>	T <sub>2</sub> Extraosseus	M <sub>1</sub> With metastases

G<sub>1</sub>-Low-grade; G<sub>2</sub>-High-grade; T<sub>1</sub>-Intraosseus; T<sub>2</sub>-Extraosseus; M<sub>0</sub>-No metastases; M<sub>1</sub>-With metastases.

(specialized in oncology surgery), pediatric oncologists, specialized physical therapist and often social workers [7,9,10,16]. When proper chemotherapy and surgery protocol is followed, survival rates surpass 70% [13,14,15].

High-grade osteosarcoma patients without clinically detectable lung metastases are presumed to have micro metastases. For these patients treatment consists of preoperative (neoadjuvant) chemotherapy, wide or radical surgical resection and postoperative (adjuvant) chemotherapy i.e. "sandwich therapy

Parosteal osteosarcoma or low-grade intramedullary osteosarcoma patients are treated with wide or radical surgical resection alone. Chemotherapy is reserved only for cases with high-grade transformation.

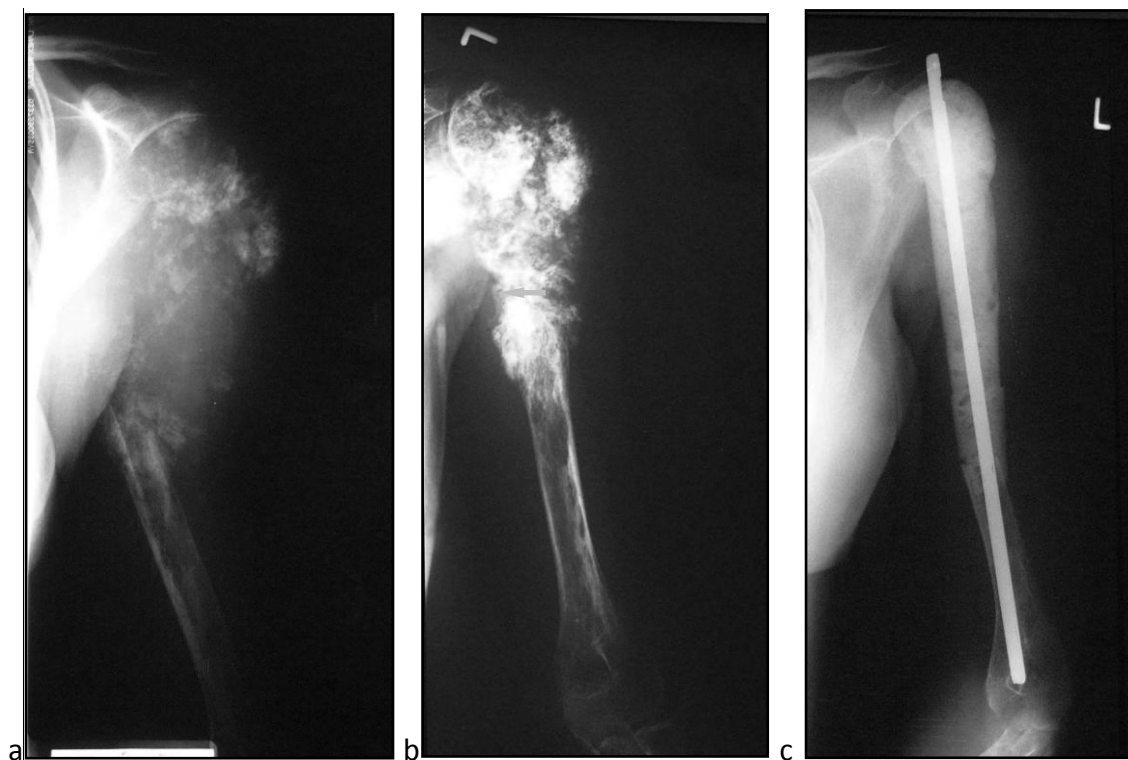
Periosteal osteosarcoma patients may be treated with preoperative (neoadjuvant) chemotherapy similar to that used for conventional osteosarcomas [10,16,18].

### Chemotherapy

Advances in polychemotherapy protocols in last 30 years have been responsible for improved survival rates and possibility for limb salvage surgery. Since the beginning of

the "odyssey" with Rosen and Jaffe, until now, chemotherapy has been shown to reduce number of pulmonary metastases or to delay their appearance, facilitating surgical treatment (Fig. 6) [10,31,32.]

Standard modern regimen include drugs that have been shown to be the most effective against osteosarcoma: doxorubicin (Adriamycin), cisplatin (Platinol) ifosfamide (Ifex) with mesna (Mesnex) and high-dose methotrexate (Rheumatrex) with Leucovorin calcium rescue. Most standard protocols use doxorubicin and cisplatin with or without high-dose methotrexate for both neoadjuvant and adjuvant chemotherapy [9,10,13,14]. The postoperative (adjuvant) chemotherapy is mostly dependent on the extent of tumor necrosis evaluated after surgical removal. The postoperative chemotherapy regimen is typically the same as preoperative regimen when tumor necrosis is found to be  $\geq 90\%$  at the time of surgery. "Poor responders" to preoperative chemotherapy, defined as those with  $<90\%$  tumor necrosis at the time of surgery, may benefit from postoperative chemotherapy. In these patients a salvage therapeutic regime is attempted with an increased dose of chemotherapy, an increased length of chemotherapy, or change in chemotherapeutic agent. Recent trials have incorporated ifosfamide after conventional chemotherapeutic drugs to improve patient survival rates [12,13,14,16,31,32].



**Figure 6. a) Fifteen years old female osteosarcoma patient with pathological fracture of the left proximal humerus at the first presentation. The patient had preoperative (neoadjuvant) chemotherapy with Swedish Sarcoma Protocol XIV. b) Excellent respond (>97% tumor necrosis) after neoadjuvant chemotherapy (arrow shows the site of the pathological fracture). c) Radiograph of the humerus after wide resection of the osteosarcoma, and first stage reconstruction of the bone with intramedullary rod and bone cement.**

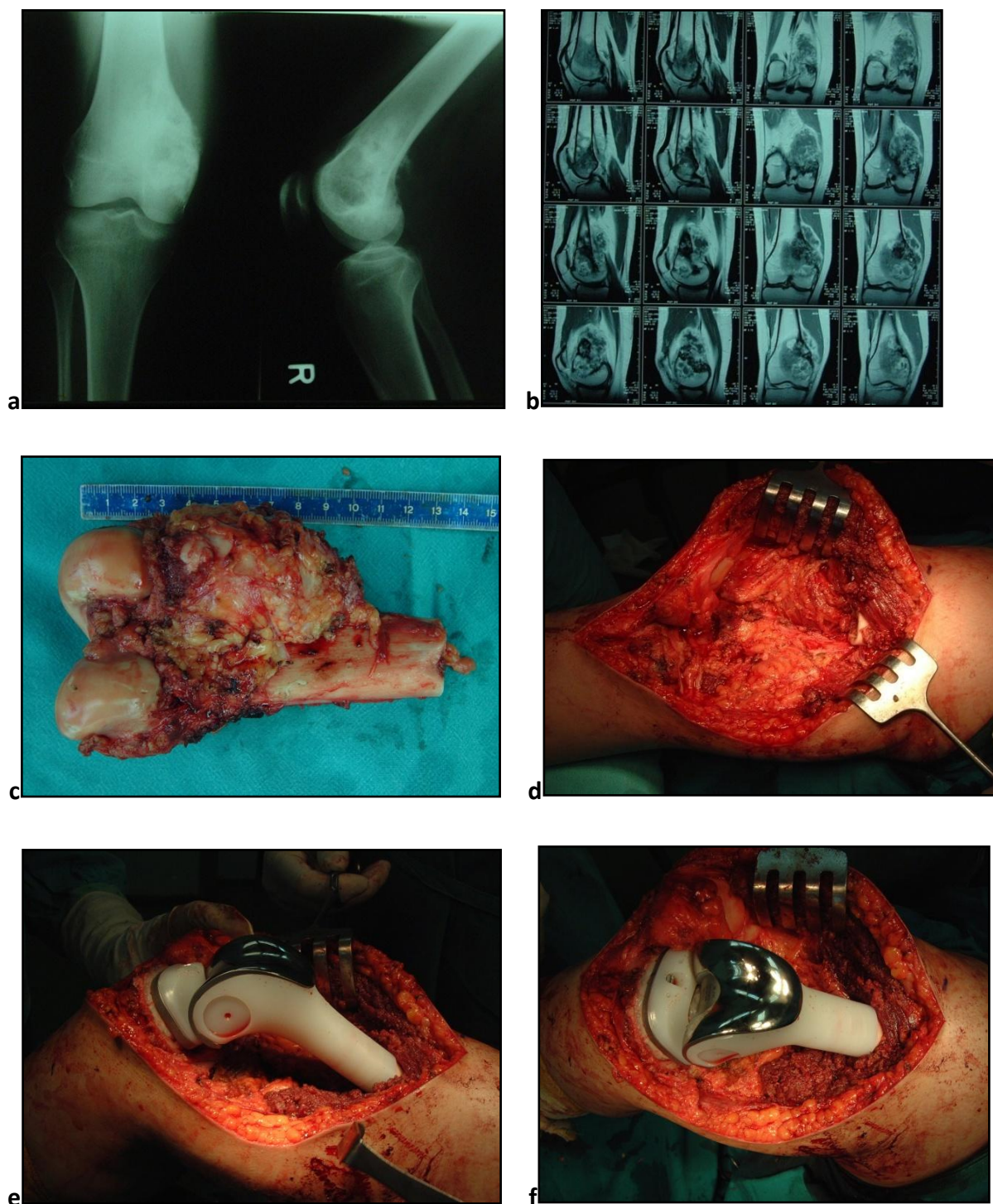
### Surgery

The two primary surgical options are tumor resection with limb-salvage, and amputation. Surgical margins in excision should encompass resection of tumor, pseudo capsule, and a cuff of normal tissue en block. The best results are published when multidisciplinary approach in diagnosis and treatment are encountered. Meticulous preoperative planning before the biopsy and definite surgery will ensure better results [27,28]. Prior to the emergence of limb-salvage surgery in the 1970s, amputation of the affected limb was considered the definite surgical intervention. Amputation remains the indicated treatment when disease-free margins resection leaves nonfunctional limb. The limb-salvage surgery for osteosarcoma patients is attributable to the use of preoperative chemotherapy and to advancement in musculoskeletal imaging, prosthetic implant design and surgical technique (Fig. 7). Today limb sparing surgery is possible for >85% of extremity osteosarcomas [8,16,33,34,35].

Surgical treatment has to be planned having in consideration four basic principles of limb-salvage procedures: 1) local

recurrence should be no greater and survival no worse than by amputation; 2) the procedure, or treatment of its complications, should not delay adjuvant therapy; 3) reconstruction should be enduring and not associated with large number of local complications requiring secondary procedures and frequent hospitalizations; 4) function of the limb should approach that obtained by amputation, although body image, patients preference and life style may influence the decision [8,9,36].

There are few relative contraindications to be taken in consideration for limb-salvage surgery: wrong site or ill-done biopsy, massive encasement of neurovascular bundles, extensive tumour involvement in soft tissue, muscles of skin, complex or complicated (i.e. with infection) pathological fractures, expected inequalities of the extremities more than 8 cm, and exceptionally poor effect of the neoadjuvant chemotherapy [16,37,38]. In the process of decision making for limb-salvage surgery versus amputation the “rule of three” can be very helpful. For extremity survival bone (1), nerves (2), blood vessels (3), and muscle and skin (4) are necessary to be preserved.



**Figure 7. a) radiography of high-grade chondroblastic osteosarcoma of right distal femur in a girl of 17; b) anterior and lateral MRI view of the lesion; c) photo of the resected tumor; d) tumor site ready for reconstruction; e, f) reconstructed right femur and knee (Link modular endoprsthesis).**



If osteosarcoma involves one or two of former, limb preserving is possible. If any three of the former are involved, amputation must be taken in consideration [7,33].

When “negative” tumour margins are obtained, a large skeletal defect is often present, requiring reconstruction of the bone, muscles, other soft tissues, and the skin. Patients’ age, tumour location and extent of resection, narrow the list of appropriate surgical alternatives. The extent of the disease, anatomical location of the tumour and the patient’s age and psychological profile define the most appropriate surgical procedures. Several options for limb-sparing are available: resection arthrodesis and other similar techniques with special indications (Fig. 6c), modular (Fig. 7) or special expanding endoprostheses, cortico-spongious or bulk auto graft. In less developed countries, with lower technical and financial support of the medical system, reconstruction of the defects with biological materials is preferable [39]. For the patients who can not satisfy the principles of limb preservation, ablative surgery has to be taken into consideration. For these patients disarticulation of the hip, or shoulder girdle, rotationplasty, femoral or below knee, humeral or other amputations are far more appropriate [16,35,36,37].

The current recommendation for detectable metastases is to excise as many lesions as technically feasible following surgical treatment of the primary tumor. The survival rate for patients can be as high as 75% when both the primary tumor and solitary lung metastasis are adequately resected [12,19,21,22].

Amputation remains the indicated treatment when resection to disease-free margins leaves a nonfunctional limb. The rate of surgical site recurrence is 4% to 6% for both limb-salvage and amputations. Complications following limb-salvage reconstructions include wound complications, infections, mechanical construct failure, and nonunion. The reported incidence of complications with limb-salvage surgical techniques is 4% to 38% [16,26,33,34,37].

### Treatment possibilities in future

Basic science is making continuous advance in molecular mechanisms and biologic pathways that may yield more specific agents, less-toxic drugs that will further improve survival rates.

Inhibition of tyrosine kinase signalling is known to regulate a number of cell growth, cell proliferation, angiogenesis, and apoptosis and is an area of current interest [40].

Liposomal muramyl tripeptide phosphatidylethanolamine (L-MTP-PE) is a promising drug in clinical trial that

functions to stimulate the formation of tumoricidal macrophages [41].

Intra-arterial administration of cisplatin has been investigated for achieving improved histologic response following chemotherapy. Since the pioneer attempts to administrate intra-arterial cisplatin from the 1980’s, a major advance in imaging techniques improves the techniques and makes it easier and safer.<sup>(41)</sup> Reported studies demonstrate an increase in long-term survival up to 93%, thus a consensus on the routine use of intra-arterial chemotherapy does not exist [43].

### Postoperative follow-up

After chemotherapy has been completed, the patient should be closely followed by the orthopedic oncology surgeon and the medical oncologist. The patient should be monitored for local recurrence, distant or systemic metastases and complications related to reconstruction of the extremity.

CT scanning of the chest, plain film radiographs of the reconstructed extremity and meticulous physical examinations are recommended every three months for the first two years and at least every six months from the second through the fifth year, and subsequently on a yearly basis. Also, annual bone scintigraphy is mandatory for the first two years after completion of the chemotherapy.

### Prognosis

Prior to the introduction of chemotherapy, when amputation was the primary treatment for patients with osteosarcoma the predicted long-term survival was 15-20%. Dismal survival rates were presumably attributable to pulmonary metastatic disease, whether clinically obvious or occult [44]. Survival rates dramatically increased during 1970s and 1980s with the pioneer work of Rosen and Jaffe [31,32].

Currently, long-term survival rates are 60% to 70% for patients with localized osteosarcoma and for extremity localized up to 80%. Despite the use of modern chemotherapy the 10-year survival rates decline significantly to 20% in patients with clinically detectable metastases [16]. Most of the patients ultimately die because of respiratory failure caused by the metastatic burden [21,22]. Excluding high-grade surface osteosarcoma, which has similar prognosis to that of conventional osteosarcoma, the surface (parosteal and periosteal) osteosarcoma variants have the best prognosis of all. The 10-year survival rates for this patients is up to 85% [18,45]. The site of the lesion has prognostic importance. Best survival rates are expected in patients with appendicular localization of the osteosarcoma.



Central localization (as pelvis, ribs and vertebrae) are less common sites of osteosarcoma, but with poorest prognosis. Osteosarcoma of the jaws is associated with an especially good prognosis, whereas some osteosarcoma involving the skull has a very poor prognosis [17]. Badly planned and ill preformed biopsy can complicate the final surgery and may decrease survival rates [7,27,28].

Poor prognostic factors for patients with osteosarcoma include metastases at first presentation, extremely large primary tumor, increased alkaline phosphatase and lactate dehydrogenase levels, poor response to neoadjuvant chemotherapy, discontinuous tumor of bone, pathologic fractures and lymph node involvement [17,45,46].

Despite current surgical and chemotherapeutic treatment regimens, 30% to 40% of osteosarcoma patients experience relapse within 3 years of treatment. Pulmonary recurrence is most common secondary to micrometastatic disease [16]. Regardless of poor prognosis, repeated tumor excisions can be performed (of primary site or metastatic one), because many studies have shown improved survival rates [16,21,22]. The role of "second-line" chemotherapy regimen remains controversial because no standard regimen exists for recurrence.

### Summary

With advances of chemotherapy, radiographic imaging, and reconstructive surgery, most patients with osteosarcoma can now be offered limb-sparing treatment. Multidisciplinary approach in diagnosis and treatment is mandatory. Surgical resection with wide margins after neoadjuvant and adjuvant chemotherapy after surgery is a current standard of care [10]. Osteoarticular allografts, modular prostheses, or composites of these two approaches form the basis for most current reconstructions. However, amputations still play an important role and offers a standard to which other approaches must be compared [8].

Basic science is making continuous advance in molecular mechanisms and biologic pathways that may yield more specific agents, and less-toxic drugs that will further improve survival rates [3].

### Acknowledgement

Special thanks to Mrs. Maria Tanevska-Pulios for English language editing of the paper.

### REFERENCES

1. Larson SE, Lorentzon R. The incidence of malignant primary bone tumors in relation to age, sex and site. *J Bone Joint Surg*, 1974; 56-B:534-540.
2. Dorfman HD, Czerniak B. Bone cancers. *Cancer*; 1995; 75:203-210.
3. Hayden JB, Hoang BH. Osteosarcoma: Basic science and clinical implications. *Orthop Clin North Am*, 2006; 37:1-7.
4. Prichard DJ, Finkel MP. The Etiology of Osteosarcoma. *Clin Orthop and Rel Res*. 1975; 111:14-27.
5. Fletcher CDM, Unni KK, Mertens F. Pathology and Genetics of Tumours of Soft Tissue and Bone. (WHO Classification of Bone Tumours). Lyon: *International Agency for Research on Cancer Press* 2002; pg. 227-32, 264-85.
6. Gross WS. Sarcoma of Long Bones: Based upon a study of One Hundred and Sixty-five Cases. *Clin Orthop and Rel Res*. 1975; 111:5-13.
7. Bacci G, Picci P. Analysis of Factors Influencing Treatment Options in Osteosarcoma. Review. *Forum*, 1994; 4: 52-64.
8. Di Caprio MR, Friedlander GE. Malignant Bone Tumours: Limb Sparing Versus Amputation. *J Am Acad Ort Surg*. 2003; 11: 125-9.
9. Samardziski M, Zafiroski G, Tolevska, C, Zafirova-Ivanovska B, Kostadinova-Kunovska S, Kalicanin-Markovska M. Limb-sparing in patients with non-metastatic high-grade osteosarcoma. *J. BUON*, 2009; 14: 63-69.
10. Wittig JC, Bickels J, Priebat D, Jelinek J, Kellar-Graney K, Shmookler B, Malawer M. Osteosarcoma: A Multidisciplinary Approach to Diagnosis and Treatment. *Am Fam Physician*. 2002; 65:1123-32. (also seen on: www.aafp/afp).
11. Enneking WF. Osteosarcoma (editorial comment). *Clin. Orthop and Rel Researc*, 1975; 2-4.
12. Bacci G, Rocca M, Salone M, et all. High-grade osteosarcoma of the extremities with lung metastases at presentation: Treatment with neoadjuvant chemotherapy and simultaneous resection of primary and metastatic lesions. *J Surg Oncol*, 2008; 98:415-420.
13. Bacci G, Picci P, Ferarri S, Sangiorgi L. et all. Neoadjuvant chemotherapy for the treatment of osteosarcomas of the extremities: excellent response of the primary tumour to preoperative treatment with methotrexate, cisplatin, adriamycin and ifosfamide. Preliminary results. *Chir Organi Mov* 1995; 80:1-10.

14. Bruland OS. and Phil A. On the Current Management of Osteosarcoma. A Critical Evaluation and Proposal for a Modified Treatment Strategy. *Eur J Cancer* 1997; 33: 1725-31.
15. Sæter G, Bruland ØS, Folerras G, Boysen M, Høie J. Extremity and non-extremity high-grade osteosarcoma. *Acta Oncol.* 1996; 35: 129-34.
16. Messerschmitt PJ, Garcia RM, Abdul-Karim FW, Greenfield EM, Getty PJ. Osteosarcoma. *J Am Acad Ort Surg.* 2009; 17: 515-27.
17. Unni KK. Osteosarcoma of bone. *J Orthop Sci.* 1998; 3:287-294.
18. Samardziski M, Zafiroski G, Tolevska C, Kostadinova-Kunovska S, Vasilevska V, Parosteal Osteosarcoma. *Bratisl Lek Listy.* 2009; 110: 240-4.
19. Scully SP, Ghert MA, Zurakowski D, Thompson RC, Gebhardt MC. Pathologic fractures in osteosarcoma: Prognostic importance and treatment implications. *J Bone Joint Surg Am.* 2002; 84:49-57.
20. Ilic D, Zafiroski G, Simova N, Zisovski N, Glamocanin S, Janevska V, Tolevska C, Vaskova O, Samardziski M. Detection of lymph node metastasis form osteosarcoma with 99mTc-MTP scintigraphy. Case report. *Radiol Oncol* 1999; 33: 23-6.
21. Yonemoto T, Tatzaki Sh, Ishii T, Satoh T, Kimura H, Iwai N. Prognosis of Osteosarcoma with Pulmonary Metastases at Initial Presentation is not dismal. *Clin Orth Rel Res.* 1997; 349:194-9.
22. Blasier D, Mayba I, Ferguson C, DeSa D, Bishop A, Letts M. Metastatic Osteosarcoma and Multiple Resections. A case report. *J Bone Joint Surg.* 1986; 68-B: 748-750.
23. Takeshita H, Gebhardt M, Springfield D, Kusuzaki K, Mankin H. Experimental Models for Study of Drug Resistance in Osteosarcoma: P-Glycoprotein-Positive, Murine Osteosarcoma Cell Lines. *J Bone Joint Surg Am.* 1996; 78: 366-75.
24. Carlos A, Muro-Cacho H. The Role of Immunohistochemistry in the Diagnosis of Primary Tumours of the Bone. *Patholo Update Cancer Control. JMCC.* 1998; 5: 561-9.
25. Lodwick GS, Haun CL, Smith WE, Keller RF, Robertson ED. Computer Diagnosis of Primary Bone Tumours, A Preliminary Report, *J Bone Joint Surg Am.* 1963; 80: 273-5.
26. Samardziski M, Zafiroski G, Janevska V, Miladinova D, Popeska Z. Computer assisted diagnosis of benign bone tumors. *Radiol Oncol* 2004; 38: 165-9.
27. Ghert M, Colterjohn N, Manfrini M. The Use of Free Vascularised Fibular Grafts in Skeletal Reconstructions for Bone Tumors in Children. *J Am Acad Ort Surg.* 2007; 15:577-87.
28. Campanacci M. Errors in the Diagnosis and Treatment of the Musculoskeletal Tumors: What must not be done. *Chir Organi Mov.* 1999; 84: 1-17.
29. Mankin HJ, Lange AT, Spanier SS. The Hazards of Biopsy in Patients with Malignant Primary Bone and Soft-Tissue Tumours. *J Bone Joint Surg Am.* 1982; 64: 1121-7.
30. Enneking WF, Spanier SS, Goodman MA. A surgical staging of musculoskeletal sarcomas. *J Bone Joint Surg (Am).* 1980; 62:1027-30.
31. Enneking WF. A system of staging musculoskeletal neoplasms. *Clin Orthop.* 1986; 204:9-24.
32. Rosen G. Pre-operative (neo-adjuvant) chemotherapy for osteogenic sarcoma: a ten year experience. *Orthopedics.* 1985; 8:659.
33. Jaffe N. Osteogenic sarcoma: State of the art with high-dose methotrexate treatment. *Clin Orthop.* 1976; 120:95-102.
34. Nagarajan R, Neglia PJ, Clohisy DR, Robinson LL. Limb Salvage and Amputation in Survivors of Paediatric Lower-Extremity Bone Tumours: What are Long Term Implications. *J Clin Oncology.* 2002; 22: 4493-501.
35. Ghert M, Colterjohn N, Manfrini M. The use of free Vascularised grafts in skeletal reconstruction for bone tumors in children. *J Am Acad Orthop Surg.* 2007; 15: 577-587.
36. Kotz R, Dominkus M, Zettl T et al. Advances in bone tumor treatment in 30 years with respect to survival and limb salvage. A single institution experience. *Intern Othoped.* 2002; 26: 197-206.
37. Capanna R, Biagini R, Rugeri P, Bettelli G, Casadei R, Campanacci M. Temporary resection-arthrodesis of the knee using intramedullary rod and bone cement. *Inter Othoped.* 1989; 13: 253-8.
38. González-Heranz P, Burgos-Flores J, Ocete-Guzmán J.G, López-Mondejar J. A, Amaya S. The Management of Limb-Length Discrepancies in Children after Treatment of Osteosarcoma and Ewing's Sarcoma. *J Ped Orthop.* 1995; 15:561-5.
39. Zafiroski G, Kamnar J, Grkova V, et al. Childrens orthopedics. *Skopje:Kultura,* 2003. p. 102-11.
40. Gosheger G, Gebert C, Ahrens H, Streitbueger A, Winkelmann W, Harges J. Endoprosthetic reconstruction in 250 patients with sarcoma. *Clin Orthop Rel Res* 2006; 450:164-171.
41. Messerschmitt PJ, Retew AN, Brookover RE, Garcia RM, Getty PJ, Greenfield EM. Specific tyrosine kinase inhibition regulate human osteosarcoma cells in vitro. *Clin Orthop Rel Res.*

- 2008; 466:2168-75.
42. Meyers PA, Schwartz CL, Krailo M, et al. Osteosarcoma: The addition of muramyl tripeptide to chemotherapy improves overall survival. A report from Children's Oncology Group. *J Clin Oncol.* 2008; 26:633-8.
  43. Jaffe N, Raymond AK, Ayala A, et al. Analysis of efficacy of the intra-arterial cis-Diammine-dichloroplatinum-II and high dose methotrexate with citrovorum factor rescue in the treatment of primary osteosarcoma. *Reg Cancer Treat.* 1989; 2:157-63.
  44. Bacci G, Ferrari S, Tienghi A et al. A comparison of methods of loco-regional chemotherapy combined with systemic chemotherapy as neo-adjuvant treatment of osteosarcoma of the extremity. *Eur J Surg Oncol.* 2001; 27:98-104.
  45. Longhi A, Errani C, DE Paolis M, Mercuri M, Bacci G. Primary bone osteosarcoma in the pediatric age: State of the art. *Cancer Treat Rev.* 2006; 32:423-36.
  46. Broström LA. On the Natural History of Osteosarcoma. Aspects on diagnosis, prognosis and endocrinology. *Act Orthop Scan. Supl.* 1979; 183:9-38.
  47. Pochanugool L, Subhadharaphandou T, Dhanachai M, and all. Prognostic Factors Among 130 Patients With Osteosarcoma. *Clin Orthop Rel Res.* 1997; 345:206-14.