

# Journal of Pediatric Sciences

## Association of antenatal Bartter syndrome type 1 and Becker's muscular dystrophy

*Albina Tummolo, Gabriella Aceto, Giovanni Francioso, Alberto Bettinelli,  
Silvana Tedeschi, Rosa Penza*

Journal of Pediatric Sciences; 2010; 4; e38

**How to cite this article:**

**Tummolo A., Aceto G., Francioso G., Bettinelli A., Tedeschi S., Penza R. Association of antenatal Bartter syndrome type 1 and Becker's muscular dystrophy. Journal of Pediatric Sciences 2010;4:e38**

## CASE REPORT

## Association of antenatal Bartter syndrome type 1 and Becker's muscular dystrophy

Albina Tummolo<sup>1</sup>, Gabriella Aceto<sup>1</sup>, Giovanni Francioso<sup>1</sup>, Alberto Bettinelli<sup>2</sup>,  
Silvana Tedeschi<sup>3</sup>, Rosa Penza<sup>1</sup>

### Abstract:

Bartter syndrome (BS) is a heterogeneous ion channel disorder characterized by hypokalemia, hypochloremia, metabolic alkalosis and hyperreninemia with normal blood pressure. We report a case of a boy who was referred to our clinic with a medical history suggestive of antenatal BS. The molecular analysis confirmed the clinical suspicion of BS (type I), although his potassium serum concentration was always in normal range (median 4.1 mmol/l, range 3.7 – 4.7), requiring only a very low dose of indomethacin as treatment protocol. Over the follow-up period he presented myotonia of the limbs and bilateral equinism and was admitted for severe weakness and intense muscular cramps involving the lower extremities. Laboratory tests showed creatine kinase (CK) 27295 U/l, and normal serum potassium (4.3 mmol/l). A hypokalemic rhabdomyolysis could be excluded. The DNA analysis confirmed the hypothesis of Becker's Muscular Dystrophy (BMD). The coexistence of a muscular disorder can alter the biochemical features of BS by causing normal serum potassium concentration and normokalemic rhabdomyolysis. This unusual biochemical pattern of BS type I should be properly investigated to avoid mismanagement and prevent severe complications.

**Key words:** Bartter syndrome, Becker's muscular dystrophy, hypokalemia, rhabdomyolysis

**Received:** 29/06/2010; **Accepted:** 13/07/2010

### Introduction

Bartter syndrome (BS) is a heterogeneous disorder characterized by defects in sodium and chloride re-absorption, which results in excessive urinary loss of sodium, chloride and potassium. The overall features of this class of disorders include: hypokalemia, hypochloremia, metabolic alkalosis and hyperreninemia with normal blood pressure [1].

BS type 1, also identified as antenatal or neonatal BS, is caused by mutations in the SLC12A1 gene encoding for a sodium-potassium-chloride cotransporter (NKCC2). In antenatal BS, abnormalities begin in utero with fetal polyuria resulting in polyhydramnios and premature delivery. Patients affected usually present hypokalemia and manifest a marked hypercalciuria and consequently the development of nephrocalcinosis [2].

Although the above biochemical features should be distinctive for the diagnosis of BS type I, a noteworthy phenotypic variability of both clinical and biochemical components of this

Albina Tummolo<sup>1</sup>, Gabriella Aceto<sup>1</sup>,  
Giovanni Francioso<sup>1</sup>, Alberto Bettinelli<sup>2</sup>,  
Silvana Tedeschi<sup>3</sup>, Rosa Penza<sup>1</sup>

<sup>1</sup>Department of Paediatric Nephrology, University of Bari, Italy  
<sup>2</sup>Department of Paediatrics, San Leopoldo  
<sup>3</sup>Laboratory of Medical Genetics, Istituti Clinici di Perfezionamento, Milano, Italy Mandic Hospital, Merate-Lecco, Italy

**Corresponding Author:** Albina Tummolo, MD

Department of Paediatric Nephrology, University of Bari, Italy. Tel:+39-080-559-2008, Fax: +39-080-559-2008  
E-mail: a.tummolo@bioetaev.uniba.it

disorder have been described. Only hypokalemia appears constantly reported, whereas other laboratory signs may be absent [2].

The phenotype aspect of this disorder can be also influenced by the presence of other conditions,

some of which have been reported in association with BS without a fully understandable genetic pattern [3-5].

We report a case of a boy who has been followed-up since infancy for BS type I, in spite of normal serum potassium concentrations and was diagnosed with Becker's Muscular Dystrophy (BMD) during his follow-up. This case describes an atypical biochemical pattern of BS when it is associated to a condition leading to muscle necrosis.

### Case Report

A Caucasian boy was referred to our clinic at the age of three months because of polyuria, severe volume depletion, hyperuricemia and neonatal seizures. Presence of severe polyhydramnios was detected before birth. He was born at 31 weeks of pregnancy with a body weight of 1850g from nonconsanguineous parents. On admission to our unit he presented arterial blood pressure in normal range (75th percentile for age and sex). Laboratory findings disclosed a tendency towards metabolic alkalosis (pH: 7.57, bicarbonate: 27

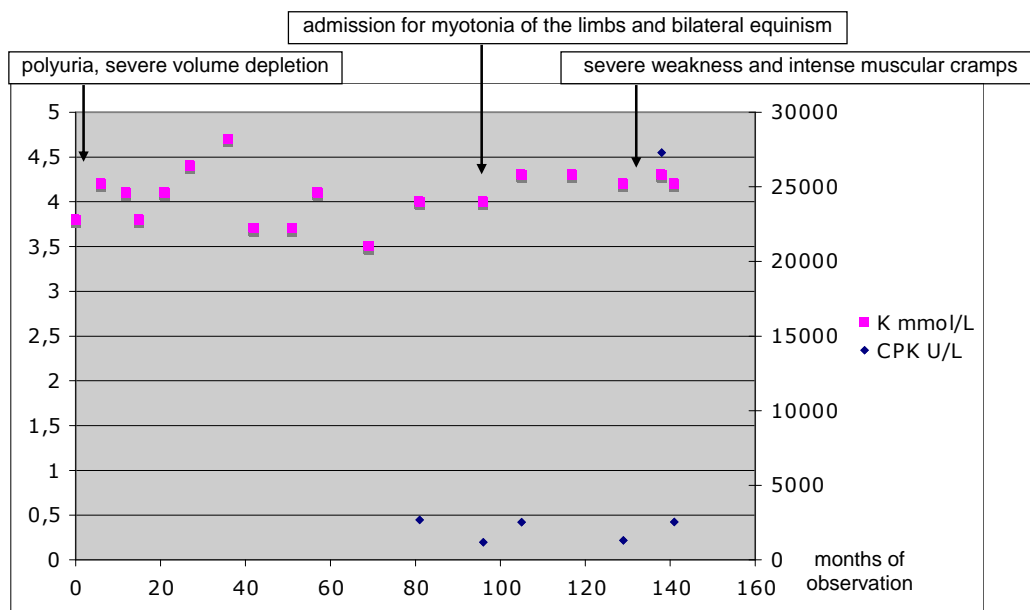
mmol/L), normal serum sodium (143 mmol/l), potassium (3.8 mmol/l), chloride (103 mmol/l) and creatinine (60  $\mu$ mol/l) and an abnormal value of uricemia (8.8 mg/dl), urinary calcium / creatinine ratio (0.65 mg/mg, reference < 0.40), plasma renin activity (> 50 ng/ml per hour; reference < 2.5 ng/ml/h) and plasma aldosterone (430 ng/dl; reference < 201 ng/dl). Renal ultrasound detected bilateral nephrocalcinosis.

In the hypothesis of a Bartter syndrome, a blood sample was taken for genomic DNA isolation. The sequence analysis of all the exon sequences and exon-intron boundaries of the SLC12A1 gene revealed a frameshift and a missense mutation in exons 21 and 26 respectively (Figure 1). The c.2731delGA, leading to a premature stop codon, and the p.G1089E, in a highly conserved residue, were consistent with the diagnosis of BS type I.

On the basis of the clinical and molecular findings, the child was managed symptomatically with a very low potassium supplementation (1mEq/Kg/day) in addition to indomethacin (2 mg/Kg/day) and allopurinol (3mg/kg/day).



Figure 1- Sequence analysis of the SLC12A1 exon 21 and exon 26 in the patient and in the wild type



**Figure 2 – Main laboratory and clinical features overview**

On follow-up the child showed significant clinical improvement, requiring only a very low dose of indomethacin (0.2 mg/kg/day), although his weight and height always remained below the third percentile for age and sex. Since the age of 8 years, he began to manifest myotonia of the limbs and bilateral equinism, although fine motor milestones remained always normal for age.

At the age of 12 years, he was admitted for severe weakness and intense muscular cramps involving the lower extremities. The medical history revealed an intense muscular activity in concomitance with the boy's summer holidays. On physical examination a weakness pattern limited to the legs' muscle groups was confirmed, his calf muscles were found to be hypertrophic and there was a tendency to Gowers manoeuvre.

The laboratory tests showed abnormal values of: myoglobin (220 ng/ml), creatine kinase (CK: 27295 U/l), CK-MB (10.1 ng/ml) and serum creatinine: (90  $\mu$ mol/l), with estimated GFR of 84.3 ml/min/1.73m<sup>2</sup> (Schwartz formula). Alanine aminotransferase was 165 U/l, the aspartate aminotransferase was 227 U/l. Serum electrolytes, complete blood count and thyroid function were all in normal range. The electromyography showed normal nerve conduction and the cerebral

and spinal Magnetic Resonance Imaging no morphological abnormalities. The capillaroscopy and the antinuclear antibodies were negative, as well as the research for viral and bacterial infections. Acetylcarnitine and serum aminoacids were found to be in normal range.

After a few days of observation the muscular cramps gradually disappeared and the renal function remained stable. On account of the clinical and chemical findings, especially considering that rhabdomyolysis was not due to hypokalemia (serum potassium levels were normal: median 4.1 mmol/l, range 3.7 – 4.7) (Figure 2) the decision of performing a genetic analysis for muscular dystrophies was taken. After isolating the DNA from peripheral blood leukocytes, PCR analysis was performed using specific primers for the cDNA. The study demonstrated an in-frame deletion of exon 48 of the dystrophin gene, which was consistent with the diagnosis of BMD.

### Discussion

We have reported the unusual case of a boy, in whom the typical hypokalemia of BS was altered by the presence of a muscular disorder which causes the ongoing release of potassium and muscular enzymes from the muscular fibre lysis

leading to normal serum potassium levels and high levels of CK [6].

Other causes of rhabdomyolysis may be excluded in our patient. A wide range of diseases and circumstances may lead to rhabdomyolysis, the most common cause is the muscular trauma. Less common causes include extraordinary physical exertion, muscle enzyme deficiencies, infections and toxins, endocrinopathies, medical drugs, alcohol, electrolyte abnormalities, including hypophosphatemia, hypocalcemia, hypernatremia, hyponatremia, and especially hypokalaemia [7]. Rhabdomyolysis has been already reported in patients affected by BS. In adult patients and, more recently in a 4-year-old girl, marked hypokalemia (< 2mEq/l) caused myopathy with rhabdomyolysis [8].

Our patient was investigated for all the above causes of rhabdomyolysis, but none could be detected. Indeed, at any time the serum potassium concentration could not have justified the rhabdomyolysis observed, and there are no pediatric reports showing rhabdomyolysis with normokalemia in children affected by BS.

Hyperuricemia is usually reported in association with BS (up to 50% of patients with BS). A previous case of an adult patient with the association of BS, BMD and symptomatic hyperuricemia has been reported by Fishel et al [9]. That patient was first diagnosed with muscular dystrophy at the age of 19, then with gout (40 years) and finally he developed clinical and laboratory markers of BS at the age of 49 years. However, no molecular biology on BS is reported in the Fishel's case. Furthermore no renal US was performed and the paediatric history of this patient is not reported.

BMD is caused by abnormalities in the quality and/or quantity of dystrophin, a protein located on the inner face of the plasma membrane in connection with the sarcolemmal membrane of all types of myofibers. A recent hypothesis suggests that the chronic intracellular  $Ca^{2+}$  overload, leading to degeneration of dystrophin-deficient skeletal muscle, is tightly controlled by the membrane potential which is set by sarcolemmal ion channels activity [10]. However, no evidences

have been produced to demonstrate that the loss-of-function mutation in NKCC2 can determine effects both in kidney and in skeletal muscles.

Although the simultaneous occurrence of BS and BMD can be considered coincidental, physicians should be aware that a biochemical change of BS can occur in the presence of another condition, simultaneously affecting the potassium homeostasis.

## REFERENCES

1. Kleta R, Bockenhauer D. Bartter Syndromes and Other Salt-Losing Tubulopathies. *Nephron Physiol* 2006; 104: 73–80.
2. Bettinelli A, Ciarmatori S, Cesareo L, Tedeschi S, Ruffa G, Appiani AC, et al. Phenotypic variability in Bartter syndrome type I. *Pediatr Nephrol* 2000; 14: 940-45.
3. Ertekin V, Selimoglu AM, Orbak Z. Association of Bartter's syndrome and empty sella. *J Pediatr Endocrinol Metab* 2003; 16: 1065-68.
4. Robitaille P, Tousignant K, Dubois J. Bartter syndrome and cholelithiasis in an infant: is this a mere coincidence? *Eur J Pediatr* 2008; 167: 109-10.
5. Tomimatsu T, Fukuda H, Kanzaki T, Hirano S, Wada K, Murata Y. Neonatal Bartter syndrome with unilateral multicystic dysplastic kidney disease. *Pediatr Nephrol* 2003; 18: 391-93.
6. Visweswaran P, Guntupalli J. Rhabdomyolysis. *Crit Care Clin* 1999; 15: 415-28.
7. Gennari FJ. Hypokalemia. *N Engl J Med* 1998; 339: 451-58.
8. Pela I, Materassi M, Seracini D, Lavoratti G, Bettinelli A. Hypokalemic rhabdomyolysis in a child with Bartter's syndrome. *Pediatr Nephrol* 2005; 20: 1189-91.
9. Fishel B, Zhukovsky G, Legum C, Jossiphov J, Alon M, Peer G, Iaina A, Nevo Y. A case of Bartter's syndrome, gout and Becker's muscular dystrophy. *Clin Exp Rheumatol* 2000; 18: 426-27.
10. Allard B. Sarcolemmal ion channels in dystrophin-deficient skeletal muscle fibres. *J Muscle Res Cell Motil* 2006; 27: 367-73.