

# Journal of Pediatric Sciences

## Bells Palsy in Children – A review

Arif Khan, Nahin Hussain, Jayaprakash Gosalakkal

Journal of Pediatric Sciences 2011;3(2):e77

How to cite this article:

Khan A, Hussain N, Gosalakkal J. Bells Palsy in Children – A review.  
Journal of Pediatric Sciences. 2011;3(2):e77

# Bells Palsy in Children – A review

Arif Khan, Nahin Hussein, Jayaprakash Gosalakkal

## Abstract:

Bell's palsy is defined as an isolated unilateral lower motor neurone facial weakness of no obvious cause. It is the most common cause for acute facial nerve (VII cranial nerve) paralysis. The incidence has been estimated at around 20 to 25 cases per 100 000 population annually but the exact incidence in children is not known. It manifests as unilateral impairment of movement in the facial muscles, drooping of the brow and corner of the mouth, and impaired closure of the eye and mouth. Acute lower motor neurone facial paralysis is a common presentation in childhood. In most cases, an aetiological agent is not identified and the condition resolves spontaneously. We have reviewed the available literature for Bell's Palsy in children, along with in-depth evidence review for use of steroids and aciclovir in this condition.

**Keywords:** Bell's Palsy, Facial paralysis, Lower motor neurone, Magnetic resonance imaging, Steroids and Acyclovir.

**Received:** 05/12/2010; **Accepted:** 24/03/2011

## Introduction

Bell's palsy is defined as an isolated unilateral lower motor neurone facial weakness of no obvious cause. It is the most common cause for acute facial nerve (VII cranial nerve) paralysis [1]. The incidence has been estimated at around 20 to 25 cases per 100 000 population annually [2] but the exact incidence in children is not known. It manifests as unilateral impairment of movement in the facial muscles, drooping of the brow and corner of the mouth, and impaired closure of the eye and mouth. Acute lower motor neurone facial paralysis is a common presentation in childhood. In most cases, an aetiological agent is not identified and the condition resolves spontaneously [3].

## Clinical features

The most alarming symptom of Bell's palsy is the paralysis of muscles of facial expression and often causes significant facial distortion. Majority of the children and their carers think they have had a stroke or have an intracranial tumour. The weakness is often sudden in onset and evolves rapidly, with maximal facial

weakness developing within two days. Older children can sometimes complain of numbness of face, dryness of the mouth and eye on the affected side, loss of taste in the front portion of the tongue, ear pain and intolerance to loud noises on the affected side. Parents and careers

Arif Khan, Nahin Hussein,  
Jayaprakash Gosalakkal

Department of Paediatric Neurology, Leicester  
Royal Infirmary, University Hospital of Leicester  
NHS Trust, Leicester LE1 5WW, United Kingdom

Correspondence author:  
Arif Khan, MRCPCH

Department of Paediatric Neurology, Leicester  
Royal Infirmary, University Hospital of Leicester  
NHS Trust, Leicester LE1 5WW, United Kingdom  
Tel : 01162739491  
Fax: 01162587760  
E-mail: khangoa@hotmail.com

can notice the child having difficulty in speaking, watering of the eye on the affected side and dribbling when drinking or after cleaning teeth.

### **Etiology and pathophysiology**

Bell's palsy is a rare diagnosis in a child. The underlying mechanism of Bell's palsy remains unclear, but seems to be due to the reactivation of Herpes simplex virus type 1 within the intrapetrous pathway of facial nerve [4]. The reactivation of varicella zoster virus (VZV) has also been suggested to be among the etiologies of idiopathic peripheral facial nerve palsy [5,6]. This makes a significant difference due to poorer prognosis and the therapy of the palsy. Independent of the patients age, idiopathic facial palsy is a diagnosis of exclusion [7].

It is important to consider other diagnosis when a child presents with a unilateral rapid onset lower motor neurone VII nerve paresis. Conditions such as infections, inflammation, injuries, neoplasias, metabolic causes and congenital anomalies should be excluded. A thorough neuropediatric examination including lumbar puncture plays the most important role for the exclusion of borreliosis, other CNS-pathologies and syndromes. Besides, the ENT-examination excludes the most common infectious condition namely otitis media or mastoiditis. However, in endemic areas borreliosis remains the most important exclusion diagnosis in unilateral facial nerve palsy in children, as it can be responsible for up to 50% of cases of facial nerve palsy [8]. Congenital facial nerve palsy may be the result of developmental defects or traumatic etiology. Facial paralysis in the neonate is uncommon, occurring in 0.23% to 1.8% of live births. Out of these, 78% to 90% are associated with birth trauma [9].

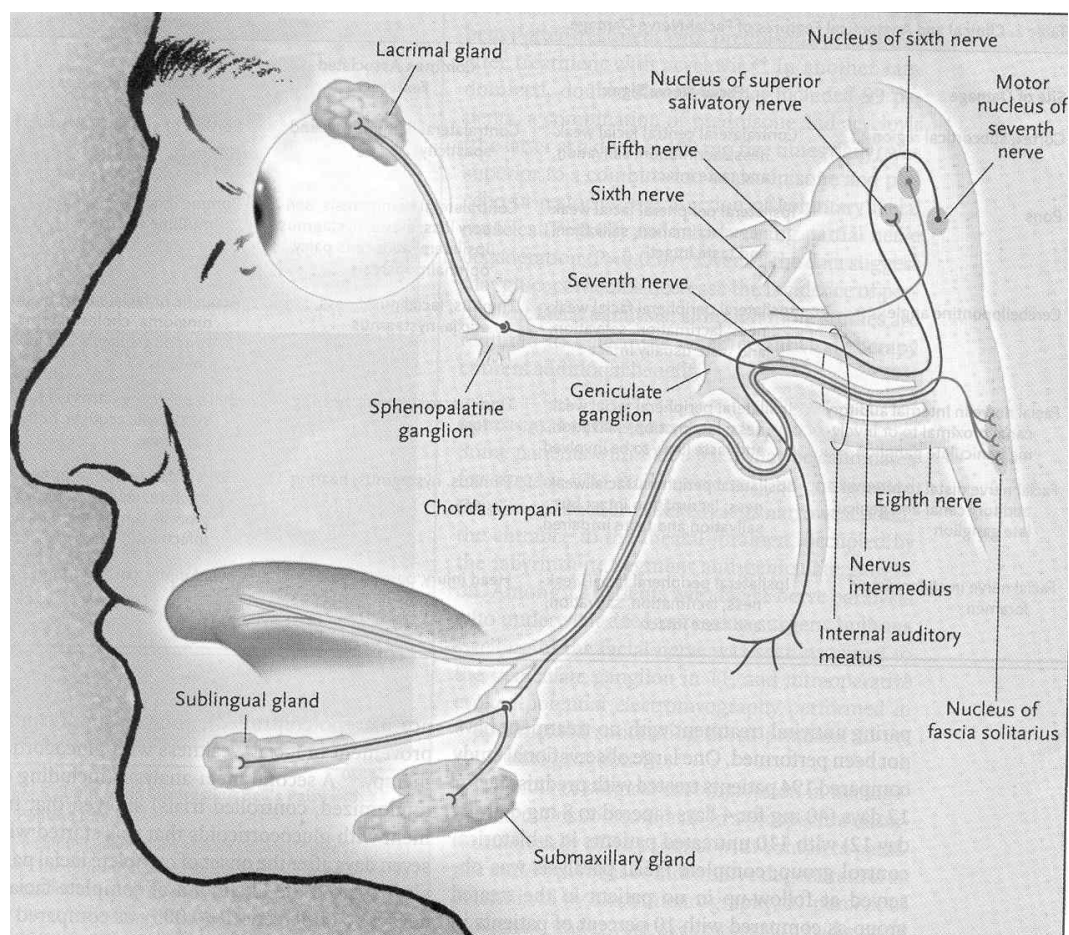
Many studies looking at etiologies of facial nerve palsy in children have been carried out. There is considerable variation in the proportion of each category between the old and recent

studies. This can be explained by the fact that more recently detailed investigation of children presenting with facial nerve weakness have been carried out.

The pathophysiology of idiopathic facial nerve palsy is uncertain. It often occurs two to three weeks following a viral illness. A variety of specific pathologies can also produce an acute lower motor neurone facial paralysis. Active viral invasion of the nerve, vascular ischaemia and immune demyelination have been implicated. The role of physical swelling of the nerve in the pathophysiology is unclear. Increasing evidence implies that the main cause of Bell's palsy is latent herpes viruses (herpes simplex virus type 1 and herpes zoster virus), which are reactivated from cranial nerve ganglia [10]. Sensitive polymerase chain reaction techniques have isolated herpes virus DNA from the facial nerve during acute palsy [11]. Inflammation of the nerve initially results in a reversible neurapraxia, but ultimately Wallerian degeneration ensues.

### **Course of facial nerve:**

The facial nerve (VII) nucleus is situated in the pons lateral to that of the sixth nerve. The facial nerve fibres winds around the sixth nerve nucleus and emerges medial to the eighth nerve at the pontomedullary junction, it then enters the skull via the internal auditory meatus, and passes along the facial canal. The nerve passes in close proximity to the medial wall of the inner ear and the mastoid cavity. During its course through the petrous temporal bone, branches leave to supply the lacrimal glands, the stapedius muscle in the inner ear, sensation for auricular skin, the sublingual and submandibular salivary glands, and taste fibres to the anterior two thirds of the tongue. The facial nerve exits the skull via the stylomastoid foramen and terminal branches supply the muscles of facial expression [Figure 1]. Lower motor neurone facial weakness may result from a lesion anywhere between the facial nerve nucleus in the pons and the terminal



**Figure 1. Functional anatomy of the facial nerve. Facial nucleus is in the caudal pons. The facial nerve courses dorsomedially and encircles the nucleus of abducens (sixth) cranial nerve. After bending around the abducens nucleus, the facial nerve lies close to the sixth nerve. The facial nerve exits the pons in the cerebellopontine angle close to the fifth, sixth, and eighth cranial nerves. The eighth nerve, the motor root of the seventh nerve, and the nervus intermedius (the sensory and parasympathetic root of the facial nerve) enter the internal auditory meatus. Sensory cells located in the geniculate ganglion continue distally as the chorda tympani nerve, which carries taste fibres. Peripheral fibres of the nervus intermedius portion of the facial nerve initiate salivary, lacrimal, and mucous secretion.**

branches. In majority of cases of Bell's palsy lesion is in the facial nerve after it passes through the internal auditory meatus and before it exits the stylomastoid foramen [12].

### Diagnosis

Making a diagnosis of Bell's palsy in children can be difficult. A full clinical history should be taken, and a detailed physical examination performed. A thorough neurological examination is essential to exclude the involvement of the central nervous system (hemiparesis, other

cranial nerve involvement etc) and upper motor neurone facial paralysis. Bell's palsy is not synonymous with facial nerve paralysis but is a diagnosis of exclusion for acute onset of idiopathic facial nerve paralysis. A small number of cases are caused by a variety of underlying pathologies some of which have significant mortality and morbidity associated with them [table 1].

The differential diagnosis for facial nerve paralysis should be considered to correctly

**Table I. Causes of acquired facial nerve paralysis**

<b>Infective or inflammatory</b>	Otitis media, mastoiditis, Temporal lobe abscess, Herpes zoster (Ramsay Hunt syndrome) (35), Varicella, mumps, meningitis, encephalitis, Mycoplasma (36), Lyme disease, Kawasaki disease, Guillain-Barre syndrome, Cat scratch disease, HIV
<b>Trauma</b>	Facial burn (16), basal skull fracture, penetrating injury, surgery
<b>Neoplastic</b>	Leukaemia, Rhabdomyosarcoma, Cerebellar astrocytoma
<b>Haematological</b>	Histiocytosis, Haemophilia (37)
<b>Congenital</b>	Melkersson-Rosenthal syndrome, Intracerebral arteriovenous malformation, Osteopetrosis (16)
<b>Other</b>	Hypertension, sarcoidosis

evaluate and give appropriate therapy in a timely fashion for the treatable causes of facial nerve paralysis. Children with atypical signs or symptoms and focal neurological signs require urgent specialist referral [table 2],[3, 13].

Facial weakness is best demonstrated by asking the child to “close their eyes” (testing upper facial area) and “show me your teeth” (for testing the lower facial area). Bilateral cortical innervation of the muscles of the upper face (orbicularis oculi and frontalis) means that complete facial paralysis is only seen with lower motor neurone lesions. The extent of additional impairment depends on the site of injury. Proximal lesions are associated with impaired lacrimation, hyperacusis, and loss of taste on the anterior two thirds of the tongue. The first step is to differentiate between an upper and lower motor neurone lesion of the facial nerve. A lower motor neurone lesion occurs with Bell's palsy, whereas an upper motor neurone lesion is associated with a cerebrovascular accident or lesion. A lower motor neurone lesion causes

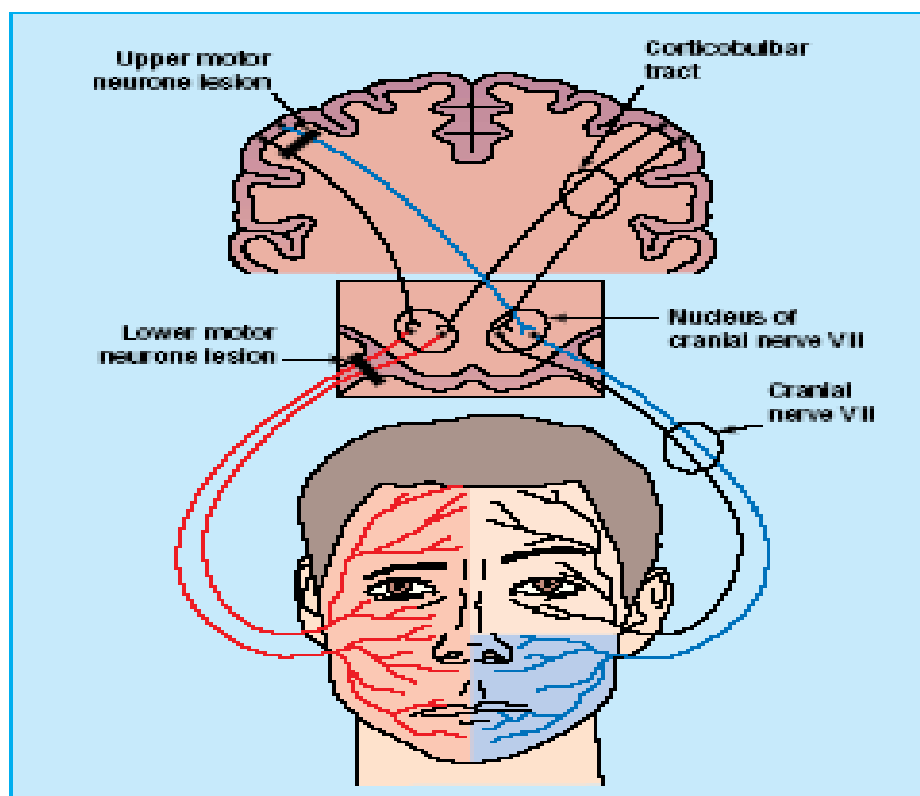
weakness of all the muscles of facial expression. Weakness of frontalis occurs, eye closure is weak and the angle of the mouth falls. With an upper motor neurone lesion frontalis is spared, normal furrowing of the brow is preserved, and eye closure and blinking are not affected [figure 2] [14].

Bell's palsy (lower motor neurone facial weakness) results in complete facial paralysis on one side resulting in asymmetry of the face. The paralysis of the following muscles innervated by the facial nerve results in inability to frown and wrinkle the forehead (nasociliary and frontal head of occipitofrontalis), difficulty in eye closure and bell's phenomena (orbicularis oculi), inability to whistle and puff out the cheeks with expiration (orbicularis oris and buccinator), flattening of nasolabial fold and drooping of angle of mouth on affected side due to paralysis of muscles of facial expression. Bell's phenomenon is upward diversion of the eye on attempted closure of the lid and is seen when eye closure is incomplete.

**Table II. Symptoms and signs indicative of possible additional pathology requiring urgent specialist referral**

Earache, Hearing loss (VIII cranial nerve paresis with possibility of cerebropontine angle lesions), Acute suppurative ear disease.	Lymphadenopathy, pallor or bruising, erythema migrans (Lyme disease).
Pain, paraesthesia or Single branch involvement	Vesicles in external meatus or on soft palate (Ramsay hunt syndrome)
Associated cranial neuropathies or other neurological signs	Mastoid swelling
Hypertension	Gradual progression of paralysis beyond 3 weeks or Recurrence.

Look for a painful rash and vesicles in the ear, which indicates Ramsay Hunt syndrome caused by herpes zoster virus. Otoscopy is



**Figure II. Lesion of right upper motor neurone causes central pattern of facial weakness on left with sparing of upper part of the face. Lesion of right lower motor neurone causes complete facial paralysis on the right side of the face (14).**

mandatory. Where adequate auditory acuity cannot be confirmed an audiogram should be arranged. Hypertension is a rare but well recognised cause of facial paralysis [15] hence all children must have their blood pressure checked. Check that no other cranial nerves are involved. Bell's palsy is seventh nerve palsy in isolation. Look for pointers to a more serious underlying cause that might require urgent referral [3, 13].

### Investigations

Controversy exists as to the appropriate investigation of children presenting with acute facial paralysis. A good clinical history and systematic examination will help in excluding other causes of acute onset facial weakness. Facial paralysis is a recognised feature of leukaemia in children. As a result, some authorities have recommended the routine performance of a full blood count for all children

presenting with acute lower motor neurone facial paralysis [16]. MRI is a common diagnostic tool in a child. Radiological imaging is essential if additional neurological abnormalities are identified or if malignancy like neuroblastoma is suspected. Magnetic resonance imaging (MRI) is especially helpful in identifying intracranial and brainstem pathology. Contrast enhanced magnetic resonance imaging can identify sections of affected nerve in idiopathic facial palsy [17]. This expensive and invasive test is not indicated in the majority of children presenting with typical features of Bell's palsy [13].

The primary concern for the patient and the physicians is when and how facial paralysis will be completely resolved [18]. Currently, the nerve excitability test, nerve conduction study (NCS), blink reflex test, and needle electromyography (EMG) are used to determine the prognosis.

Demonstration of fibrillation potentials that reveal axonal damage in the facial nerve and the associated muscle denervation provide valuable information for predicting a poor prognosis in the subacute phase [19].

Most clinical neurophysiologists recommend electromyographic and electroneurographic studies 10-15 days after the onset of facial weakness in Bell's palsy to determine the magnitude of axonal damage to the facial nerves [20].

However, it should be stated, that the more reliable method of a needle-EMG cannot be easily performed in a child. The alternative method of a surface-EMG is not as precise as a needle-EMG. EMG and NCS with measurement of fibrillation potentials and recording of the blink reflex can provide objective assessment of facial nerve function and reassure parents and children [13]. It has to be emphasized that, as yet there is no reliable investigation or test at presentation that can indicate who will make a full recovery [21].

### **Treatment**

The treatment of idiopathic facial (Bell's) palsy is controversial. The use of steroids early in the course of the disease has been suggested as a way of reducing the duration of paralysis (by decreasing the inflammation and oedema of the nerve sheath) and the risk of long-term impairment. A meta-analysis of randomised control trials, performed in adults, seems to support this view [22]. The benefits of steroid treatment have yet to be proven in children [23,24] [table 3]. Majority will recover completely, with or without treatment [25]. Similarly the routine use of antiviral agents has not been found to be beneficial [table 4]. The use of steroids and acyclovir in the treatment of Bell's palsy has been addressed in two recent cochrane reviews [26, 27]. These found no benefit from either but concluded that available

studies were insufficiently powered to detect a treatment effect.

Surgical decompression of the facial nerve canal is no longer considered an effective treatment for patients with idiopathic facial palsy. A number of other treatments, aimed at improving outcome like vitamin B<sub>12</sub>, alone or in combination with steroids, 100% hyperbaric oxygen, nerve repair, transposition and graft for persistent facial weakness has been tried in adults with variable outcomes [21].

Ninety five per cent of children will recover full function most within the first three weeks of the illness [28, 29]. A randomised controlled trial done exclusively in children reported a recovery rate of 80-90% in the first six months of the disease and this reached 100% by 12 months irrespective of use of steroids [30].

Persistent facial weakness can have considerable functional and cosmetic implications [3]. The small numbers of children falling into this group require expert assessment.

Complete facial palsy, no recovery by three weeks, associated conditions like hypertension, diabetes and severe degeneration of facial nerve shown by electrophysiological testing are indicators of poor prognosis in Bell's palsy [21].

### **Differences between adult-onset and childhood facial nerve palsy.**

Facial nerve paralysis is a relatively uncommon condition in the paediatric population. It appears 2 to 4 times less frequently in children than in adults [31]. In all the studies analysing etiology of facial nerve palsy, Bell's Palsy was the most prevalent cause. Chang et al reported that the most frequent cause of facial nerve palsy in adults was Bell's palsy (54.9%) followed by infection and trauma, whereas in children Bell's Palsy was diagnosed in 66.2% of children with facial nerve palsy.

**Table III. Relevant papers for evidence of use of oral steroids in children with Bells palsy (Adapted from Ashtekar et al (38))**

Author, date and country	Patient group	Study type (level of evidence)	Outcomes	Key results	Study Weaknesses
<b>Salinas RA 2001 Chile</b>	3 RCTs with a total of 117 patients. One trial compared cortisone acetate with placebo; one compared prednisolone plus vitamins, with vitamins alone; and one, not placebo controlled, tested the effect of methylprednisolone	Systematic review (level 1a)	Effect of steroid therapy in the recovery of Bell's palsy	Overall 13/59 (22%) of patients allocated to steroid therapy had incomplete recovery 6 months after randomisation compared with 15/58 (26%) in control group	Only one trial was done exclusively in children (mentioned above, Unuvar et al) Small number of patients.
<b>Salman and MacGregor 2001 Canada</b>	8 RCTs in total. 5 trials comparing steroids with no intervention, 1 trial each comparing steroids with either acyclovir or vitamins, or hyperbaric oxygen.	Systematic review (level 1b)	Clinical and electrical recovery in 6 trials, clinical recovery with electromyography if no recovery in 1 trial, and in the remaining one 3 doctors assessing photos and complication rate.	3 trials found no significant difference with steroids, 4 trials showed some benefit with steroids while 1 trial showed hyperbaric oxygen to be more effective.	Only one trial was done exclusively in children (mentioned above, Unuvar et al) The paediatric cases in the remaining 7 trials were not analysed separately. 5 of the 8 trials were randomised. The trial designs, treatment schedule and outcome measures were heterogeneous.
<b>Unuvar E 1995 Turkey</b>	42 children with complete facial palsy Group 1(n=21) received methyl prednisolone 1mg/kg/day PO for 10 days; Group 2 (n=21) no treatment	RCT (level 1b)	Recovery at 4, 6 and 12 months	Recovery rate: group 1, 86% and 100% at 4 and 6 months and group 2, 72% and 86% at 4 and 6 months. All regained facial nerve function at 12 months	Small numbers Not placebo controlled or blinded
<b>Dhiravibulya 2002 Thailand</b>	75 children with Bell's palsy, 28 excluded. 39 of the remaining 47 children in the study received oral prednisolone	Retrospective case series Jan 1996 –July 2001 (level 4)	Recovery from Bell's palsy	Of the 39 who received prednisolone, complete recovery in 24(61.5%), nearly complete in 15(38.5%). All children, including those who did not receive steroid, recovered completely within 7 months.	Uncontrolled, retrospective, observational study



**Table IV. Relevant papers for evidence of use of acyclovir in bell's palsy (Adapted from Yuen et al. 39)**

Author, date and country	Patient group	Study type (level of evidence)	Outcomes	Key results	Study Weaknesses
<b>Adour KK et al, 1996, USA</b>	119 patients presented within the first 72 hours Acyclovir & prednisolone v placebo & prednisolone Acyclovir 2000mg per day for 10 days Prednisolone 1 mg/kg for 5 days tapered to 10 mg/day for next 5 days	PRCT	Electrical testing	Acyclovir & prednisolone group had less partial nerve degeneration (p=0.05)	Small study 20% patients (16.8%) were lost to follow-up No intention to treat analysis
			Visual assessment of motor recovery by FPRP & FPRI	Small treatment effect was demonstrated in the acyclovir & prednisolone group (p=0.04)	
<b>De Diego JI et al, 1998, Spain</b>	113 patients presenting within the first 96 hours Acyclovir alone v prednisolone alone Acyclovir 2400mg per day for 10 days Prednisolone 1mg/kg for 10 days tapered to zero over the next 6 days	PRCT	Electrical testing	Prednisone had less degeneration of marginal branch of facial nerve (p=0.02)	Small study No real placebo control group 12 patients (10.6%) were lost to follow-up No intention to treat analysis
			Visual assessment of motor recovery by FPRP	Prednisone was beneficial (p=0.0338)	

The incidence of facial paralysis caused by trauma was significantly higher in children than adults, but this could be attributed to the higher number of injuries in children caused by falls and traffic accidents [32]. Numerous studies conducted on factors influencing the prognosis of facial nerve palsy show that younger age was associated with better prognosis [33,34].

### Conclusion

Bell's palsy is a self-limiting idiopathic rapid onset facial palsy that is non-life-threatening and has a generally favourable prognosis. Facial paralysis can be caused by numerous conditions, all of which should be excluded before a diagnosis of Bell's palsy is reached. The etiopathogenesis of Bell's palsy is uncertain; acute immune demyelination triggered by a viral infection may be responsible. Children presenting with Bell's palsy should have a full physical and neurological examination. Otoscopy and blood pressure measurement are

mandatory. To date there is no clear evidence that any form of treatment improves outcome. Studies in Adults have shown that prednisolone is still the only evidence-based medication option for idiopathic facial nerve palsy. However there is no data to clarify the dose and duration of treatment. Protection of the cornea, with artificial tears and overnight patching, is normally all that is required. Follow up is advisable and persistent or recurrent Bell's palsy requires specialist referral. There is a need for a well designed adequately powered, multicentre randomised controlled trial to evaluate etiopathogenesis, outcome and the role of various treatment options in children.

## REFERENCES

1. Adour KK, Byl FM, Hilsinger RL Jr, Kahn ZM, Sheldon MI. The true nature of Bell's palsy: analysis of 1,000 consecutive patients. *Laryngoscope* 1978; 88:787-801.
2. Martyn CN, Hughes RAC. Epidemiology of peripheral neuropathy. *J Neurol Neurosurg Psychiatry* 1997; 62:310-18.
3. May M, Fria TJ, Blumenthal FW, et al. Facial paralysis in children: differential diagnosis. *Otolaryngol Head Neck Surg* 1981; 89:841-8.
4. Tankere F, Bernat I. Bell's palsy: from viral aetiology to diagnostic reality. *Rev Med Interne* 2009; 30: 769-75
5. Yamakawa T, Hamada M, Takeda T. Different real-time PCR assays could lead to a different result of detection of varicella zoster virus in facial palsy. *J. virol methods* 2006; 139:227-29.
6. Furuta Y, Aizawa H, Ohtani F, Sawa H, Fukuda S. Varicella-zoster virus DNA level and facial paralysis in Ramsay Hunt syndrome. *Ann Otol Rhinol Laryngo* 2004; 113:700-5
7. Finsterer J. Management of peripheral facial nerve palsy. *Eur Arch otorhinolaryngol* 2008; 265:743-52.
8. Roob G, Fazekas F, Hartung HP. Peripheral facial palsy: etiology, diagnosis and treatment. *Eur Neurol*.1999;41:3-9.
9. Falco NA, Eriksson E. Facial nerve palsy in the newborn: incidence and outcome. *Plast Reconstr Surg*. 1990;85:1-4.
10. Devriese PP. Bell's palsy in children. *Acta otorhinolaryngol Belg* 1984; 38:261-7.
11. Murakami S, Mizobuchi M, Nakashiro Y, Doi T, Hato N, Yanagihara N. Bell's palsy and herpes simplex virus: identification of viral DNA in endoneurial fluid and muscle. *Ann Intern Med* 1996; 124: 27-30.
12. Hilger J. The nature of Bell's palsy. *Laryngoscope* 1949; 59:228-35.
13. Riordan M. Investigation and treatment of facial paralysis. *Arch. Dis. Child*. Apr 2001; 84: 286 – 288.
14. Dresner SC. Ophthalmic management of facial nerve paralysis. *Focal points*. San Francisco: American Academy of Ophthalmology, Jan 2000.
15. Lloyd AV, Jewitt DE, Still JD. Facial paralysis in children with hypertension. *Arch Dis Child* 1966; 41:292-294
16. Grundfast KM, Guarisco JL, Thomsen JR, Koch B. Diverse etiologies of facial paralysis in children. *Int J Pediatr Otorhinolaryngol* 1990; 19:223-239.
17. Tien R, Dillon WP, Jackler RK. Contrast-enhanced MR imaging of the facial nerve in 11 patients with Bell's palsy. *AJNR Am J Neuroradiol* 1990; 11:735-741.
18. Ushin0 M, Kondo K, Takeuchi N, Tojima H, Yamaguchi T, Kaga K. Prediction of the prognosis of Bell's palsy using multivariate analyses. *Otol Neurotol* 2007; 29:69-72
19. Ozgur A, Semai B, Hidir UU, Mehmet Fatih O, Tayfun K, Zeki O. Which electrophysiological measure is appropriate in predicting prognosis of facial paralysis?. *Clin Neurol Neurosurg* 2010; 112:844-48.
20. Aramimed M, Valls-Sole J, Cruccu G, Ongerboer de Visseret BW. Disorders of the Cranial nerves. In *Neuromuscular Function and Disease: Basic, Clinical, and Electrodiagnostic Aspects*. Volume 1. 1st edition. Edited by: Brown WF, Bolton CF, Aminoff MJ. Philadelphia: W.B. Saunders Company; 2002:761.
21. HollandNJ, Weiner GM. Recent developments in Bell's palsy. *BMJ*, Sep 2004; 329: 553 – 557.
22. Williamson IG, Whelan TR. The clinical problem of Bell's palsy: is treatment with steroids effective? *Br J Gen Pract* 1996; 46:743-747.
23. Unuvar E, Oguz F, Sidal M, Kilic A. Corticosteroid treatment of childhood Bell's palsy. *Pediatr Neurol* 1999; 21:814-816.
24. Salman MS, MacGregor DL. Should children with Bell's palsy be treated with corticosteroids? A systematic review. *J Child Neurol* 2001; 16:565-8.
25. Peitersen E. The natural history of Bell's palsy. *Am J Otol* 1982; 4:107-111.
26. Salinas RA, Alvarez G, Alvarez MI, et al. Corticosteroids for Bell's palsy (idiopathic facial paralysis). Most recent amendment 2001. *Cochrane Database Syst Rev* 2004; Issue 3.

27. Allen D, Dunn L. Aciclovir or valaciclovir for Bell's palsy (idiopathic facial paralysis). *Cochrane Database Syst Rev*. 2004;.
28. Inamura H, Aoyagi M, Tojima H, *et al*. Facial nerve palsy in children: clinical aspects of diagnosis and treatment. *Acta Otolaryngol Suppl* 1994; 511:150-152.
29. Prescott CA. Idiopathic facial nerve palsy in children and the effect of treatment with steroids. *Int J Pediatr Otorhinolaryngol* 1987; 13:257-264.
30. Marenda SA, Olsson JE. The evaluation of facial paralysis. *Otolaryngol Clin North Am* 1997; 30:669-82.
31. El-Hawrani AS, Eng CY, Ahmed SK, Clarke J, Dhiwakar M. General practitioners' referral pattern for children with acute facial paralysis. *J Laryngol Otol*.2005;119:540-42.
32. Cha CI, Hong CK, Park MS, Yeo SG. Comparison of Facial Nerve Paralysis in Adults and Children. *Yonsei Med J* 2008; 49(5):725-34.
33. Kerbavaz RJ, Hilsinger RL Jr, Adour KK. The facial paralysis prognostic index. *Otolaryngol Head Neck Surg* 1983;91:284-89
34. Smith IM, Heath JP, Murray JA, Cull RE. Idiopathic facial(Bell's) palsy: a clinical survey of prognostic factors. *Clin Otolaryngol Allied Sci* 1988;13:17-23.
35. Bjerkhoel A, Hyden D. Ramsay-Hunt syndrome in a preschool infant. *ORL J Otorhinolaryngol Relat Spec* 1989; 51:251-254.
36. Morgan M, Moffat M, Ritchie L, *et al*. Is Bell's palsy a reactivation of varicella zoster virus? *J Infect* 1995; 30:29-36.
37. Ray M, Ezhilarasan R, Marwaha RK, *et al*. Facial nerve palsy in an infant with hemophilia A. *Pediatr Hematol Oncol* 1999; 16:71-74.
38. Ashtekar CS. Do we need to give steroids in children with bell's palsy? Best Bets(Best evidence topics). Internet 2005.
39. Yuen M. Acyclovir was not shown to be effective in Bell's palsy. Best Bets(Best evidence topics). Internet 2000.