

Journal of Pediatric Sciences

Evaluation of Histopathology Examination of Routine Tonsillectomy and Adenoidectomy Specimens in Developing Countries

Adebolajo Adeyemo, Clement Okolo, Segun Ogunkeyede

Journal of Pediatric Sciences 2011;3(3):e96

How to cite this article:

**Adeyemo A, Okolo C, Ogunkeyede S. Evaluation of Histopathology Examination of Routine
Tonsillectomy and Adenoidectomy Specimens in Developing Countries.
Journal of Pediatric Sciences. 2011;3(3):e96**

Evaluation of Histopathology Examination of Routine Tonsillectomy and Adenoidectomy Specimens in Developing Countries

Adebolajo Adeyemo¹, Clement Okolo², Segun Ogunkeyede³

Abstract:

Objective: Healthcare costs are usually borne directly by patients or relations in developing countries; therefore reducing waste in the system is very important. This study aims to determine the necessity of full histopathology examination in routine tonsillectomy and adenoidectomy in children.

Methods: A retrospective chart review of patients 18 years and younger who underwent tonsillectomy and/or adenoidectomy between January 1986 and December 2006 at the University College Hospital, Ibadan, Nigeria was done. The age, sex, surgical procedure and pathology results were recorded. Histology reports were broadly classified into: non-neoplastic and neoplastic pathologies. Charts of neoplastic pathologies were pulled and the medical history reviewed.

Results: A total of 244 patients met the inclusion criteria with a mean age of 5.3 ±4.7 years. There were 150 males (61.5%) and 94 females (38.5%). Tonsillectomy and adenoidectomy were performed together on 74 patients (30.3%) while tonsillectomy and adenoidectomy alone were performed on 60 (24.6%) and 110 (44.7%) patients, respectively. Review of the pathology reports revealed two cases of malignancies with an incidence of 0.82%.

Conclusion: Medico-legal factors will suggest the review of all surgical specimens. Therefore it is important to identify innovative approaches to reduce costs of histopathology examination in routine tonsillectomies and adenoidectomies.

Keywords: Tonsillectomy; Adenoidectomy; Histology; Pathology; Neoplasm; Malignancy

Received: 09/05/2011; **Accepted:** 25/07/2011

Introduction

The palatine and nasopharyngeal tonsils are lymphatic tissues of the respiratory and digestive tract's epithelium. They constitute the central portion of the ring of lymphatic tissues at the oropharyngeal isthmus.

Tonsillectomy, with or without adenoidectomy is the most common major surgical procedure performed in the paediatric population [1]. The major indications for tonsillectomy and/or adenoidectomy are recurrent or chronic infections and obstructive sleep apnoea but the procedure can also be performed as a biopsy procedure to exclude malignancy.

In 1939, Starry noted that histopathology examination of all specimens should be done [2] since then a debate has ensued on the necessity of full pathologic examination of all tonsillectomy and

adenoidectomy specimens. Weibel, in 1965 stated that systematic microscopic examination was

Adebolajo Adeyemo¹, Clement Okolo²,
Segun Ogunkeyede³

¹Institute of Child Health, College of Medicine, University of Ibadan, PMB 5017, Ibadan, Nigeria

²Department of Pathology, College of Medicine, University of Ibadan, PMB 5017, Ibadan, Nigeria

³Department of Otorhinolaryngology, University College Hospital, PMB 5116, Ibadan, Nigeria

Correspondence author:

Adebolajo Adeyemo, FWACS

Institute of Child Health, College of Medicine, University of Ibadan, PMB 5017, Ibadan, Nigeria

Tel: +234-8037172329

Email: adebolajo@hotmail.com

justifiable in patients over the age of 40 years because “the incidence of malignant tumours in the rhinopharynx and the tonsils increases considerably after this age,” and that routine microscopic examination could be omitted in younger patients [3]. Other reasons adduced for dissent with Starry’s opinion are that pathological results from these specimens are not clinically significant and play no role in modifying the clinical course of the paediatric patient [4] moreover the incidence of unexpected pathologies is extremely low in childhood [4,5].

In Nigeria, like other developing economies health insurance coverage is very limited and the bulk of the costs of healthcare provision are borne out of pocket by the patients. Healthcare costs therefore places an acute burden on households’ resources, eliminating unnecessary investigation charges will be a great relief and free scarce resources. This situation has brought to fore again the debate on the necessity of routine histopathology examination of tonsillar specimens in otherwise normal subjects. This study therefore aims to evaluate the necessity of full histopathology examination in routine tonsillectomy and/or adenoidectomy by assessing the frequency of unexpected malignancy in children.

Material and methods

A retrospective chart review of all patients 18 years and younger who underwent tonsillectomy and/or

adenoidectomy between January 1986 and December 2006 at the University College Hospital, Ibadan, Nigeria was carried out. Records for the year 1995 were incomplete and therefore omitted. The records were reviewed to deduce the patient's age, sex, type of surgical procedure and the result of pathologic examination of the specimen. In our institution, adenotonsillectomy specimens are fixed in formalin, embedded in paraffin, sectioned with a microtome and stained with hematoxylin and eosin dye before light microscopic examinations. The histology reports were broadly classified into two groups: non-neoplastic and neoplastic pathologies. Patients that had neoplastic pathologies in their examination report had their charts pulled and their medical history reviewed.

Results

A total of 244 patients, (M:F, 1.6:1) met the criteria for inclusion in the study with a mean age of 5.3 ± 4.7 years. The age distribution and proportion of the surgical procedures done are shown in Figures I and II. The majority of the histology reports seen in the study were non-neoplastic lesions, (99.2%) while 0.82% was malignant.

The malignancies were two cases: a malignant lymphoma in a 13 year old male and pleomorphic rhabdomyosarcoma in a 16 year old male.

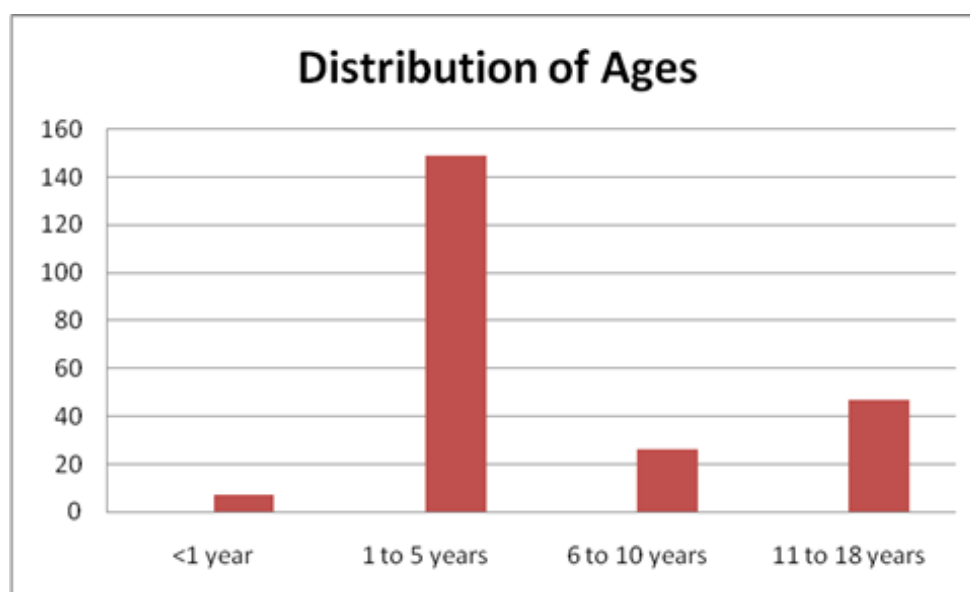


Figure I. Age distribution of patients.

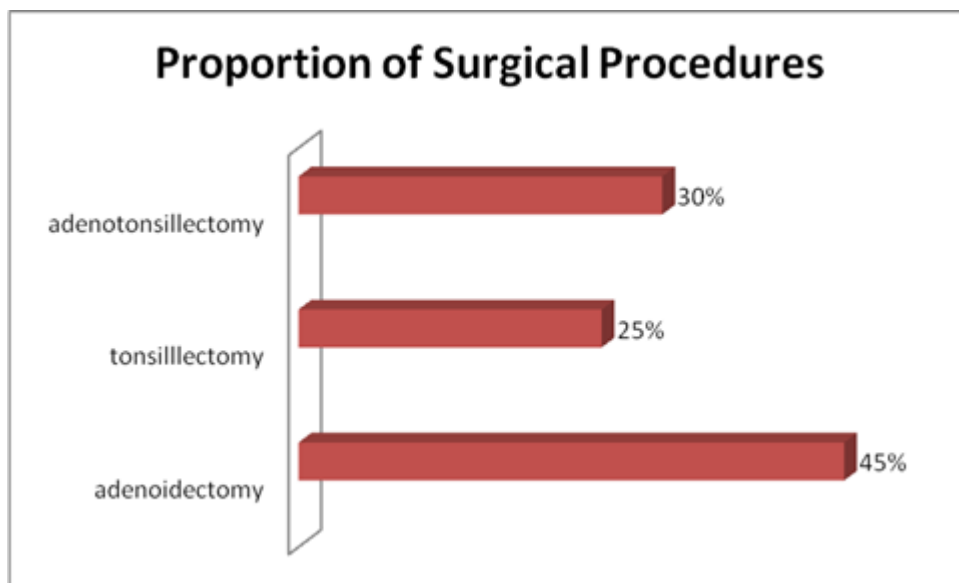


Figure II. Surgical procedures.

Discussion

Routine tonsillectomy and/or adenoidectomy are almost always performed for recurrent infections or obstructive hypertrophy. Although pathological examination of routine tonsillectomy and adenoidectomy specimens does not usually change the clinical line of management of the paediatric patient, it is performed so as not to miss an unexpected diagnosis especially malignancy [6,7]. Previous reports has shown the incidence of unexpected malignancy in routine tonsillectomy and/or adenoidectomy in children to be between 0 and 0.18% [1,4]. Weibel, documented only one case of lymphoma in an adult out of 4680 patients who had tonsillectomy and/or adenoidectomy [3]. Only one unexpected malignancy was reported by Daneshbod et al out of 15,120 adult and paediatric patients and thus the authors recommended that histopathology examination was not necessary for routine tonsil hypertrophies [7]. The incidence of malignancy in our series is 0.82%. The two cases of malignancy in our series were both suspected preoperatively. The patient with lymphoma presented with an oral mass, palpable hard cervical lymph nodes and acute respiratory obstruction. While the patient with pleomorphic rhabdomyosarcoma presented with a 6 month history of increasingly progressive swelling of the right side of the oropharynx with associated difficulty in breathing.

Lymphoma is the most common malignancy of the tonsil in children [8] accounting for 60% of all head and neck malignancies in this age group [9]. Pre-operative risk factors for malignancy in tonsillectomy specimens includes a history suggestive of cancer, tonsillar asymmetry, palpable firmness or visible lesion of the tonsil, neck mass, unexplained weight loss and constitutional symptoms (fatigue, night sweats, fevers and anorexia) [10]. Rhabdomyosarcoma, a soft tissue sarcoma is the fifth most common cancer in children [11] and the commonest sarcoma in children. About 40% of all cases occur in the head and neck region; within the head and neck a quarter of lesions present in non-parameningeal sites such as the oral cavity and oropharynx [12]. The pleomorphic sub-type is rarely seen in children, constituting about 4% of cases seen in the paediatric age group [13]. It is a standard practice in our hospital to send all the surgically removed tissues for routine full pathologic examination. However microscopic examination of all specimens adds to the medical care costs for patients and this is an important factor [4,5,15]. The cost of each histopathology examination for palatine tonsils in Nigeria varies between approximately \$13 (N2000) and \$130 (N20,000). In many developing countries like Nigeria where the majority of the population live on less than a US dollar a day [11] the cost of

histopathology examination translates to a huge amount of money.

Gross pathological examination of all specimens has been suggested with histopathology examination reserved for cases where clinical signs indicate the possibility of malignancy [1,4] though all specimens should be kept for later examination if warranted by subsequent clinical signs [1,7]. Even though all cases of neoplastic lesions in this series had a preoperative clinical suspicion of malignancy, the relatively high incidence of malignant lesions compared to other studies does not suggest a total abandonment of current practice. There may still be a need for histopathology examination of surgical specimens.

Conclusion

Despite the huge costs and resources associated with histopathology examination of routine tonsillectomy and/or adenoidectomy specimens, medico-legal arguments will support retaining the current practice. Rather than continuing the debate on the appropriateness or otherwise of the histopathology examination we suggest that innovative approaches to reduce costs of the examination be sought instead.

REFERENCES

1. Dohar JE and Bonilla JA. Processing of adenoid and tonsil specimens in children: a national survey of standard practices and a five-year review of the experience at the Children's Hospital of Pittsburgh. *Otolaryngol. Head Neck Surg*, 1996; 115: 94–97.
2. Starry AC. Pathology of the tonsil with statistical report and microscopic study. *Ann Otol Rhinol Laryngol*, 1939; 48: 346–358.
3. Weibel E. Pathological findings of clinical value in tonsils and adenoids. *Acta Otolaryngol*, 1965; 60: 331–338.
4. Williams MD and Brown HM. The adequacy of gross pathological examination of routine tonsils and adenoids in patients 21 years old and younger. *Hum. Pathol*, 2003; 34: 1053–1057.
5. Alvi A and Vartanian AJ. Microscopic examination of routine tonsillectomy specimens: is it necessary? *Otolaryngol. Head Neck Surg*, 1998; 119: 361–363.
6. Sodagar R and Mohallateh EA. Necessity of routine pathological examination of tonsils. *Eye Ear Nose Throat J*, 1972; 51: 229–230.
7. Daneshbod K, Bhutta RA and Sodagar R. Pathology of tonsils and adenoids: a study of 15, 120 cases. *Ear Nose Throat J*, 1980; 59: 466–467.
8. Erdag TK, Ecevit MC, Guneri EA, Dogan E, Ikiz AO and Sutay S. Pathologic evaluation of routine tonsillectomy and adenoidectomy specimens in the pediatric population: Is it really necessary? *Int. J. Pediatr. Otorhinolaryngol*, 2005; 69: 1321–1325.
9. Hicks J and Flaitz C. Mucoepidermoid carcinoma of salivary glands in children and adolescents: assessment of proliferation markers. *Oral Oncology*, 2000; 36: 454–460.
10. Beaty MM, Funk GF, Karnell LH, Graham SM, McCulloch TM and Hoffman HT et al. Risk factors for malignancy in adult tonsils. *Head Neck*, 1998; 20: 399–403.
11. Ruymann FB, Grovas AC. Progress in the diagnosis and treatment of rhabdomyosarcoma and related soft tissue sarcomas. *Cancer Invest*, 2000; 18: 223–241.
12. O'Sullivan B, Audet N, Catton CN, Gullane PJ. Soft Tissue and Bone Sarcomas of the Head and Neck. In: Harrison LB, Sessions RB, Hong WK, Kies, MS, et al (editors). *Head and Neck Cancer: A Multidisciplinary Approach*, second edition, Philadelphia; Lippincott Williams & Wilkins, 2004; 787–823.
13. Brown BJ, Oluwasola AO. Childhood rhabdomyosarcoma in Ibadan, Nigeria: 1984–2003. *Ann Trop Paediatr*, 2006; 26(4): 349–55.
14. Netser JC, Robinson RA, Smith RJ and Raab SS. Value based pathology: a cost analysis of the examination of routine and nonroutine tonsil and adenoid specimens. *Am. J. Clin. Pathol*, 1987; 108: 158–165.
15. FAO., 2006. FAOSTAT, food security statistics, Nigeria. http://www.fao.org/faostat/foodsecurity/Countries/EN/Nigeria_e.pdf. Food and Agricultural Organization of the United Nations, Rome.