

Journal of Pediatric Sciences

Ectopic located tooth which obstructed the maxillary sinus ostium

Mustafa Paksoy, Arif Őanlı, Gokhan Altın, Banu Atalay Erdogan, Zekiye Eda Bekmez

Journal of Pediatric Sciences 2012;4(3):e140

How to cite this article:

Paksoy M, Sanli A, Altin G, Atalay-Erdogan B, Bekmez ZE. Ectopic located tooth which obstructed the maxillary sinus ostium. Journal of Pediatric Sciences. 2012;4(3):e140.

CASE REPORT

Ectopic located tooth which obstructed the maxillary sinus ostium

Mustafa Paksoy, Arif Şanlı, Gokhan Altın, Banu Atalay Erdogan, Zekiye Eda Bekmez

Kartal Dr.Lutfi Kirdar Education and Research Hospital ENT Department, Istanbul, Turkey

Abstract: *A giant mucocele secondary to obstruction of the maxillary sinus ostium with an ectopic tooth. Mucocele secondary to ectopic maxillary tooth is very rare. We present a case of giant mucocele which is caused by obstruction of the maxillary sinus ostium with an ectopic tooth. The patient presented with headache and facial asymmetry. CT of the paranasal sinuses revealed an ectopic maxillary tooth, obstructing the maxillary sinus ostium and a mucocele of the maxillary sinus that erodes bony walls. The ectopic tooth was removed with Caldwell-Luc approach and the mucocele was marsupialized to the middle meatus with endoscopic sinus surgery. Ectopic maxillary tooth should be kept in mind as rare cause of paranasal sinus mucoceles.*

Keywords: *Tooth Eruption; Ectopic; Mucocele; Maxillary Sinus*

Accepted: April 18, 2012

Corresponding author : *Banu Atalay Erdogan, Kartal Dr.Lutfi Kirdar Education and Research Hospital ENT Department, Cevizli- Kartal-Istanbul/TURKEY, banuatalay81@gmail.com Phone:+902164413900 Fax:+90216352008*

Introduction

The cause of developing an ectopic tooth is a result of a serial abnormal interaction of the oral epithelium with an underneath located mesenchymal tissue during the configuration of a mature tooth (1). Transmigration or abnormal migration of the tooth are terms that describe an ectopic condition and denotes a far area from the alveolar process of the tooth. Disorders that include abnormalities that can be observed during tooth growth can be seen around of the oral cavity or at the other parts of the human body. When compare with canine tooth and submandibular 3rd molar tooth, it can be observed that tooth migration is more frequent in under-grown tooth at the premolars. The condition is more frequent in females than males. Migration abnormalities located at the maxillary sinus, mandibular condyle, angle, coronoid process, orbital, palate, mentum and, even at the dermis are frequently reported in the literature. Ectopic development of tooth is more frequent at the dental circumference, but surprisingly may rarely localize itself at other areas. Even though the

ratio of tooth abnormalities are higher in permanent tooth, it may also occur at the exit of a primary tooth. Especially, the condition is more frequent in children with a cleft palate and cleft lip (2,3). A mucocele is a benign expanding state that may chronically develop at the paranasal sinuses. It can easily develop after a sinus ostium blockage and locate itself at the ethmoidal region. Maxillary mucocele is a seldom condition and may develop more often after a trauma, a tumor or endonasal surgery (3,4). It may occur after an odontogenic developmental anomaly, commonly due to a trauma, and together with an odontogenic cyst or because of idiopathic reasons (5). Actually, the developmental process is still controversial (6). Symptoms may not be significant in most of the patients and the condition can be detected during routine radiographic studies. Such cases must be followed by radiographic studies. Surgical removal may depend on the symptoms of the patient, it's location and the co-pathologies.

Surgical extraction of a tooth can be decided according to the symptoms of the patient, the localization and to co-pathologies that accompany the condition (7). Chronic maxillary sinusitis, sourcing from dental conditions and/or development of a mucocele is a serious disorder where the odontogenic origin must be treated. External originated cysts or mucocele's are reported in the literature, but reports related with the migration of an ectopic or super numerated premolar tooth, that may completely block the ostiomeatal complex (OMC) is very scarce. Treatment of chronic sinusitis and a cyst, it may be essential to surgically extract the tooth. Excision can be carried out by Caldwell-Luc method or by an endoscopic sinus surgery (8). In this presentation, we reported a patient who was treated by a combined endoscopic sinus surgery (ESS) and a Caldwell operation, due to a ectopic tooth that caused chronic sinusitis, obstruction of nasal passage and an advanced facial asymmetry, by causing a formation of a mucocele, after locating itself at the left maxillary sinus OMC.

CASE REPORT

Our patient is a 12 years old girl who have referred to our clinic due to significant complaints such as blockage of nasal passage severe headache, loss of sense at the left cheek and extreme swelling. Physical examination showed a purulent nasal discharge, a ridging that closes the entire left nasal cavity towards the nasal septum located at the medial maxillary sinus wall, swelling at the nasolabial fold and significant facial asymmetry (Figure 1).

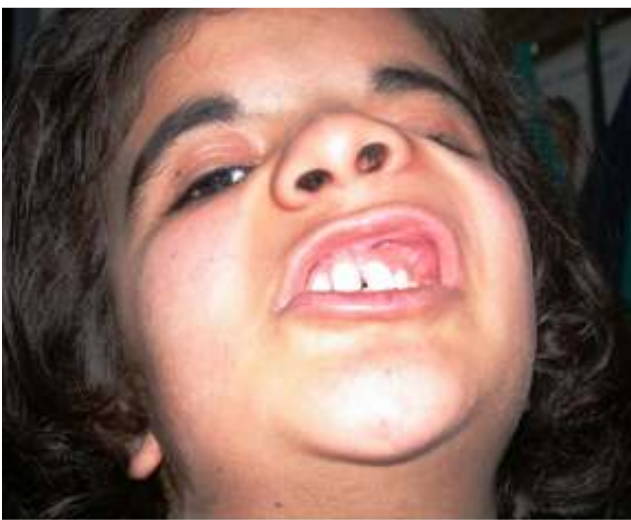

Figure1: Cheek swelling was measured by the eye-mouth line and the ear-nose line on the face.

Radiological CT study showed a significant hyperdense circular opacity enclosed with fine borders, at a dimension of 1 x 1 cm, located at the left OMC, accompanied with a cystic expansion at the soft tissue density which filled the left maxillary sinus. The coronal and axial cross-sections of the mucocele which occurred because of this obstructive hyperdense mass demonstrated a defect at the medial, anterior and posterior bone walls and also completely blocked the nasal air passage by expanding the medial maxillary wall towards the septum (Figure 2).

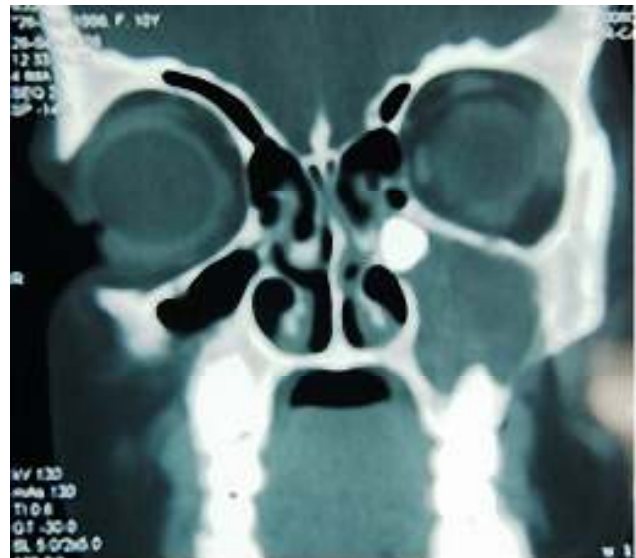

Figure 2: Computed tomography of the paranasal sinuses demonstrated a left well defined circular opacity surrounded by soft tissue mass in the left maxillary antrum in coronal section

An endoscopic sinus surgery (ESS), under general anesthesia of the left side of the patient was planned for therapy. After uncinectomy, OMC was localized and an ectopic mature premolar tooth, together with a completely developed root of the mass that blocked OMC was determined. Alone by an endonasal method, it was almost impossible to extract this ectopic mature premolar massive tooth from the OMC. Consequently, we decided that we needed to work together with a Caldwell approach to safely extract the tooth that localized itself at such a sensitive point and to drainage the content of the giant mucocele (Figure 3). Firstly, window was opened at the anterior maxillary wall. The anterior wall was very thin and muco-prulent fluid was drained from the left antrum. After then, the ectopic tooth was extracted from the medial wall after it was removed from the internal side of the antrum. Cystic wall structures that surrounded the cyst was resected. No any antrostomy was conducted from the

inferior meatus as there was enough space after the tooth was extracted from the OMC opening. A bleeding control was done and the gingivo-buccal excision site was sutured with a 3.0 vicryl sutures. The operation lasted approximately 30 minutes. No any major complications developed. During a long-term follow-up, symptoms were found to improve and a complete closure of the anterior wall opening was obtained.

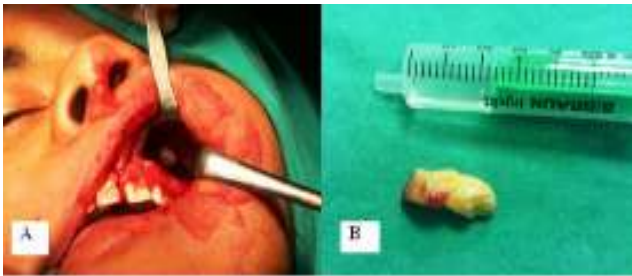


Figure 3: The tooth was seen in the left maxillary antrum via Caldwell-Luc procedure and it was excised.

Histopathological study revealed as a mucocele, demonstrating no any malignity, but containing a sum of granulomatous inflammation and a mature ectopic premolar tooth.

After a 2 years of follow-up of this patient, we saw that a significant improvement was present at nasal inhalation and facial asymmetry and the patient became asymptomatic at the end of the follow-up period. We finally all agreed that the disorder was a simple dental ectopic case which caused an unusual clinical table, completely affecting the maxillary sinus, and leading to a frontal and lateral expansion and asymmetric facial appearance and sensual loss.

DISCUSSION

Malposition of the tooth is a frequently encountered condition. Clinicians does not accept ectopic tooth formation or impactions as a commonly known reason (9). However, trauma, infection and abnormal development are admitted as possible causes. Abnormal tissue interactions may potentially result with ectopic tooth formation and ectopic tooth origin. Provided that ectopic origin of tooth can be seen at the nasal septum, mandibular condyle, coronoid process and palate, tooth extruding at different sites than the oral cavity is an extremely rare condition (3,10). Rarely, tooth may extrude from the maxillary antrum and may lead to local sinonasal symptoms such as repeated acute or chronic sinusitis, mucocele formation and sometimes, epistaxis (1,11). The frequency of

intraosseous abnormal migration of premolar tooth is lesser when compared with canine teeth and other teeth (8).

In our case, scarce location of an ectopic premolar tooth, at the OMC of the left maxillary sinus, without a past history of trauma and surgical intervention, has caused the formation of a giant mucocele and sinus expansion.

In the literature, ectopic eruptions are more commonly reported as a nasal tooth (8,12). Ectopic extruders and blockages may cause pain, nasal external deformity, sense of a foreign object, unilateral blockage, congestion, repeating epistaxis and mucosal incrustation at the mid-face area and head; rhinitis caseosa accompanied with a bad serious odor or a purulent discharge, or a development of a fistula tract towards the oral cavity. Dental pathologies must not be overlooked and must be eliminated as well in certain patients where such symptoms and findings are present (9,11). Exception of the formation of a fistula tract, all findings were present in our case.

In the literature there are a very small number of cases reported which were related with an ectopic and progressive premolar tooth, leading to a formation of a dentigerous cyst or a mucocele (3,5,8,12). We also did not encounter a case like this one in the literature where a patient is identified to have a deformation at the nasolabial sulcus, accompanied with a large facial asymmetry and a complete blockage at the outlet of the maxillary antrum, located at the OMC as an ectopic tooth.

Conventional sinus graphs and axial and coronal plane CT scanning may be used in the diagnosis of such pathologies. Final diagnosis may require a careful observation and evaluation of symptoms and findings. A complete localization of ectopic tooth can be determined by the aid of a CT study. Our CT study demonstrated an expansion at the left maxillary sinus and a complete blockage of the OMC due to hyperdense opacity. Yet we failed to obtain a tooth image. Even though we used an advanced study tool, CT failed to provide a definite diagnosis in this patient. Merely, a mass which was described as a tooth which caused a chronic extensive expansion of the sinus and blocked the sinus ostium during operation was determined. In such patients the most convenient treatment option is excision or marsupialization of the mucocele or the extraction of the tooth that lead to a dental pathology.

If not extracted adequately or if left untreated, it may show a tendency to re-generate. If a significant sinus disease is present, then affected sinuses must be treated with

endoscopic sinus surgery to obtain a better result (13). However, some of the authors may prefer to marsupialize such large cysts and mucocele's. In the present case, it was almost impossible to extract the ectopic mature premolar dental mass from the OMC only by using an endonasal route. Therefore, a combination together with a Caldwell-Luc approach was necessary to safely extract a tooth localized at such a sensitive point and to drainage the content of a very big mucocele. Compared to odontogenic keratocysts, recurrence and malign transformation after therapy is more rare in mucocele and dentigerous cysts, but careful and close follow-up and periodical care is essential (3). Our patient was followed for more than 2 years. We monitored an asymptomatic course in our patient demonstrating no any changes in malignity and in ameloblastic state, and recurrence. But we achieved a satisfactory therapeutical conclusion.

CONCLUSION

As it can be observed in our patient, spite to advance diagnostic tools, we may not be capable to definitely diagnose masses that block the OMC before a surgical intervention is carried out. It is necessary to monitor the entire pathology and the lesion and to conduct a combination of a Caldwell-Luc procedure together with endoscopic sinus surgery to obtain an adequate excision. As it can be seen in this patient, localization of an ectopic premolar tooth at a high level and the formation of a mucocele, plus a giant maxillary sinus expansion is a very rarely encountered condition.

REFERENCES

- 1- Goh YH. Ectopic eruption of maxillary molar tooth –an unusual cause of recurrent sinusitis. *Signapure Med J* 2001;42(2):80-1.
- 2- Alves DBM, Pedrosa EFNC, Andreo JC, Carvalho IMM.,Rodrigues AC. Transmigration of mandibular second premolar in a patient with cleft lip and palate. *J Appl Oral Sci.* 2008; 16 (5):360-3
- 3- Srinivasa PT, Sujatha G,Thanvir MN,Rajesh P. Dentigerous cyst associated with an ectopic third molar in the maxillary sinus:A rare entity. *Indian J Dent Res.*2007;18(3):141-3.
- 4- Jayaraj SM, Patel SK, Ghufloor K, Frosh AC. Mucocoeles of the maxillary sinus. *Int J Clin Pract.* 1999;53(5):391-3.
- 5- Lamb JF, Husein OF, Spiess AC. Ectopic molar in the maxillary sinus precipitating a mucocele: a case report and literature review. *Ear Nose Throat J.* 2009 ;88(8):6-11.
- 6- Atherino CC, Atherino TC. Maxillary sinus mucopyoceles. *Arch Otolaryngol.* 1984 ;110(3):200-2.
- 7- Helióvaara A, Ranta R, Rautio J. Dental abnormalities in permanent dentition in children with submucous cleft palate. *Acta Odontol Scand.* 2004;62(3):129-31.
- 8- Di Pasquale P, Shermetaro C. Endoscopic removal of a dentigerous cyst producing unilateralmaxillary sinus opacification on computed tomography. *Ear Nose Throat J.* 2006;85(11): 747-81
- 9- Jude R, Horowitz T, Loree J. A case report. Ectopic molars that cause osteomeatal complex obstruction. *J AmDent Assoc* 1995;126:1655-7.
- 10- Dagistan S, Cakur B, Goregen MA dentigerous cyst containing an ectopic canine tooth below the floor of the maxillary sinus: a case report. *J Oral Sci.* 2007;49(3):249-52.
- 11- Hekimoglu K., Cinar F., Hekimoglu C. Ectopic Localization of Third Molar Tooth in Maxillary Sinus, Causing Postnasal Haemorrhage: Case Report. *Turkiye Klinikleri J Dental Sci* 2009;15(3):220-3.
- 12- Tanimoto Y, Miyawaki S, Imai M, Takeda R, Takano-Yamamoto T. Orthodontic treatment of a patient with an impacted maxillary second premolar and odontogenic keratocyst in the maxillary sinus. *Angle Orthod.* 2005;75(6):1077-83.
- 13- Cedin AC, Paula Junior FA, Landim ER, Silva FL, Oliveira LF, Sotter AC. Endoscopic treatment of odontogenic cyst with intra-sinusal extension. *Rev Bras Otorrinolaringol (Engl Ed).* 2005 ;71(3):392-395.