

Journal of Pediatric Sciences

Tuberculous psoas abscess with Pott's disease in 5 year old child presenting as lower abdominal and pelvic mass.

Vishal Sachchidanand Yadav, Vikas Sachchidanand Yadav

Journal of Pediatric Sciences 2013;5(1):e171

How to cite this article:

Yadav VS, Yadav VS. Tuberculous psoas abscess with Pott's disease in 5 year old child presenting as lower abdominal and pelvic mass. Journal of Pediatric Sciences. 2013;5(1):e171

CASE REPORT

Tuberculous psoas abscess with Pott's disease in 5 year old child presenting as lower abdominal and pelvic mass

Vishal Sachchidanand Yadav, Vikas Sachchidanand Yadav

Abstract:

Psoas abscess in the pediatric population is a rare clinical entity with various etiologies and non-specific clinical presentation, frequently resulting in delayed diagnosis, increased morbidity and prolonged hospitalization. We report a case of a primary psoas abscess with Pott's disease due to Mycobacterium Tuberculosis infection in an immunocompetent 5yr old female child that presented with left lower abdominal pain and a soft tissue mass over the left iliac fossa (LIF) and inguinal regions.

Keywords: Abdominal mass, psoas abscess, tuberculous, percutaneous drainage

Accepted: 12/03/2012 **Published:** 02/01/2013

Corresponding author: Vishal Sachchidanand Yadav, India, vish_yad_123@yahoo.co.in

Introduction

Psoas abscess is regarded as a rare disease in the medical literature [1]. Nowadays, the true incidence is unknown but it has probably increased due to improvements in diagnostic techniques [2]. Psoas abscess may be classified as primary or secondary, depending on the presence or absence of underlying disease. Primary psoas abscess is a rare clinical entity with subtle and non specific symptoms, most commonly seen in immunosuppressed patients or those predisposed to infections. Tuberculous psoas abscess was usually associated to complicate Pott's disease, but it can also be secondary to direct extension from other adjacent structures or haematogenous spread from an occult source.

Case Report

A 5-year-old female child from low socio-economic status with weight 16kg presented with progressive left lower quadrant abdominal pain radiating to the ipsilateral hip and thigh and failure to thrive, since 6 months. Distension of abdomen with left renal angle fullness was noted since 7days. There was also a 2-month history of difficulty in walking. She was pale, anaemic and had toxic look.

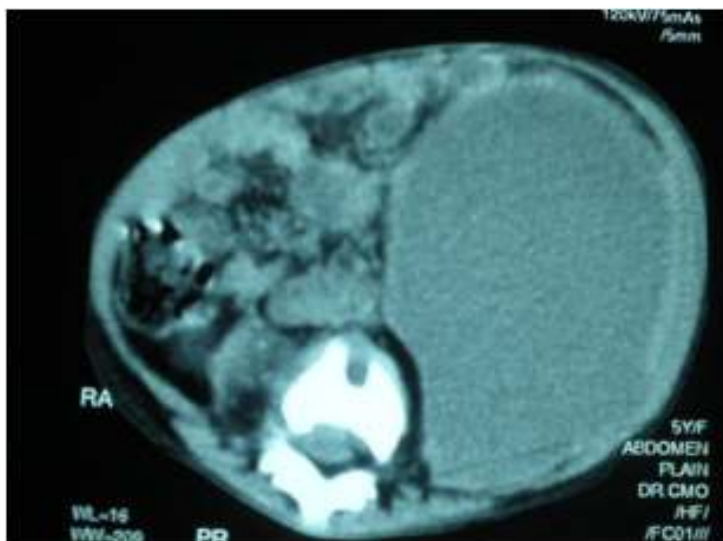
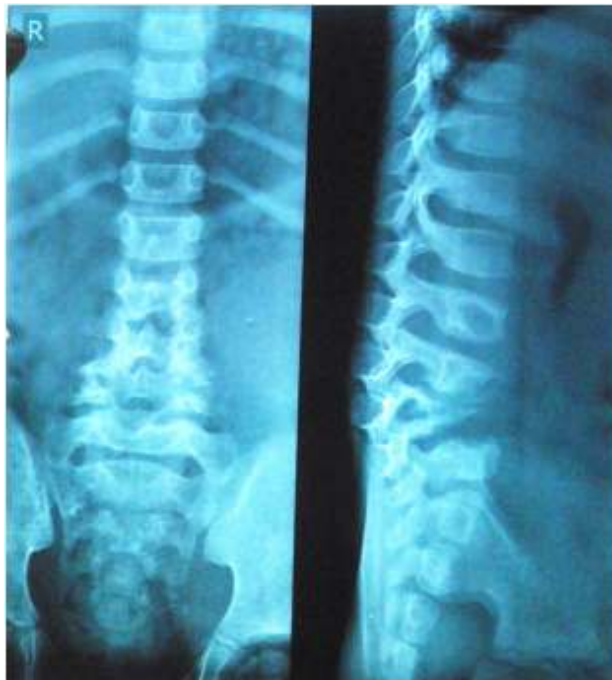According to the mother, the child started limping which gradually worsened. At the time of presentation, the girl was unable to walk and sat only with support. She lay down most of the time with the left hip flexed. She also complains of constipation with hard stools. Her medical history was negative. There was no history of trauma, cutaneous or other infection. The patient denied fever, back pain, gastrointestinal or genitourinary symptoms, weight loss or weakness. The chest was clear on auscultation and no adenopathy was found. She was not vaccinated against Mycobacterium tuberculosis (MTb) with no history of contact. Examination of the LIF and inguinal regions showed a fluctuant, warm, mildly tender mass, measuring 20 x 15 cm. Flexion and external rotation of the ipsilateral hip was painful. The neurological examination was normal. Examination of back revealed posteriorly protruding lumbar vertebral processes without associated spinal tenderness. Blood test showed decreased haemoglobin (6.5 mg/dl) and increased C-reactive protein (1.48 mg/dl), without any others abnormalities. Urine analysis was normal. Serologic HIV testing was negative.

Ultrasonography revealed a large hypoechoic collection with many internal echoes in left lower abdomen, volume

of which was over 900 ml and it was pushing the bladder to the right side and the left kidney laterally and downwards. Colon loaded with stool. The right psoas muscle appeared to be normal.

The computed tomography (CT) that a large hypodense cystic mass measuring 16cm. x 10cm.x 7cm. (sagittal, transverse and antero-posterior). The mass was within left psoas muscle and extended inferiorly into the pelvis and left thigh. The mass showed peripheral enhancement with internal cystic areas (HU 10 to 20) suggestive of abscess. Superiorly the abscess displaced the left kidney upwards,

anteriorly all bowel loops to right and stretched the left abdominal muscles. In thigh femoral vessels were displaced anteriorly. The abscess was crossing the midline in some places. There was another abscess in front of sacrum extending into both gluteal region [Fig 1]. The L5 and S1 vertebrae showed destructive areas with paravertebral abnormal soft tissue abscess. There was epidural soft tissue component displacing the cauda equina posteriorly at the level of L5 to S1. Disc between L5 and S1 was also displaced (Figure 2).



Discussion

The iliopsoas compartment is an extraperitoneal space which contains the iliopsoas and iliacus muscles. The psoas major muscle arises from the transverse processes and bodies of the 12th thoracic and all lumbar vertebrae. Superiorly it passes beneath the arcuate ligament of the diaphragm, proceeds downward across the brim of the lesser pelvis, passes beneath the inguinal ligament and in front of the capsule of the hip joint and ends in a tendon that receives nearly the whole of the fibres of the iliacus muscle and is inserted into the lesser trochanter of the femur. Thus, the space defined by the psoas fascia is a direct communication from the mediastinum to the thigh. It is innervated by the branches of L2, 3, and 4, and it is the primary flexor of the hip joint. The psoas abscess may be classified as primary or secondary, depending on the presence or absence of underlying disease. Since this muscle lies in close proximity to organs such as the sigmoid colon, appendix, jejunum, ureters, abdominal aorta, kidneys, pancreas, spine, and iliac lymph nodes, any underlying disease in these organs can spread secondarily to the iliopsoas muscle [4].

The etiology of primary psoas abscess is unclear, but lymphatic and hematogenous spread of an infectious process from an occult source in the body, often associated with immunosuppressant conditions like diabetes mellitus, renal failure, intravenous drug abuse, human immunodeficiency virus infection, malignancies and other chronic illness or trauma, has been implicated [4]. In the literature, there are other reported causes of primary psoas abscess like brucellosis, trichinosis, typhilitis, pneumococcus or MT [5]. Less frequently, tuberculous psoas abscess can be secondary to direct extension from other adjacent structures, [6] or even haematogenous seeding from a distant site. However, the occurrence of tuberculous psoas abscess as the presenting manifestation of TB, without evidence of active infection elsewhere, has been seldom reported [6-9].

In the majority of these cases, as in our own case, those patients presented subacute or chronic symptoms and good general status. Although fever, abdominal or back pain and limitation of hip joint movements are the classical triad of psoas abscess, it can be presented only in 35% of all patients [3]. Clinical suspicion, radiological study with US and CT, the last considered the gold standard, along with microbiological culture of the pus, are crucial to the diagnosis.

Besides that, ruling out another source of infection in the lung, spine, hip, genitourinary or gastrointestinal tracts

should be also kept in mind. Since no tuberculous disease was found in other organs, this case was considered as a primary psoas abscess. The respiratory tract might have been the route of entry of bacilli and in an adult the reactivation of a quiescent tuberculous focus from an occult source may result in haematogenous spread of bacteria, even in the absence of a predisposing condition.

Treatment of tuberculous psoas abscess involved the use of appropriate antituberculous drugs along with drainage. PCD has been shown to be the first line treatment of abdominal abscess, including tuberculous, which renders surgery unnecessary in many cases [10]. In the presented case, the girl was started on empiric antituberculous treatment after percutaneous abscess drainage, and responded well to it exhibiting normalization. No spinal deformity developed.

References

- 1- Gruenwald I, Abramson J, Cohen O: Psoas abscess: case report and review of the literature. *J Urol* 1992; 147: 1624-26.
- 2- Berge VM, Marie S, Kuipers T, Jansz AR, Bravenboer B: Psoas abscess: report of a series and review of the literature. *Neth J Med* 2005; 63: 413-16.
- 3- Penado S, Espina B, Campo J: Absceso de psoas. Descripción de una serie de 23 casos. *Enferm Infecc Microbiol Clin* 2001; 19: 257-60.
- 4- Mallick I, Thoufeeq M, Rajendran T: Iliopsoas abscesses. *Postgrad Med J* 2004; 80: 459-62.
- 5- Cubukcu S, Gurbuz U, Çevilkol C, Aktan S, Tuncer T. Primary psoas abscess presented with only low back pain. *Turk J Phys Med Rehab* 2006; 52: 137-40.
- 6- Chaoui F: Bilateral tuberculous abscess of the psoas without spinal involvement associated with colonic tuberculosis. *Presse Med* 1987;16:1100-101.
- 7- Mateos A, Monte R, Rodriguez A, Corredoirá J: Primary Psoas abscess caused by Mycobacterium tuberculosis. *Scand J Infect Dis* 1998; 30: 319.
- 8- Harrigan RA, Kauffman FH, Love MB. Tuberculous psoas abscess. *J Emerg Med* 1995;13(4):493-98.
- 9- Chen YC, Chang SC, Hsieh WC, Luch KT, Shen MC: Non-spinal psoas abscess due to Mycobacterium tuberculosis in a patient with acquired immunodeficiency syndrome: a report case. *J Formos Med Assoc* 1994; 9: 433-36.
- 10- Dinc H, Onder C, Turhan AU, Sari A, Aydin A, Yulug G, Gumele HR: Percutaneous catheter drainage of tuberculous and nontuberculous psoas abscesses. *Eur J Radiol* 1996;23(2):130-34.