

# Clinicopathological features of trichoblastomas and malignant variant: trichoblastic carcinoma

Melekber CAVUS OZKAN <sup>1</sup> , Zeliha LEYLA CINEL <sup>2</sup> 

<sup>1</sup> Department of Plastic, Reconstructive and Aesthetic Surgery, School of Medicine, Marmara University, Istanbul, Turkey.

<sup>2</sup> Department of Pathology, School of Medicine, Marmara University, Istanbul, Turkey.

**Corresponding Author:** Melekber CAVUS OZKAN

**E-mail:** melekbero@gmail.com

**Submitted:** 11.02.2021

**Accepted:** 03.03.2021

## ABSTRACT

**Objective:** Trichoblastomas are rare benign tumors of the skin appendages with epithelial and mesenchymal components that exhibit differentiation to the follicular germinative epithelium and particularly to the follicular stroma of the skin. Our aim was to contribute to already limited literature data in order to gain more insights into the treatment and follow-up of patients with this condition.

**Methods and Materials:** A total of 9 patients with trichoblastoma and 1 patient with malignant trichoblastoma were surgically treated between 2016 and 2020 at the Department of Plastic, Reconstructive and Aesthetic Surgery, School of Medicine, Marmara University.

**Results:** Of the 10 patients with trichoblastoma, 5 were female and 5 were male, with a median age of 49 years. The smallest and largest lesion lengths were 0.4 and 2 cm, respectively. Seven lesions had developed in the head and neck region, while 2 were in the trunk. One of our cases was a 45-year old female patient with a malignant trichoblastoma presented with a lesion in the right side of the lower lip.

**Conclusion:** Trichoblastomas are rare tumors that affect both sexes equally and are seen most commonly in the head and neck region. Recurrence rates were found to be low when they were treated with negative surgical margins.

**Keywords:** Skin Neoplasms, Plastic Surgery, Histopathology

## 1. INTRODUCTION

Trichoblastomas are rare benign tumors of the skin appendages with epithelial and mesenchymal components that exhibit differentiation to the follicular germinative epithelium and particularly to the follicular stroma of the skin [1]. Although they may develop at any site harboring hair follicles, the most common site of involvement is the head and neck region [2-5]. Generally, they form plaques, nodules, or papilla. Although, most patients have sporadic lesions, multiple lesions may occur generally in conjunction with Brooke-Spiegler Syndrome or its phenotypic variant, i.e. "multiple familial trichoepithelioma" [6]. The malignant form is even more uncommon, with two morphological types reported: trichoblastic carcinoma and trichoblastic carcinosarcoma.

Histopathologically, trichoblastomas are symmetric lesions with well-defined boundaries that are localized in the dermis.

The tumor consists of basaloid cell islets with occasional areas of palisading cells surrounded by intense follicular fibrotic stroma. It has several subtypes depending on the growth pattern: large nodular, small nodular, cribriform (trichoepithelioma), racemiform, retiform, and columnar (desmoplastic trichoblastoma). It is important to be aware of the presence of these subtypes for successful differential diagnosis. Furthermore, other pathological features may be observed including sebaceous and ductal differentiation, hyaline transformation, and melanocytic hyperplasia. Basal cell carcinoma (BCC), microcystic adnexal carcinoma, and syringoma may be associated with challenges in differential diagnosis, particularly in smaller biopsy samples. BCC, the most common malignant skin tumor, lacks specific follicular stroma. Palisading alignment around the cell islets is more prominent

**How to cite this article:** Ozkan Cavus M, Cinel ZL. Clinicopathological features of trichoblastomas and malignant variant:Trichoblastic carcinoma. Marmara Med J 2021; 34(2):147-151. doi: 10.5472/marumj.943131

and retraction artifacts are present. Immunohistochemical staining showing androgen receptor positivity and lack of Merkel cells which can be detected with cytokeratin 20, favor a diagnosis of BCC, while the opposite favors a diagnosis of trichoblastoma [7].

Our aim was to contribute to already limited literature data in order to gain more insights into the treatment and follow-up of patients with this condition.

## 2. MATERIALS and METHODS

A total of 9 patients with trichoblastoma and 1 patient with malignant trichoblastoma, surgically treated between 2016 and 2020 at the Plastic, Reconstructive and Aesthetic Surgery Department, School of Medicine Marmara University were included in the study. Information such as the site of involvement, therapeutic modalities administered, recurrence rate, and presence of concomitant skin tumors was retrieved from patients' records and pathology reports. All patients underwent excisional biopsy with total tissue sampling. Following routine tissue preparation, the cross-sections were stained with Hematoxylin and Eosin. If required, additional cross-sections were prepared and immunohistochemical studies were performed to aid in the differential diagnosis.

Excisional biopsy was performed in all lesions. Due to narrow surgical margins, two patients underwent re-excision. Since, trichoblastoma is a rare tumor of the skin appendage, its treatment is relatively obscure. The mean duration of follow-up in our patients was 33 months. Absence of recurrences, including the three patients with longest follow up (53, 55, and 62 months, respectively), suggests that excision with negative surgical margins may suffice for treatment.

The study was conducted in accordance with the principles of the Declaration of Helsinki. This study was approved by the Marmara University, School of Medicine, Ethics Committee (Approval number: 08.05.2020; 09.2020.530).

### Statistical Analysis

Statistical analysis was performed using the SPSS version for Windows 15.0 software (SPSS Inc., Chicago, IL, USA). Continuous variables were expressed in mean  $\pm$  standard deviation (SD), median (min-max), while categorical variables were expressed in number and percentage. The unpaired *t*-test was used to compare continuous random variables between the time periods, while the chi-square test was used to compare discrete random variables. A *p* value of  $<0.05$  was considered statistically significant.

## 3. RESULTS

Of the 10 cases with trichoblastoma, 5 were female and 5 were male, with a median age of 49 years. Seven patients were less than 60 years of age, while 2 were  $\geq 60$  years of age. The smallest and largest lesion lengths were 0.4 and 2 cm, respectively. Seven lesions had developed in the head and neck region, while 2 were

in the trunk. In one case, trichoblastoma in association with concomitant syringocystadenoma papilliferum had developed on the background of a sebaceous nevus. Also, three patients had concomitant BCC, poroma, and seborrheic keratosis, one in each respectively. A negative surgical margin was considered to indicate adequate treatment. However, resection was done in 2 patients, due to deep or lateral continuation, one each respectively. The mean duration of follow up was  $33.44 \pm 15.48$  months. The clinical characteristics of the patients are shown in Table I. Histopathologically 8 lesions were localized in the superficial dermis, had well-defined margins, and contained basaloid cell groups and specific follicular stroma in their surroundings (Figure 1). With regard to growth pattern, the most common subtype was the nodular subtype, with 5 patients having double or triple patterns such as small nodular, cribriform, racemiform and retiform types. It was interesting to note the presence of melanin pigment in two patients. No patients had recurrence.

One of our cases differed slightly from the others. This case was a 45-year old female patient with a history of malignant trichoblastoma who presented with a lesion in the right side of the lower lip that had existed for a one-year period with accelerated growth within the past 3 months. The lesion was 1 cm in length and had a nodular appearance (Figure 2). A pre-diagnosis of BCC was made and the patient underwent excisional biopsy with a 2-mm surgical margin. Due to a pathological diagnosis of malignant trichoblastoma, re-excision with wedge excision was carried out with a surgical margin of 1 cm. Cervical computed tomography did not show any lymph node metastases. In histopathological examination, the tumor consisted of small nodules with significant follicular differentiation that infiltrated into the subcutaneous tissue and superficial muscles. The perineural invasion observed in one field facilitated the diagnosis of malignancy (Figure 3). The patient was followed up for 36 months and no recurrence was detected.

## 4. DISCUSSION

In the current study, the largest lesion was 2 cm. However, patients with lesions of up to 6 cm have also been reported [8]. Trichoblastomas are papule or nodule like lesions that are generally less than 2 cm in diameter. The lesions are generally the same color as the skin. Less frequently, brown-black colored pigmented forms that can be clinically mistaken for malignant melanoma or pigmented BCC have also been reported [5, 9]. In our patient series, although, two patients had focal melanin pigment microscopically, no cases had clinical pigmentation. Lesions the same color as the skin were more likely to be confused with BCC.

It has been reported that both trichoblastoma and malignant trichoblastoma may develop on the background of sebaceous nevus, and such lesions are generally larger and more heavily pigmented [10,11]. One of our patients also had a lesion that developed on the background of sebaceous nevus, although, with no pigmentation. This lesion was accompanied by

syringocystadenoma papilliferum that also developed on the background of sebaceous nevus. Syringocystadenoma papilliferum is a benign tumor of the skin appendage that frequently develops on sebaceous nevi. Total excision and primary repair were performed for these sebaceous nevi with negative surgical margins.

Although published literature suggests that trichoblastomas mostly occur in subjects over 60 years of age, an 11 year old pediatric patient has also been reported [12]. In our study, the median age was 49 years, with only two patients being older than 60 years of age, and the youngest patient was 16 years old. With regard to gender distribution, there were 5 male and 5 female patients. Again, in line with the published data, 7 of the lesions (77.77%) were in the head and neck region [13]. Although, more frequent occurrence in this region suggests that UV light may play an etiological role, definitive evidence for this hypothesis is lacking.

Malignant trichoblastoma has only been described in case reports in the literature. Pigmented forms such as trichoblastomas and giant forms have also been reported [14,15]. As in our patients, these lesions mostly affect the head and neck region [16] and the elderly, although, other locations such as the abdomen [17] and the paraspinous area [18] may also be involved.

The histopathology of malignant trichoblastoma consists of an epithelial component that is surrounded by special follicular stroma, as in the benign form, although, it has also moderate or marked atypia. On the other hand, in trichoblastic carcinosarcoma, both components are of malignant nature. Our patient had well – differentiated trichoblastic carcinoma that displayed pronounced follicular differentiation. Although predisposing factors have not been fully elucidated, lesions developing on the background of trichoblastoma have been reported [19], with a more aggressive clinical course. Our patient lacked the benign trichoblastoma component. Also, other 9 patients with trichoblastoma did not have malignant transformation.

As this tumor is very rare, no treatment principles have been established. The therapeutic option may be determined on the basis of the tumor stage. A screening for metastatic lesions is recommended, as patients with lymphatic or hematogenous spread have been reported [20]. The primary form of treatment reported in the literature involves surgical excision. There is no clear-cut consensus regarding the surgical margins, with some studies reporting excisions ranging between 0.5 cm and 1.5 cm [13-15]. In our patient, excision was performed to achieve a surgical margin of 1 cm, with primary repair. Since, the screening for metastatic lesions was negative, no additional treatments were administered. However, some authors opted for radiotherapy even in non-metastatic patients [21]. Our patient was followed up every 3 months in the first year, and by bi-yearly exams thereafter, as the lesion was small, pathological stage was low (pT1), and surgical margins were extended. No recurrence or lymphatic/hematogenous metastases were detected at the end of 36 months' of follow-up.

Trichoblastomas are rare tumors originating from hair follicles and their malignant forms have been reported even less frequently. In this study, our aim was to contribute to already limited literature data in order to gain more insights into the treatment and follow-up of patients with this condition. Recurrence rates were found to be low when they were treated with negative surgical margins.

Table I. Demographic features of patients

No	Sex	Age	Localization	Size (cm)	Accompanying tumor	Follow-up (month)
1	Female	32	Left medial canthus	0,5	BCC	16
2	Male	41	Left upper eyelid	0,4	-	16
3	Male	78	Left deltoid	0,6	Poroma	23
4	Male	49	Nasal dorsum	0,6	Seborrheic keratosis	28
5	Female	49	Left nasolabial fold	0,5		29
6	Male	51	Trunk	2		55
7	Male	34	Right nasolabial fold	0,6		53
8	Female	64	Left temporal	1,3	Syringocyst-adenomacystoma	62
9	Female	16	Nasal dorsum	0,5		19
10	Female	45	Lower lip	1		36

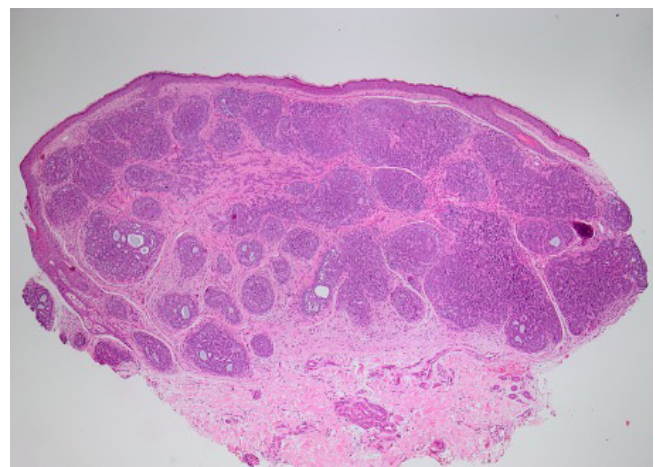
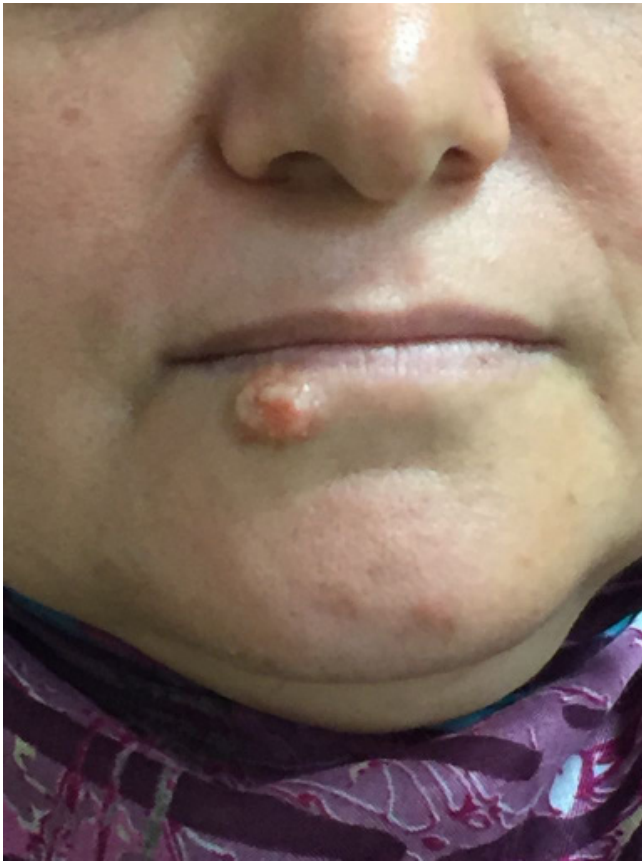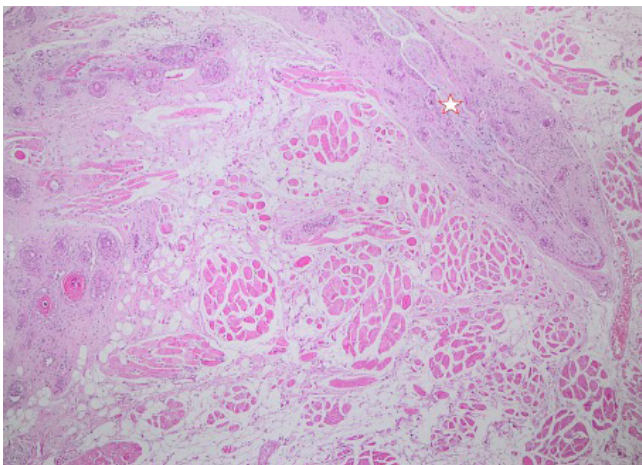


Figure 1. Well – circumscribed basaloid cell groups and the surrounding fibrotic stroma in the dermis. Large nodular and cribriform growth patterns are seen. H&Ex40



**Figure 2.** Nodular lesion at the right of the lower lip diagnosed as malignant trichoblastoma.



**Figure 3.** Subcutaneous fat tissue and perineural invasion of malignant trichoblastoma (Shown with star). H&Ex40

### Compliance with Ethical Standards

**Ethical approval:** The study was conducted in accordance with the principles of the Declaration of Helsinki. This study was approved by the Marmara University, School of Medicine, Ethics Committee (Approval number: 08.05.2020; 09.2020.530).

**Financial support:** The authors have no relevant financial information to disclose.

**Conflict of interest:** The authors have no potential conflicts to declare.

### Authors' contributions

Conception and design of the study, data collection and writing: MCO and ZLC, Analysis and interpretation of data: MCO, Editing: ZLC. Both authors read and approved the final version of the article.

### REFERENCES

- [1] Headington JT. Differentiating neoplasms of hair germ. *J Clin Pathol* 1970;23:464-71. doi: 10.1136/jcp.23.6.464
- [2] Eshraghi B, Riazi-Esfahani H, Katoozpour R, Anvari P, Mortazavi M, Amoli FA. Trichoblastoma of the upper eyelid. *J Ophthalmic Vis Res* 2017;12 :219-21. doi: 10.4103/2008-322X.205378.
- [3] Landolsi A, Khaled A, Bougacha L, et al. Giant trichoblastoma of the scalp. *Tunis Med* 2011;89:569-72.
- [4] Pina A, Sauthier P, Rahimi K. Vulvar trichoblastoma: case report and literature review. *J Low Genit Tract Dis* 2015;19:e10-2. doi: 10.1097/LGT.000.000.0000000010.
- [5] Sathyaki DC, Riyas M, Roy MS, Swarup RJ, Raghu N. Pigmented trichoblastoma of nose: An unusual occurrence. *J Clin Diagn Res* 2017;11:Md09-md10. doi: 10.7860/JCDR/2017/25798.10321.
- [6] Cakmak Genc G, Dursun A, Nagy N, Celikmakas A, Acuner B. Brooke-Spiegler Syndrome: Two patients from a Turkish family with multiple familial trichoepithelioma. *Am J Dermatopathol* 2019;41:778-80. doi: 10.1097/DAD.000.000.0000001265.
- [7] Kutzner H KS, Kanitakis J, Kazakov DV, Schulz T, Singh R. Trichoblastoma In: Fred T. Bosman ESJ, Lakhani SR, Ohgaki H, editors. *World Health Organization Classification of Tumours*. 1. 4th ed. France: International Agency for Research on Cancer (IARC), 2018:201-2.
- [8] Morillo V, Manrique P, Vildósola S, Saiz A, Artola JL, Bilbao I. [Giant trichoblastoma]. *Actas Dermosifiliogr* 2006;97:467-9. doi: 10.1016/s0001-7310(06)73443-3.
- [9] Quist EE, DiMaio DJ. Melanotrichoblastoma: a rare pigmented variant of trichoblastoma. *Cutis* 2017;100:243-6.
- [10] Cho HK, Song JS, Kang WH, Ro BI. Pigmented trichoblastoma arising from the nevus sebaceous: a rare case in Korea. *Ann Dermatol* 2009;21:406-8. doi: 10.5021/ad.2009.21.4.406.
- [11] Misago N, Narisawa Y. Tricholemmal carcinoma in continuity with trichoblastoma within nevus

- sebaceous. *Am J Dermatopathol* 2002;24:149-55. doi: 10.1097/00000.372.200204000-00008.
- [12] Kang TW, Kang H, Kim HO, Song KY, Park YM. Trichoblastoma in a child. *Pediatr Dermatol* 2009;26:476-7. doi: 10.1111/j.1525-1470.2009.00960.x.
- [13] Hua C, Velter C, Osio A, et al. Locally aggressive trichoblastic tumours (low-grade trichoblastic carcinomas): clinicopathological analysis and follow-up. *Acta Derm Venereol* 2018;98:126-7. doi: 10.2340/00015.555.2678.
- [14] Datiashvili RO, Izadi K, Centurion SA, Lambert WC, Scarpidis U. Malignant melanocytic trichoblastoma. *Ann Plast Surg* 2006;56:208-10. doi: 10.1097/01.sap.000.019.4243.85311.a1.
- [15] Lee JS, Kwon JH, Jung GS, et al. A giant trichoblastic carcinoma. *Arch Craniofac Surg* 2018;19:275-8. doi: 10.7181/acfs.2018.02124.
- [16] Leblebici C, Özkur E, Gürel MS, Aksu AEK, Savaş S, Kiremitçi Ü. Rare case of trichogenic tumor: trichoblastic carcinoma. *Istanbul Med J* 2016;17:32-4.
- [17] Lahbali O AM, Tbouda M, Bourhoum N, Znati K, Mahassini N. Rare location of a trichoblastic carcinoma: A case report. *Austin J Dermatolog* 2017;4:1075.
- [18] Laffay L, Depaepe L, d'Hombres A, Balme B, Thomas L, De Bari B. Histological features and treatment approach of trichoblastic carcinomas: from a case report to a review of the literature. *Tumori* 2012;98:46e-9e. doi: 10.1700/1088.11948.
- [19] Fusumae T, Tanese K, Takeuchi A, et al. High-grade trichoblastic carcinoma arising through malignant transformation of trichoblastoma: Immunohistochemical analysis and the expression of p53 and phosphorylated AKT. *J Dermatol* 2019;46:57-60. doi: 10.1111/1346-8138.14686.
- [20] Schulz T, Proske S, Hartschuh W, Kurzen H, Paul E, Wunsch PH. High-grade trichoblastic carcinoma arising in trichoblastoma: a rare adnexal neoplasm often showing metastatic spread. *Am J Dermatopathol* 2005;27:9-16. doi: 10.1097/01.dad.000.014.2240.93956.cb.
- [21] Kazakov DV, Banik M, Kacerovska D, Michal M. A cutaneous adnexal neoplasm with features of adamantinoid trichoblastoma (lymphadenoma) in the benign component and lymphoepithelial-like carcinoma in the malignant component: a possible case of malignant transformation of a rare trichoblastoma variant. *Am J Dermatopathol* 2011;33:729-32. doi: 10.1097/DAD.0b013e31820b7b87.