

ISOLATED TRANSVERSE SACRUM FRACTURE AND ITS IMPLICATIONS: A CASE REPORT

S.Kağan Başarslan , Mehmet Zileli***

**Department of Neurosurgery, Faculty of Medicine, Mustafa Kemal University, Hatay, Turkey*

***Department of Neurosurgery, Faculty of Medicine, Ege University, İzmir, Turkey*

Abstract

Fractures of the sacrum are uncommon and generally associated with fracture of the pelvis. Transverse fractures of the sacrum are even less frequent, and neurological deficit may accompany these fractures. A case of transverse fracture sacrum with cauda equina injury treated lately by sacral laminectomy and S1, S2 root decompression, is reported. Since the first case report of sacral fracture with injury to cauda equine, there have been sporadic reports of such fracture in the literature. We report an unusual case of transverse sacral fracture with neurological damage, which presented to our clinic after four months of injury.

Key Words: Transvers fracture, trauma, spinal injury, sacrum

Geliş Tarihi / Received: 13.02.2014,
Kabul Tarihi / Accepted: 23.03.2014

INTRODUCTION

Transvers sacral fracture (TSF) is rare injuries of the spine. It is also uncommon among sacral fractures, and occurs in 2 to 5% of total sacral fractures (1). The most common mechanism is a fall from a height, the lower extremities hit the ground in extreme flexion, and the sacrum is the direct touchdown point. The direct impact on the sacrum and the vertical extrusion energy through the spinal column may be the main mechanism of injury. Therefore, Roy- Camille and colleagues who are classified these fracture names them as suicide jumper's fracture (2).

In contrast to vertical fractures of the sacrum, which are the more common, TFSs are frequently associated with neurologic injury and often missed on initial radiologic investigations (3). Delay in diagnosis and treatment can lead to unacceptable neurologic deterioration and pain. As it is difficult to detect on anteroposterior view pelvic radiograph due to angulation of the fracture and bowel shadow. When clinical signs suggested a possible a sacral fracture, a computed tomography scan with coronal and sagittal reconstruction can provide optimal imaging to identify and evaluate the sacral fracture.

A highly unstable and neurological injury, the isolated TSF without pelvic ring fracture but combined with cauda equine is rarely encountered in most clinics, and its treatment method remains unclear. A limited number of cases with TSF have been reported in the literature in small case series (4). Our study describes a case of TSF diagnosed and managed medically at first in the other hospital, and lately was treated surgically with sacral decompression plus bilateral lumbosacral stabilization using pedicle screws.

CASE

A nineteen year-old female was jumped from a balcony of fourth story of the apartment for suicide attempt. Immediately after the fall on initial examination, she was disclosed to have saddle anesthesia, total bladder and bowel incontinence, poor anal tonus, with no appreciable motor weakness

in the lower limbs. After being conservatively hospitalized and followed-up for a while at a different hospital, the patient showed no recovery at the end of 4 months following injury. Then, she referred to our clinic with a mainly complaint of low back pain, which is exacerbated by standing erect, and is alleviated with lying supine more than prone and sitting in addition to neurological deficit at the beginning of her injury.

Computed tomography of sacrum revealed a TSF with anterior displacement through first and second sacral vertebrae without vertical fracture of the foramina, and pelvis. For this reason, this case was called as an isolated transverse fracture (Fig.1). Axial CT scanning revealed a depressed S1–2 fractures with significant narrowing of the sacral canal (Fig. 2a,b). On a sagittal CT (Fig. 2a) we observed obvious sacral angulation and significant sacral canal stenosis caused anteriorly by the depressed sacral fracture. Magnetic resonance imaging showed sacral fracture with anterior displacement of the distal fragment with effacement of the thecal sac at S2 level.

Surgical technique – Because of the degree of canal narrowing and clinical findings of significant instability, patient was taken up for surgery. We decided that the best treatment option was decompression of the sacral nerve roots and posterior lumbosacral fixation. A midline incision from L4 to S3 was made and the paraspinal musculature was subperiosteally dissected off the posterior elements of L4 through S3. Under fluoroscopy guidance, screws were placed through both L5 pedicles and the S1 pedicle. A laminectomy from L5 through S3 was performed with full decompression of all sacral roots. Sacral laminectomy at the level of S1-2 showed anterior displacement of the upper fragment and posterior angulation at fracture site and there was complete avulsion of S1,2,3 nerve roots on both side. The patient was allowed to be mobilized as tolerated without any orthosis in the immediate postoperative period. Postoperative period was uneventful as regard wound healing. At the six months follow-up visit, there was no lumbar or pelvic pain during ambulation or in the resting position. But, Sexual dysfunction, bladder and bowel incontinence was still present.

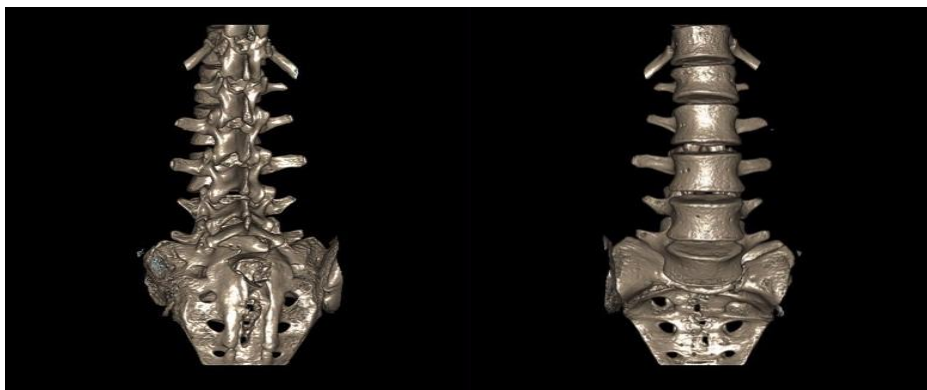


Figure 1. Three dimensional CT imaging displays lamina fractures (a) of S1-S2 level with no marked dissociations (b).

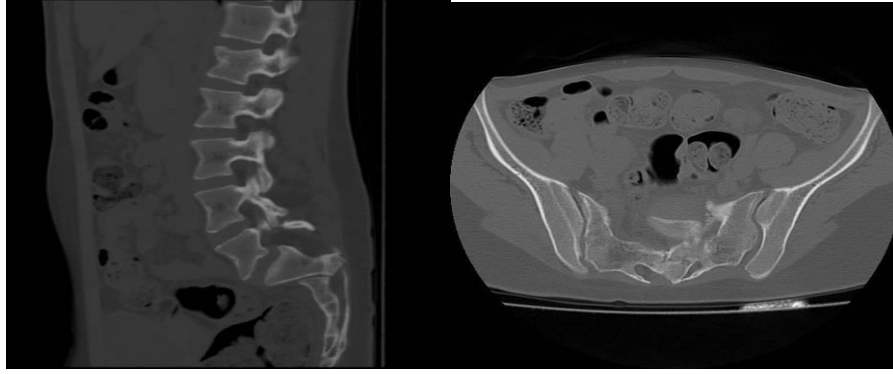


Figure 2. Sagittal (a) and axial CT (b) scan showing that the spinal canal is significantly narrowed secondary to anteriorly dislodged of distal sacrum, which has invaginated into the canal.

DISCUSSION

TSF are usually due to direct injury, which often result in angular deformity and displacement of distal fragment producing neurological damage. These fractures have been classified as upper and lower fractures. Upper sacral transverse fracture results from flexion injury involving usually slippage of S1 on S2 as in the case. They are often associated with vertical fracture through foramina and fracture transverse process of lumbar vertebrae (2,5).

Neurological dysfunction, very common in TSFs, can be the result of transection, contusion, and compression and traction of sacral nerve roots. Nerve root injury secondary to direct compression is associated with a chance of recovery (6). Neurological dysfunction in cases of TSF is thought to be secondary to compression of nerve roots at the site of fracture displacement or angulation. When we carefully examine the sagittal CT reconstructions and axial CT scans, we can deduce that if the depressed lamina fracture were not present, the spinal canal dimensions would not be narrowed, and thus compression of the nerve roots would have been unlikely. Depressed lamina fractures are rare and are generally caused by hyperextension or direct local trauma over the posterior aspect of the spine. Because of the mechanism of the accident and radiological findings associated with superficial location of sacral laminae in our case, we concluded that the local trauma sustained in the sacral area produced the TSF and the associated depressed lamina fracture.

TSF is difficult to detect, especially in cases, which neurological deficit is absent. The saddle anesthesia, loss of bladder function, and loss of rectal sphincter tone may be unrecognized during the initial treatment of severe trauma or may somehow be overlooked because of the presence of associated severe pain (1,7). Sagittally reconstructed CT scans are essential for the diagnosis and evaluation of TSF.

Neurological recovery in these types of fractures is slow, usually taking months to resolve. Ebraheim et al. reported on four patients with neurological dysfunction who underwent surgery 1 to 16 days after the injury (mean 6.2 days). Neurological recovery began to occur 6 weeks in most patients and plateaued at approximately 6 months. The early neurological recovery in patients suggests that expeditious decompression of the sacral nerve roots in cases of TSF leads to earlier recovery than

conservative treatment (7). In our case, there was no improvement on the patient's neurological status but pain-free mobility has increased. This situation was attributed to surgery in the late period.

Currently, the treatment of TSFs with associated neurological dysfunction remains controversial. Whereas some authors advocate conservative treatment (8,9), others encourage undertaking decompressive surgery (2,10,11). Decompression in TSF is easier to perform in the acute period. Because of the anatomical characteristics of the lower sacral region, stabilization procedures should be considered in patients with high region TSF, especially those associated with a vertical fracture (an H-type fracture). TSF stabilization in low region is not necessary because the involved portion of sacrum is not part of the weight transmission from the lower limbs to the spine (12).

Sacral laminectomy is indicated after a trial of conservative treatment in case of neurological deficit. Results of operative decompression are debatable and even conservative treatment has been advocated. However, in case of sacral root injuries with displaced sacrum fracture decompression is warranted, as the neurological deficit may not only be due to root avulsion as in the present case but also as a result of nerve stretching. The bony prominence has also been found to be causing difficulty in sitting, and sacrodynia or gibbectomy is especially indicated in such cases (13,14). In our patient, we decided to perform a lumbosacral fixation due to several reasons: there was L5-S1 lumbosacral instability and also severe compression of the sacral nerve roots with neurological deficits was present. Decompression was definitely justified. Additionally, this type of construct would allow early weight bearing with full mobilization.

CONCLUSION

A previously unreported type of TSF is presented. The patient's neurological outcome after expeditious decompressive surgery underscores the importance of an early diagnosis and treatment in patients with these injuries. Early surgical management and reconstruction of TSF seems to be a better treatment option.

REFERENCE

1. Dussa CU, Soni BM: A hidden injury. *Emerg Med J* 21: 390–391, 2004
2. Roy-Camille R, Saillant G, Gagna G, Mazel C. Transverse fracture of the upper sacrum. Suicidal jumper's fracture. *Spine*. 1985;10(9):838–845.
3. Gribnau AJ, van Hensbroek PB, Haverlag R, Ponsen KJ, Been HD, Goslings JC. U-shaped sacral fractures: surgical treatment and quality of life. *Injury*. 2009; 40(10): 1040-1048.
4. Fountain SS, Hamilton RD, Jameson RM. Transverse fractures of the sacrum: a report of six cases. *J Bone Joint Surg* 1977;59:486-489.
5. Harma A, Inan M, Ertem K. Isolated zone III vertical fracture of first sacral vertebra—a case report. *Acta Orthopaedica*. 2005;76(3):451–452.
6. Vaccaro AR, Kim DH, Brodke DS, Harris M, Chapman JR, Schildhauer T, et al: Diagnosis and management of sacral spine fractures. *Instr Course Lect* 53:375–385, 2004
7. Ebraheim NA, Biyani A, Salpietro B: Zone III fractures of the sacrum. A case report. *Spine*

- 21:2390–2396, 1996
8. Fountain SS, Hamilton RD, Jameson RM: Transverse fractures of the sacrum. A report of six cases. *J Bone Joint Surg Am* 59: 486–489, 1977
 9. Phelan ST, Jones DA, Bishay M: Conservative management of transverse fractures of the sacrum with neurological features. A report of four cases. *J Bone Joint Surg Br* 73:969–971, 1991
 10. Zelle BA, Gruen GS, Hunt T, Speth SR: Sacral fractures with neurological injury: is early decompression beneficial? *Int Orthop* 28:244–251, 2004
 11. Hessman M, Degreif J, Mayer A, Atahi S, Rommens PM: Transverse sacral fracture with intrapelvic intrusion of the lum- bosacral spine: case report and review of literature. *J Trauma* 49:754–757, 2000
 12. Kim MY , Reidy DP , Nolan PC, Finkelstein JA: Transverse sacral fractures: case series and literature review. *Can J Surg* 44: 359–363, 2001
 13. Schildhauer TA, Josten Ch, Muhr G. Triangular osteosynthesis of vertically unstable sacrum fractures: a new concept allowing early weight-bearing. *J Orthop Trauma*. 2006; 20(1 Suppl): S44-51.
 14. Schildhauer TA, Ledoux WR, Chapman JR, Henley MB, Tencer AF, Routt ML Jr. Triangular osteosynthesis and iliosacral screw fixation for unstable sacral fractures: A cadaveric and biomechanical evaluation under cyclic loads. *J Orthop Trauma*. 2003; 17(1): 22-31.