

## Treatment of postoperative atelectasis with dornase alpha (Pulmozyme®) after congenital heart surgery

Mustafa Hakan Zor<sup>1</sup>, Abdullah Ozer<sup>1\*</sup>, Huseyin Demirtas<sup>1</sup>, Yigit Kilic<sup>1</sup>, Baris Mardin<sup>1</sup>

### Abstract

One year old patient followed with tetralogy of fallot (TOF) was admitted to our service for surgical repair. Ventricular septal defect (VSD) was repaired with a Dacron patch. The infundibular muscle was resected to allow for unobstructed flow of blood to the pulmonary valve and the area above the pulmonary valve was opened with a polytetrafluoroethylene (PTFE) patch. The patient was intubated three times because of the atelectasis occurred in the lungs after the surgery. Atelectasis was treated with nebulised dornase alpha. It avoided the recurrence of atelectasis and the patient was discharged

**Key words:** Atelectasis, Dornase Alpha (Pulmozyme), Congenital Heart Surgery

### Introduction

The prevalence of congenital heart disease (CHD) is between 8 and 10 children per 1000 live births. The average number of cardiovascular surgeries for CHD that are necessary in Brazil is of the order of 23,077 procedures per year, including newborn babies with CHD and cases requiring reoperations (1). Pulmonary complications of postoperative pediatric cardiac surgery observed in the study of Felcar et al. where: atelectasis, pneumonia, pleural effusion, pneumothorax, chylothorax, pulmonary hypertension, pulmonary haemorrhage and diaphragmatic paralysis, whereas the first two aforementioned complications are the more common ones (2). Atelectasis, defined as collapse of a certain region of the lung parenchyma (3) is the most common complication in the postoperative period of cardiac surgery (4) by worsening oxygenation, decreasing pulmonary compliance, leading to inhibition of cough and pulmonary clearance and may lead to respiratory failure and increase pulmonary vascular resistance. Heart surgeries associated with CPB have as adverse effect the increased capillary permeability that causes edema, which results in decreased lung compliance and gas exchange (6), in addition to lead to airway obstruction, atelectasis, decreased functional residual capacity and, therefore, hypoxemia (5). Pulmonary complications are the most common causes of morbidity and mortality in the postoperative period after congenital heart surgery. Both mechanical and gas exchange abnormalities result in increased ventilator requirements, intensive care unit (ICU) stay and mortality.

Parenchymal lung disease can be caused by a variety of conditions including nosocomial pneumonia, atelectasis and use of cardiopulmonary bypass. Direct surgical trauma to the respiratory system can result in diaphragmatic paralysis, chylothorax, subglottic stenosis or vocal cord paralysis. Disturbances in the pulmonary vasculature can also trigger complications including pulmonary embolism, plastic bronchitis and even pulmonary hypertensive crises in certain at risk populations (7).

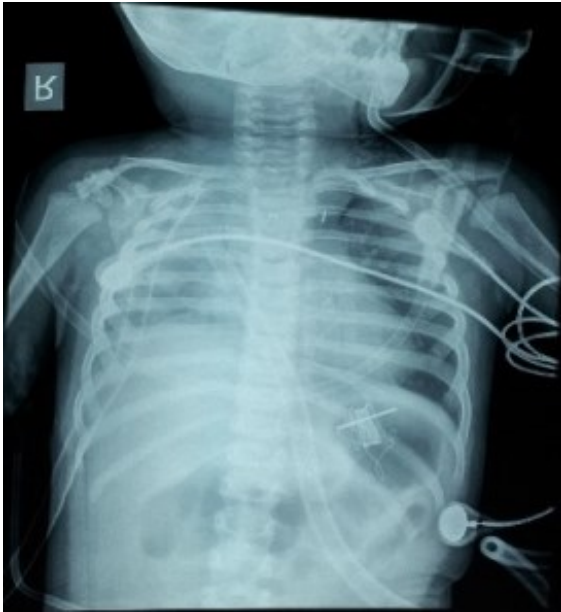### Case

One year old female patient followed with tetralogy of fallot (TOF) was admitted to our service for surgical repair. Her weight was eight kilograms. She was diagnosed with TOF in utero by fetal echocardiography at 27 weeks of gestation. After birth her echocardiography and cardiac catheterization findings were intact Interatrial septum, sub aortic ventricular septal defect, dextroposed aorta, right ventricular hypertrophy, hypo-plastic pulmonary artery and dilated ascending aorta. Total correction of TOF was decided. VSD was repaired with a Dacron patch. The infundibular muscle was resected to allow for unobstructed flow of blood to the pulmonary valve and the area above the pulmonary valve was opened with a PTFE patch. On the first postoperative day when she met extubation criteria she was extubated. 6 hours after extubation she had difficulty in breathing. Her arterial blood gas was analysed. She had respiratory acidosis and she was re-entubated.

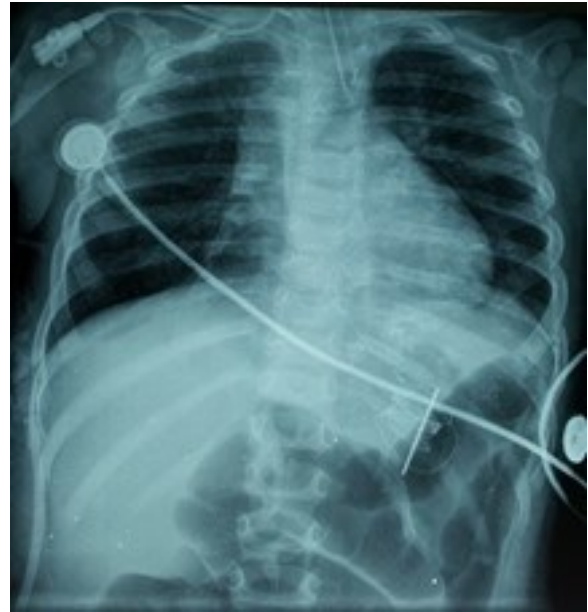Received: 08-04-2015, Accepted 27-04-2015, Available Online 01-06-2015

<sup>1</sup>Gazi University Faculty of Medicine, Department of Cardiovascular Surgery, Ankara, Turkey

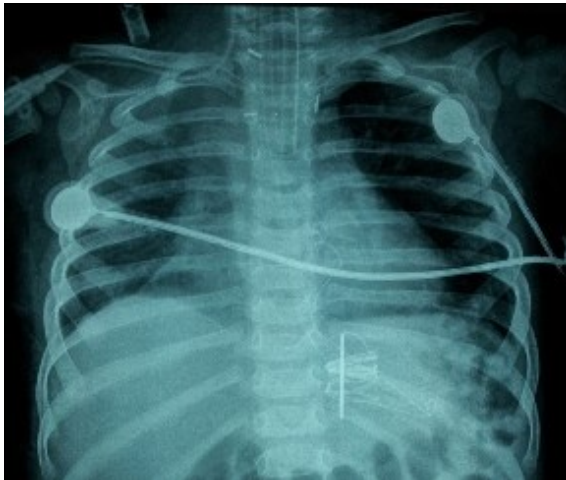\*Corresponding Author: Abdullah Ozer E-mail: [dr-abdozer@hotmail.com](mailto:dr-abdozer@hotmail.com)



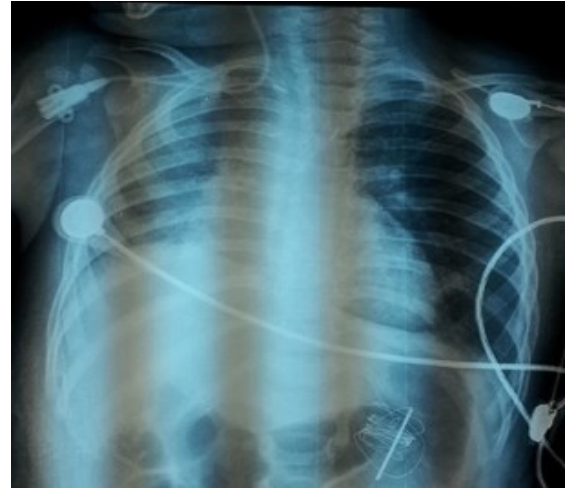
**Figure 1:** Postoperative day 1, chest x-ray with total atelectasis of the right lung. The patient was intubated



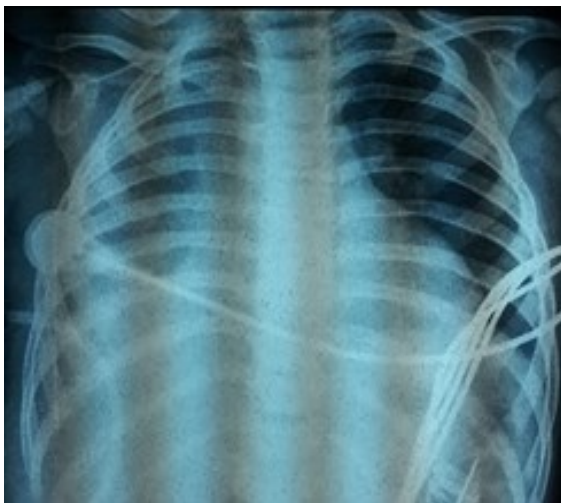**Figure 4:** Postoperative day 4, atelectasis of the right lung recovered and then the patient was ex-tubated



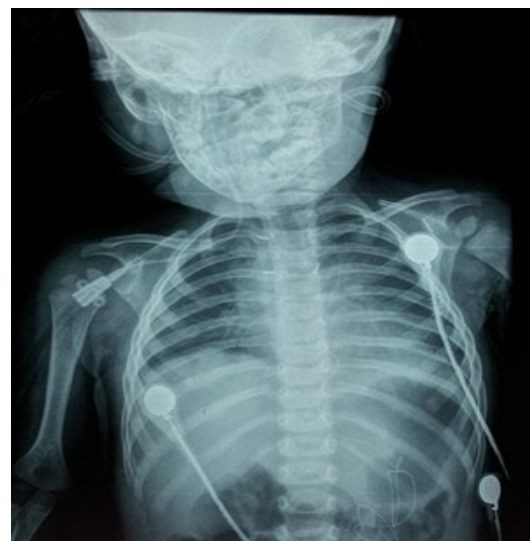**Figure 2:** Postoperative day 2, atelectasis of the right lung recovered and then the patient was ex-tubated.



**Figure 5 -** Postoperative day 5



**Figure 3:** Postoperative day 3, partial collapse of the right lung (recurrent atelectasis) the patient was re-entubated. Pulmozyme treatment was started.



**Figure 6 -** Postoperative day 6

The chest x ray showed total atelectasis of the right lung. After 17 hours of intubation the atelectasis of the right lung totally recovered on chest x ray. The patient was extubated again. Pulmonary rehabilitation techniques and bronchodilators were used for the treatment of atelectasis. After nine hours she had difficulty in breathing again. She had bradycardia, her oxygen saturation level was at 50% and she was intubated again.

Her chest x ray showed total atelectasis of the right lung. After 15 hours she was extubated again. We started to treat the patient with nebulised Dornase alpha (Pulmozyme®) twice a day. Pulmozyme is a recombinant human deoxyribonuclease I (rhDNase) an enzyme which selectively cleaves DNA. Each ampule has 2.5 mL of the solution. Each mL of aqueous solution contains 1 mg dornase alfa. After administration of 2.5 mg of Dornase alpha twice a day for three days the atelectasis of the right lung started to recover. The patient was discharged from the Intensive Care Unit (ICU) and was followed in the clinic. She was treated with Dornase alpha for three more days in the clinic and then on the fifth day she was discharged from the hospital.

## Discussion

Atelectasis resolves with the use of non-invasive mechanical ventilation but after the extubation, by the effect of the spontaneous breathing, lung starts to collapse. Postoperative pain management is important in patients who undergo open heart surgery and aorta surgery. The use of opioid-based analgesics for pain control after cardiac surgery is inevitable. Poorly controlled pain also contributes to hemodynamic instability (8). In fact, several authors have reported that a continuous positive airway pressure, with or without intermittent positive pressure ventilation, alleviates a tracheal collapse (9,10).

Pulmozyme is a nebulised form of recombinant human DNase I (rhDNase). It is reliable, non-invasive and FDA approved. Recombinant human DNase I (rhDNase) has been shown to depolymerise DNA and thereby reduce the in vitro viscoelasticity of sputum in patients with cystic fibrosis and improved pulmonary function in patients with cystic fibrosis (CF) (11).

Its efficacy has been well documented in cystic fibrosis, whereas case reports have described a beneficial effect in other respiratory disorders. Recombinant human DNase I (rhDNase, Pulmozyme, dornase alpha) has been approved for the management of CF (12,13).

## Conclusion

In conclusion, nebulised form of Dornase Alpha (Pulmozyme®) has a positive effect on morbidity and mortality in patients with atelectasis that do not resolve due to pulmonary medication and rehabilitation program after congenital heart surgery

**Conflict of Interest:** The authors declare no potential conflicts of interest with respect to the research, authorship, and/or publication of this article.

## References

1. Pinto Jr VC, Daher CV, Sallum FS, Janete MB, Croti UA. Situação das cirurgias cardíacas congênitas no Brasil. *Rev Bras Cir Cardiovascular*. 2004; 19(2): 3-4
2. Felcar JM, Guitti JCS, Marson AC, Cardoso JR. Fisioterapia pré-operatória na prevenção das complicações pulmonares em cirurgia cardíaca pediátrica. *Rev Bras Cir Cardiovasc*. 2008; 23(3):383-8.
3. Andrejaitiene J, Sirvinskas E, Bolys R. The influence of cardiopulmonary bypass on respiratory dysfunction in early postoperative period. *Medicina (Kaunas)*. 2004; 40(Suppl1):7-12.
4. Kavanagh BP. Perioperative atelectasis. *Minerva Anesthesiol*. 2008; 74(6):285-7.
5. Undern-Sternberg BS, Petak F, Saudan S, Pellegrini M, Erb TO, Habre W. Effect of cardiopulmonary bypass and aortic clamping on functional residual capacity and ventilation distribution in children. *J Thorac Cardiovasc Surg*. 2007; 134(5): 1193-8.
6. Nina RVAH, Gama MEA, Santos AM, Nina VJS, Figueiredo NETO JA, Mendes VGG, et al. O escore de risco ajustado para cirurgia em cardiopatias congênitas (RACHS-1) pode ser aplicado em nosso meio? *Rev Bras Cir Cardiovasc*. 2007; 22(4): 425-31.
7. Healy, Fiona; D. Hanna, Brian; Zinman, Raetzelle *Current Respiratory Medicine Reviews*, Volume 7, Number 2, April 2011, pp. 78-86 (9 Bentham Science Publishers)
8. Lee A. Fleisher. *Anesthesia and uncommon disease*. Elsevier Health Sciences, 2012; Sixth Ed. pp (6-7)
9. Oh AY, Kim YH, Kim BK, Kim HS, Kim CS Unexpected tracheomalacia in Marfan syndrome during general anesthesia for correction of scoliosis. *Anesth Analg* 2002; 95: 331-2.
10. Kanter RK, Pollack MM, Wright WW, et al. Treatment of severe tracheobronchomalacia with continuous positive airway pressure (CPAP). *Anesthesiology* 1982; 57: 54-6.
11. Shah PL, Scott SF, Knight RA, et al. In vivo effect of rhDNase on sputum in patients with cystic fibrosis. *Thorax* 1996;51(2):119-25.
12. Hassan NO, Chess PR. Rescue use of DNase in critical lung atelectasis and mucus retention in premature neonates. *Pediatrics* 2001;108:468.