

Aseptic Arthritis of the Temporomandibular Joint in an FMF Patient: A Case Report

FMF Hastasında Aseptik Temporomandibular Eklem Sinoviti ile birlikte Seyreden Yaygın Enflamasyon: Olgu Sunumu

✉ Kıvanç Berke Ak¹, ✉ Muazzez Süzen¹, ✉ Sina Uçkan¹

¹Bağcılar Medipol Mega University Hospital, Oral and Maxillofacial Surgery, Istanbul, Turkey

Öz

Ailevi Akdeniz ateşi (FMF), kendini sınırlayan, provoke edilmemiş ateşli ve poliserozit ataklarıyla karakterize sistemik otoinflamatuar hastalıktır. Temporomandibular eklem (TME) tutulumu nadir olsada, yaşam kalitesini önemli ölçüde düşer ve bazı hastalıklar ile benzer semptomlar nedeniyle yanlış teşhis edilebilir. Birkaç vakada farklı cerrahi yaklaşımlar bildirilmesine rağmen, kabul edilmiş tedavi yöntemi yoktur.

Olgu Sunumu: Şiddetli unilateral TME bölgesi ağrısı ve ağız açıklığında kısıtlılık nedeni ile 11 yaşında kadın hasta merkeze baş vurmuştur. Alınan anamnezde kolşisin tedavisi altında olmasına rağmen ayda bir FMF atakları geçirdiği bildirilmiştir. Radyoloji departmanı konsültasyonu sonrası kontrastlı manyetik rezonans görüntüleme (MRI) gerçekleştirildi. MRG raporunun septik artrit ve osteomyelit gibi enfektif hastalıklara yönlendirmesine rağmen, FMF ataklarının sıklığı nedeniyle diğer enflamatuar süreçler yeniden değerlendirildi. Lokal anestezi altında bakteriyolojik inceleme amaçlı sinovyal sıvı alındı. Artrosentez sonrası semptomlarda hızlı bir rahatlatama gözlemlendi. Sinovyal sıvı incelemesinde bakteri üremesi tespit edilmedi. Kolşisin doz ayarlaması ile altı aylık takipte FMF atağı gözlenmedi ve ilave operasyona ihtiyaç duyulmadı.

Sonuç: FMF'e bağlı TME artrit çok nadir görülür ve diğer hastalıklarla örtüşen semptomlar yanlış tanıya yol açabilir. Bu durumun tedavisi ile ilgili bir görüş birliği yoktur. Akut ve subakut semptomlar, kolşisin dozunun artırılması ve artrosentez gibi non-invaziv yöntemlerle hızlı bir şekilde giderilebilir.

Anahtar Kelimeler: temporomandibular eklem, artrit, ailesel akdeniz ateşi

ABSTRACT

Familial Mediterranean fever (FMF) is a systemic autoinflammatory disorder characterized by self-limited unprovoked inflammatory attacks of fever and polyserositis. Although temporomandibular joint (TMJ) involvement is uncommon, it significantly reduces the quality of life and could be easily misdiagnosed due to overlapping symptoms. Only a few cases have been reported with different surgical approaches, but there are no specific treatment guidelines.

Case Report: The case of an 11-year-old female FMF patient with severe unilateral TMJ region pain and limited maximum mouth opening is presented. Although the patient was under colchicine treatment, the frequency of FMF attacks was once a month. After consultation with the radiology department, contrast-enhanced magnetic resonance imaging (MRI) was performed. The differential diagnosis of the MRI report was infectious processes (septic arthritis and osteomyelitis). Nevertheless, other inflammatory processes were evaluated due to the frequency of FMF attacks. Under local anesthesia, synovial fluid was taken for bacteriological examination, and arthrocentesis was performed. Symptoms were relieved immediately after the operation. Bacterial growth was not detected on synovial fluid examination. No new FMF attacks were reported, and no new operations were needed in the six-month follow-up with colchicine dosage adjustment.

Conclusion: TMJ arthritis due to FMF is seen very rarely, and overlapping symptoms could lead to misdiagnosis. Although there is no consensus regarding the treatment of TMJ arthritis, acute and subacute symptoms could be relieved very quickly with less invasive methods, such as increasing the dose of colchicine and arthrocentesis.

Keywords: temporomandibular joint, arthritis, familial mediterranean fever

Sorumlu Yazar/Corresponding Author: Kıvanç Berke Ak
Bağcılar Medipol Mega Üniversite Hastanesi, Ağız Diş ve Çene
Cerrahisi

e.mail: kivançberkeak@gmail.com

Tel: 02124607070

Geliş tarihi/Received: 24.06.2021
Kabul tarihi/Accepted: 10.03.2022

INTRODUCTION

Familial Mediterranean fever (FMF) is an autosomal-recessive autoinflammatory disorder characterized by apparently unprovoked inflammation without infection, recurrent episodes of self-limiting fever, and serositis. In most patients, symptoms begin to appear before the age of 10, and the female-to-male incidence ratio is 1: .(1-3). The most prominent feature of FMF is paroxysmal fever that lasts for 2-3 days. Fever attacks are accompanied by symptoms of peritonitis, pleuritis, and arthritis (1). Like all autoinflammatory diseases, it is essential to make the correct diagnosis because of the overlapping symptoms (4). In FMF, acute phase reactants (erythrocyte sedimentation rate, C-reactive protein, serum amyloid A) and leukocyte count increase. These data help distinguish FMF from other conditions, such as viral disease, fibromyalgia, functional abdominal pain, and irritable bowel syndrome (4,5). The gene associated with FMF is located on the short arm of chromosome 16 and encodes a 781 amino acid protein called pyrin, which plays a vital role in apoptosis and inflammation. As a result of its mutation, extensive inflammation develops as a result of excessive IL-1 β secretion (4).

The most important complication of FMF is amyloidosis, which generally affects the kidneys. Intestinal obstruction; female infertility; and amyloidosis of the liver, spleen, and gastrointestinal system can also be seen. Some studies have reported that Met694Val gene mutation increases the risk of secondary amyloidosis and the severity of inflammation (4,6).

After peritonitis, articular involvement is the second most prevalent FMF manifestation. Often, articular involvement affects the middle and large joints in the lower extremities (4). The most common type of arthritis in FMF is monoarticular, recurrent, self-limited, and short-lived acute inflammation. However, protracted joint effusion attacks have been reported that can last for months or even years (7). Although joints other than the hip joint usually heal without invasive treatment, the course of hip joint involvement is generally chronic and destructive (8). A few cases of temporomandibular joint (TMJ) involvement are reported in the literature. TMJ involvement causes acute synovitis, trismus, and chronic pain (1,3). It is usually short-lived but in some cases causes bone destruction and can cause juxta-articular osteoporosis by its chronic course. Although different treatments have been tried and found successful in the reported cases, a common consensus on its treatment has not been established, as is the case with large joints (1).

The main goal of FMF treatment is to ensure complete prevention of unprovoked attacks and minimize subclinical inflammation between attacks (9). The first-line medication used in the prophylactic treatment of FMF since 1972 has been colchicine, and colchicine is the only drug that can prevent secondary amyloidosis, which is the most devastating complication of this disease (2,10). The development of molecular and genetic science has yielded new target drugs to be used in addition to colchicine in some situations. These new medications are used in persistent attacks despite the maximum prescribed tolerable dose of colchicine (10). The maximum dose in pediatric patients is 2 mg/d. Colchicine acts by changing the actin cytoskeleton by binding to tubulin monomers and inhibiting polymer formation (10,11).

In this report, the case of a patient who had FMF with TMJ and surrounding tissue inflammation and the management of this condition are presented.

CASE REPORT

An 11-year-old female patient was referred from an external center to the Oral and Maxillofacial Surgery Department, with severe pain in the right TMJ region and limited mouth opening. In anamnesis, FMF was diagnosed three years previously, and medical treatment was 2x1 0.5 mg colchicine (Colchicum Dispert®, Recordati, Italy) per day. Although the patient had used medications regularly, attacks had started to occur once a month for the last six months, and the patient had applied to our clinic during the last attack. Three months earlier, for the first time, in addition to the signs of the known symptoms of FMF, the patient experienced limited mouth opening and intense pain in the preauricular region, and these TMJ problems did not resolve.

In the clinical examination, the maximum mouth opening between the right upper and lower incisor teeth was 16 mm, which did not increase with passive stretching. In addition, 1 mm right deflection; bilateral chronic, mobile submandibular lymphadenopathy; and severe pain in the palpation of the right masseter and temporal muscle were detected. A contrast-enhanced MRI and the examination were performed on the same day (Figure 1).

In the contrast-enhanced MRI scans, a dense collection was observed in the right temporomandibular joint capsule. The axial plane's widest part was 23x23 mm, reaching a height of 13 mm in the anterior and posterior leveling. There was high contrast in the synovium in the postcontrast series. Right mandibular condylar roundness disappeared, the superior contour was irregular, and the joint

disc-to-condylar relationship was disrupted. Increased signal in the right mandibular condyle compatible with bone marrow and contrast enhancement in the postcontrast series were noted. Edema and enhancement were compatible with inflammation in the pterygoid and masseter muscles adjacent to the right TMJ. Bilateral articular eminence morphology and signal intensity were normal. The morphology and signal intensity of the bilateral temporomandibular joint disc were preserved. TMJ relations on the left and the joint disc's position to the mandibular condyle in the open and closed mouth positions were normal.

When these findings (changes in the mandibular condyle, bone marrow edema, and inflammation in the masticatory muscles) were evaluated together, the radiology department informed us that infectious processes (septic arthritis and osteomyelitis) should be evaluated first in the differential diagnosis. However, considering the patient's intense attacks, the TMJ was also evaluated for other inflammatory processes.

The patient's symptoms, especially severe pain with limited mouth opening and radiological examination, were evaluated together; TMJ arthrocentesis was performed under local anesthesia on the same day without an extra intraarticular injection. The fluid taken from the TMJ under sterile conditions during arthrocentesis was sent to the microbiology laboratory for bacteriological examination to eliminate the diagnosis of septic arthritis and osteomyelitis. A consultation was requested with the patient's rheumatologist, who followed the patient regarding the frequency of FMF attacks and the relationship with TMJ arthritis. The acute symptoms were relieved immediately following arthrocentesis. All complaints disappeared, and the maximum mouth opening was 40 mm with no deflection at the follow-up appointment in the first month. The patient's rheumatologist altered the drug regimen from 2x1 colchicine 0.5 mg to 3x1 because of the attack frequency. In the patients' blood analysis taken by her rheumatologist, erythrocyte sedimentation rate, CRP, and fibrinogen were 51 mm/h, 14 mg/L, 401 mg/dL, respectively. At the microbiological examination, bacterial growth was not detected.

No new attack developed within six months after the patient's medication regimen was rearranged. In the third month follow-up MRI (Figure 2), it is noteworthy that the collection defined in the right TMJ capsule at the previous examination was lost entirely. There was no finding indicating synovitis in unenhanced images. Contour irregular-

ity and flattening on the anterior-superior surface of the right mandibular condyle continues. Although the signal increase in the right mandibular condyle, which is compatible with bone marrow edema, has partially regressed, it continues. In the previous examination, signs of inflammation in the masticatory muscles adjacent to the right TMJ had completely regressed. Bilateral articular eminence morphology and signal intensity are normal. The bilateral TMJ disc configuration is typical, and the signal intensity is preserved. The left mandibular disc and condyle perform their normal synchronized movement in the images obtained with the mouth in the open and closed position.

DISCUSSION

FMF is a common disease in Middle East and western Mediterranean countries and has phenotypic variations among races (6). Studies report that some races also have a relatively higher incidence of amyloidosis than other ethnic groups and a more severe disease course.(12,13) Colchicine, which is an immunomodulator, is considered the first-line treatment of FMF. It has been proven that colchicine has an essential role in preventing FMF attacks in adults and children. Additionally, colchicine prevents the development of amyloidosis and increases patients' quality of life. Even if amyloidosis can be suppressed with a lower dose in adults, colchicine's minimum daily dose is recommended to be 1 mg and should not exceed 3 mg. In pediatric patients, the maximum dose has been reported as 2 mg/d (2).

Although there is no accepted standard method for the treatment of medium- and large-joint synovitis due to FMF, sulfasalazine, repetitive aspiration from the joint, corticosteroid injection following arthrocentesis and synovectomy are among the recommended treatments (1,4,7). FMF causing TMJ arthritis is usually short-lived. However, it can continue for months and cause chronic pain, trismus, and bone damage, such as juxta-articular osteoporosis. According to our literature research, TMJ involvement due to FMF was reported only in 5 case reports in 4 patients. Anesthetic spray, physiotherapy, IM local anesthesia injection, arthrocentesis, ivy loop-intermaxillary elastics, therapeutic exercises, IM and intraarticular dexamethasone injection, arthroscopy, intraarticular injection of celestone chronodose, and indomethacin are among the treatment methods reported. In all cases reported, the patients' symptoms have decreased, but there is no determined treatment consensus in TMJ arthritis due to FMF as in other joints (1,14–17).

In the case report by Frenkel et al.(1), a 14-year-old female

patient was not under colchicine treatment, although FMF has been diagnosed previously. The patient visited the emergency department with limited mouth opening and unilateral painful swelling in the TMJ region, and none of these symptoms had occurred before. Although hemogram values were normal, an increased CRP level was determined. Intracapsular steroid injection was applied after arthroscopy under general anesthesia to relieve acute symptoms, and then physiotherapy was started. The daily dose of colchicine was increased to 1.5 mg. In our case, monoarticular joint involvement occurred. In contrast to typical arthritis in FMF, the (right) TMJ was affected instead of the lower extremities. The intervention for acute joint synovitis was performed under local anesthesia instead of general anesthesia and was sufficient to relieve the patient's complaints, such as excessive pain and decreased maximum interincisal distance. Similarly, in our case, attacks were suppressed by increasing the colchicine dose from 1 mg per day to 1.5 mg. As in the report of Frenkel et al., contrast-enhanced MRI was performed on the same day in our case, and radiological examination detected intracapsular intense effusion, synovitis, condylar flattening, and irregularity in the right TMJ accompanied by inflammation in the unilateral pterygoid and masseter muscles. Through close collaboration with the radiology department, MRI, MRI evaluation, and arthrocentesis were performed on the same day.

Usluer et al.(18) reported unilateral knee joint arthritis in his case report, which was evaluated as septic arthritis due to MRI. As a result, repeated invasive procedures were performed on the patient in the orthopedic clinic, and long-term antibiotics were used. Despite the invasive procedures, because of the persistent recurrence of arthritis, a sample was obtained from the patient for bacterial culture. Since no agent had grown in the culture, the diagnosis of septic arthritis was re-evaluated. As a result of the patient's genetic examination, FMF was diagnosed. Arthritis could be prevented permanently with the initiation of colchicine. In our case, MRI suggested a diagnosis of septic arthritis, but FMF in the anamnesis was critical in reversing the diagnosis. Although the consultation of the patient's rheumatologist was requested, a negative response was received, and it was reported that FMF and TMJ synovitis were irrelevant. The second important point is that contrast-enhanced MRI evaluation was performed immediately due to close collaboration with the radiology department because of the patient's acute pain. The patient underwent arthrocentesis on the same day immediately following the imaging procedures. Arthrocentesis was performed after the intracapsular fluid was removed

for bacteriological examination to suppress the patient's acute symptoms and eliminate the possibility of septic arthritis. Arthrocentesis was performed without any additional injection, and then physical therapy was initiated. The patient delivered the consultation to her rheumatologist after the interventional procedure. The rheumatologist has increased the colchicine dose from 1 mg/d to 1.5 mg/d due to the frequency of attacks. The patient did not develop a new attack, and the joint pain was permanently resolved.

Tovi et al.(16,17), Cooksey et al.(15), and Simon et al.(19) suggest intraarticular steroid injection in their case reports. It has been highlighted that intraarticular steroid injection rapidly suppresses acute synovitis symptoms, but the adverse effects of steroid injections on the bone and joint were not considered (20). In our case, the patient's acute symptoms were suppressed with arthrocentesis by saline solution without a steroid injection, and there was no need for any extra drug injection. Only in Simon et al.'s (19) report was the colchicine dose adjusted to suppress attacks. However, no comment was made that suppressing the attacks may prevent synovitis.

Edema and decreased blood flow could increase intraosseous extravascular pressure, which causes aseptic necrosis, also known as avascular necrosis. The pathophysiology of avascular necrosis can be briefly summarized as a circulatory disturbance. As a result, avascular necrosis may cause degenerative changes and pain in the condylar region (21). It is thought that the unilateral irregularities in the condyle along with bone marrow edema seen in our case may be a sign of avascular necrosis due to prolonged inflammation.

CONCLUSION

TMJ arthritis due to FMF is seen very rarely, and there is no consensus regarding its treatment. Acute and subacute symptoms could be relieved very quickly with less invasive methods, such as increasing the dose of colchicine and arthrocentesis, instead of advanced interventional procedures or steroid injection. A detailed analysis will be possible with more case reports.

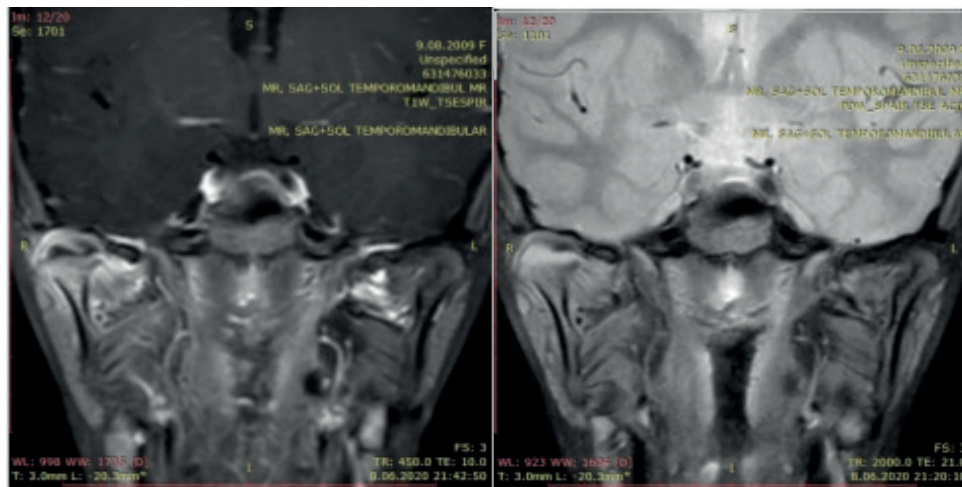


Figure 1: A contrast-enhanced MRI examination

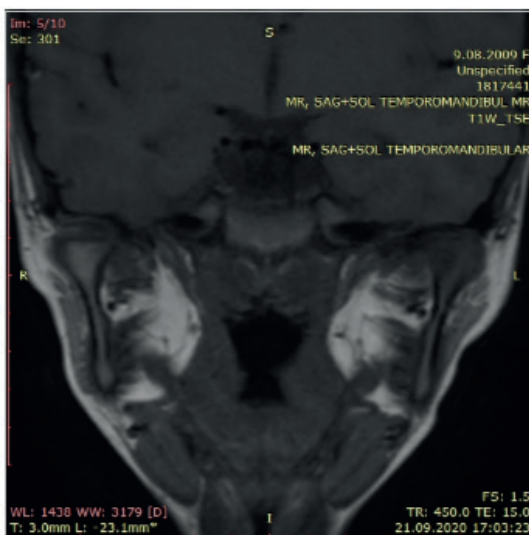


Figure 2: The third month follow-up MRI examination

REFERENCES

1. Frenkel B, Berg T, Totry A, Rachmiel A. A novel treatment of temporomandibular joint arthritis as a complication in familial Mediterranean fever—literature review and a case report. *Oral Maxillofac Surg.* 2018;22(4):365–8.
2. Hentgen V, Grateau G, Kone-Paut I, Livneh A, Padeh S, Rozenbaum M, et al. Evidence-based recommendations for the practical management of Familial Mediterranean Fever. *Semin Arthritis Rheum [Internet].* 2013;43(3):387–91.
3. Uthman I, Hajj-Ali RA, Arayssi T, Masri AF, Nasr F. Arthritis in familial Mediterranean fever. *Rheumatol Int.* 2001;20(4):145–8.
4. Berkun Y, Eisenstein EM. Diagnostic criteria of familial Mediterranean fever. *Autoimmun Rev [Internet].* 2014;13(4–5):388–90.
5. Berkun Y, Padeh S, Reichman B. A Single Testing of Serum Amyloid A Levels as a Tool for Diagnosis and. 2007;(6):182–8.
6. Mukhin NA, Kozlovskaya L V., Bogdanova M V., Rameev V V., Moiseev S V., Simonyan AK. Predictors of AA amyloidosis in familial Mediterranean fever. *Rheumatol Int.* 2015;35(7):1257–61.
7. Jarjour RA, Dodaki R. Arthritis patterns in familial Mediterranean fever patients and association with M694V mutation. *Mol Biol Rep.* 2011;38(3):2033–6.
8. Migita K, Hisanaga S, Izumi Y, Kawahara C, Shigemitsu Y, Iwanaga N, et al. Protracted arthritis in a Japanese patient with familial Mediterranean fever. *Mod Rheumatol.* 2017;27(5):905–9.
9. Ozen S, Demirkaya E, Erer B, Livneh A, Ben-Chetrit E, Giancane G, et al. EULAR recommendations for the management of familial Mediterranean fever. *Ann Rheum Dis.* 2016;75(4):644–51.
10. El Hasbani G, Jawad A, Uthman I. Update on the management of colchicine resistant Familial Mediterranean Fever (FMF). *Orphanet J Rare Dis.* 2019;14(1):1–12.
11. Dinarello CA, Wolff SM, Goldfinger SE, Dale DC, Alling DW. Colchicine therapy for familial mediterranean fever. A double-blind trial. *N Engl J Med [Internet].* 1974 Oct 31;291(18):934–7.
12. Yalçinkaya F, Çakar N, Misirlioğlu M, Tümer N, Akar N, Tekin M, et al. Genotype-phenotype correlation in a large group of Turkish patients with familial Mediterranean fever: Evidence for mutation-independent amyloidosis. *Rheumatology.* 2000;39(1):67–72.
13. Giaglis S, Papadopoulos V, Kambas K, Doumas M, Tsironidou V, Rafail S, et al. MEFV alterations and population genetics analysis in a large cohort of Greek patients with familial Mediterranean fever. *Clin Genet.* 2007;71(5):458–67.

- 14.** Simon G, Marbach JJ. Familial mediterranean fever with temporomandibular joint arthritis. *Pediatrics* [Internet]. 1976;57(5):810–2.
- 15.** Cooksey DE, Girard K. Temporomandibular joint synovitis with effusion in familial Mediterranean fever. *Oral Surgery, Oral Med Oral Pathol.* 1979;47(2):123–6.
- 16.** Tovi F, Gatot A, Fliss D. Temporomandibular arthritis in familial mediterranean fever. *Head Neck.* 1992;14(6):492–5.
- 17.** Tovi F, Barneir E, Peist M, Bar-Ziv J. Protracted temporomandibular joint arthritis in familial Mediterranean fever. *J Oral Maxillofac Surg* [Internet]. 1985;43(6):466–8.
- 18.** Usluer H, Bircan Z. Protracted familial mediterranean fever arthritis presenting as septic arthritis. *Rheumatol Int.* 2007;27(11):1083–5.
- 19.** Simon G, Marbach JJ. Familial Mediterranean fever with temporomandibular joint arthritis. *Pediatrics.* 1976;57(5):810–2.
- 20.** Marzook HAM, Abdel Razek AA, Yousef EA, Attia AAMM. Intra-articular injection of a mixture of hyaluronic acid and corticosteroid versus arthrocentesis in TMJ internal derangement. *J Stomatol Oral Maxillofac Surg.* 2020;121(1):30-4.
- 21.** Chuong R, Piper MA. Avascular necrosis of the mandibular condyle-pathogenesis and concepts of management. *Oral Surgery, Oral Med Oral Pathol.* 1993;75(4):428–32.