

Primary Cerebellar Agenesis - Chiari IV Malformation

Deniz TEKİN, MD.¹, Serap UYSAL MD.¹, Ömer İYİĞÜN, MD.²,

Ondokuz Mayıs Üniversitesi, Tıp Fakültesi, Çocuk Sağlığı ve Hastalıkları¹ ve Nöroşirürji²
Anabilim Dalları, SAMSUN

- ✓ Total or subtotal cerebellar agenesis that was described firstly by M. Combettes in 1831 is very rare. Severe dysfunction in movement is observed in the cerebellar lesions. Since there is a significant recovery in movement partial cerebellum lesions, it has been suggested that normal movement is not absolute dependent to cerebellum. But this issue is still controversial. The cases of complete cerebellar agenesis in the literature are usually reported in the autopsy. The study presented here is the sixth living case in the literature according to our knowledge.

Key words: Cerebellar agenesis, motor abnormality, central nervous system malformations

- ✓ **Primer Serebellar Agenezi - Chiari IV Malformasyonu**

Total yada subtotal serebellar agenezi ilk kez 1831'de M. Combettes tarafından tariflenen çok nadir bir durumdur. Serebellum lezyonlarında hareketde ciddi bozukluk gözlenir. Parsiyel serebellum lezyonlarında belirgin bir iyileşme olduğundan dolayı serebellumun normal hareket ile ilgili olmadığı düşünülür. Literatürdeki total serebellar agenezi vakaları genellikle otopsielerde bildirilmiştir. Burada sunulan vaka, literatürde bizim bildiğimiz yaşayan altıncı vakadır.

Anahtar kelimeler: Serebellar agenezi, motor anormallik, santral sinir sistemi malformasyonları

INTRODUCTION

Total or subtotal cerebellar agenesis described firstly by M. Combettes in 1831⁽¹⁾ is very uncommon. Severe dysfunction in movement is observed in the cerebellum lesions. Since there is a significant recovery in the partial cerebellum lesions, it has been suggested that normal movement is not dependent to cerebellum⁽²⁾. But this issue is still controversial. Cerebellar agenesis can be seen with other nervous system diseases such as anencephaly, microcephaly, holoprosencephaly, congenital hydrocephaly and arrhinencephaly⁽³⁻⁷⁾. The cases of complete cerebellar agenesis in the literature are usually reported in the autopsy. The study presented here is the sixth living case in the literature according to our knowledge.

CASE STUDY

A seven-year old girl patient admitted to our clinic with complaints of unable to walking, medial strabismus in the eyes. There was no abnormal findings in history for prenatal period and birth. She has four healthy brothers and one healthy sister. At physical examination, Her height, weight and head circumference are 118.0 (25-50P) cm, 21.0 (25-50P) kg, 48 (2%-98%) cm respectively. Except for neurologic examination, the physical examination is normal. There aren't any chromosomal and metabolic abnormalities as well as anomalies belong to other organs. Her family history is unremarkable. There is no relationship between the parents and it was learnt that her motor development in the first months of

life had been normal. She was able to sit down with support in sixth month and without support in eighth month. In fourteenth month, she was able to walk with support. In eighteenth month, she was able to say some words such as mommy and daddy. Around the six and half and seven years of age she was able to stand up herself. In her postnatal history, febrile convulsions happened in the eighteenth month. The patient's motor development has started to become worst especially after the second febrile convulsion. When we saw the patient first she was seven years old and in the first grade of the elementary school. Her IQ level was evaluated as just under the normal level and her reading and speaking was not so clear and her handwriting was not good. She was able to eat her meals and to wear her clothes herself and she was able to meet these kinds of her needs since three years of age according to her parents. After almost one year-follow up period, we saw that her clinical symptoms started to get better. At this period she has

physical rehabilitation program and she has got benefit from this program. She was able to walk 15-20 steps without help and her speaking and handwriting was better. In the neurological exam, the walking was ataxic and there was a disymmetry and disdiadokokinesy. In the lower extremities deep tendon reflexes was briefly increased. In the eyes there was medial strabismus and it was very obvious at the right eye. In the MRI (magnetic resonance imaging), the brain cerebellum was agenetic and there was no vermis. The brain stem was hypoplastic and posterior fossa was full with CSF (cerebrospinal fluid). Aqua ductus, hemispheric area, third and lateral ventricles were normal (Figure 1, 2). With these findings, the patient was diagnosed as Chiari IV Malformation.

DISCUSSION

Primary cerebellar agenesis is described as total or subtotal agenesis. It is really a rare disease⁽⁶⁾ and its clinical manifestations are really variable. In literature, there is an

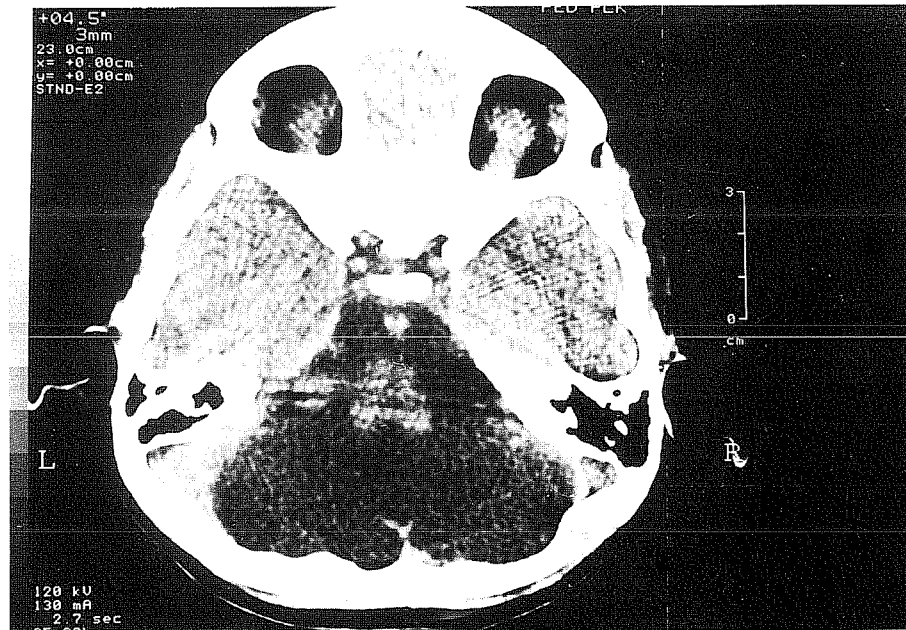


Figure 1. Scan showing the absent of cerebellar tissue in posterior fossa.

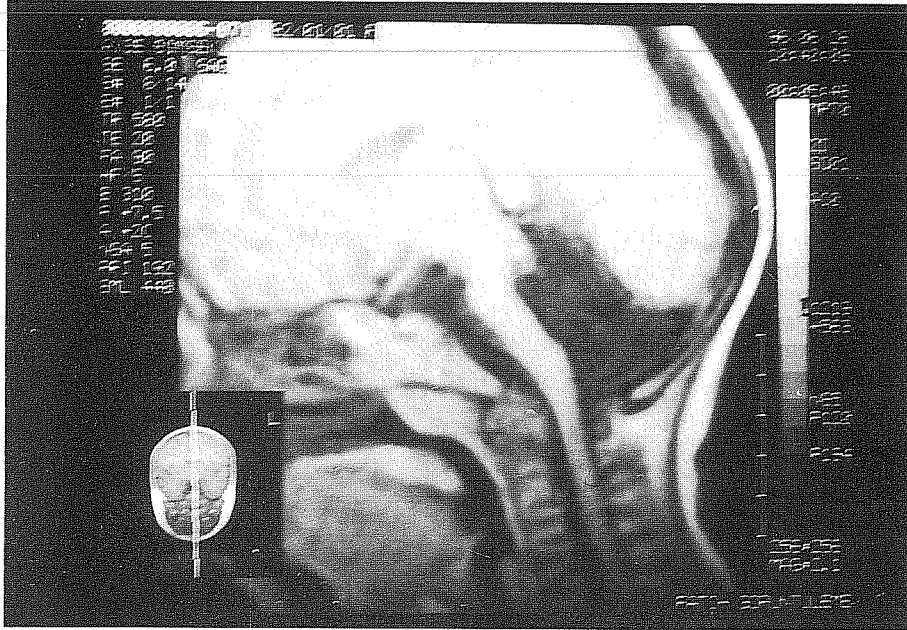


Figure 2. Severe cerebellar hypoplasia has sometimes been termed Chiari IV malformation. Finding in this very rare entity include absent or severely hypoplastic cerebellum, small brain stem and large posterior fossa cerebrospinal fluid spaces. T1 weighted magnetic resonance image shows large ventriculus and absence of the cerebellum.

example living only one hour as well as an example living until 71 years of age^(8,9). These patients have usually behavioral, mental and physical abnormalities in higher rates^(6,10,11). Physically, they exhibit a nonprogressive syndrome characterized by variable inability to coordinate movements. Based on the autopsy results, it has been reported only five cases of cerebellar agenesis between years of 1831 and 1965 (Combettes, 1831; Sternberg, 1912; Anton and Zingerle, 1914; Baker and Graves, 1931; Tennstedt, 1965). The study presented here is the sixth living case in our knowledge. Primary cerebellar agenesis and cystic and cystic-like malformations of posterior fossa might be very similar to each other in terms of many features. That's why distinctive diagnosis should be done very well. The differential diagnosis of primary cerebellar agenesis, which may be difficult

with CT (computed tomography), includes cystic or cyst-like malformations of the posterior fossa, including the Dandy-Walker malformation (DWM), vermian- cerebellar hypoplasia (VCH), mega-cisterna magna(MCM), arachnoid cysts (AC) and the vanishing cerebellum seen in Chiari II malformation (VCCM). DWM is easily diagnosed on the basis of the classic triad: complete or partial agenesis of the vermis, cystic dilatation of the fourth ventricle and an enlarged posterior fossa. VCH describes a variety of congenital malformations associated with a normal-sized posterior fossa, varying degrees of vermian and cerebellar hypoplasia, and a prominent retrocerebellar cerebrospinal fluid space that communicates freely with a normal or dilated fourth ventricle. MCM can be asymmetric and give the appearance of a mass effect, simulating an arachnoid cyst;

therefore, ventriculography or cisternography may be required to demonstrate the communication of the cyst with the subarachnoid space⁽¹²⁾. In the Chiari II malformation severe degeneration of the cerebellum may occur, which has been termed the "vanishing cerebellum". VCCM must be differentiated from primary cerebellar agenesis, on the basis of a relatively normal-sized posterior fossa, identification of symmetrical remnants of the anterior quadrangular lobules, lack of scattered remnants of cerebellar tissue and the presence of a normal tentorial attachment, straight sinus, brain and spine. The Chiari II malformation is always associated with a myelomeningocele⁽⁶⁾.

In our patient, the MRI findings identified the anomaly as primary cerebellar agenesis and therefore there is a hypoplastic brain stem as well as cerebellar agenesis, we accepted this case as a Chiari IV malformation.

CONCLUSION

Even though the concept that cerebellum is center of the balance has been accepted for long time, some scientists has emphasized that cerebellar agenesis sometimes may be without any symptom. Walking and speaking of the patients with cerebellar agenesis are slow and highly clumsy during their lives⁽²⁾. When the published cases were investigated, it has been observed that these patients were able to stand up, walk and talk over the course of time. We have also observed in our case that cerebellar functions started to improve in our one year-follow up period.

Geliş tarihi : 08.01.2002

Yayına kabul tarihi : 01.08.2002

Yazışma adresi:

Dr. Deniz TEKİN

Ondokuz Mayıs Üniversitesi, Tıp Fakültesi,

Çocuk Sağlığı ve Hastalıkları Anabilim Dalı

55139 Kurupelit, SAMSUN

REFERENCES

1. Combettes M. Absence complète du cervelet, des pÉdoncules postÉrieurs et la protubÉrance cÉbrale chez une jeune fille morte dans sa onziÈme annÉe. Bull Soc Anat Paris 1831; 5: 148-157.
2. Glickstein M. Cerebellar agenesis. Brain 1994; 117: 1209-1212.
3. Riccardi VM, Marcus ES. Congenital hydrocephalus and cerebellar agenesis. 1978; 13: 443-447.
4. Hayashi T, Takagi S, Kuramoto S. A case of haloprosencephaly: with possible association of Dandy-Walker cyst. Brain Dev.1981; 3: 97-101.
5. Pitella JE, Nogueiera AM. Cerebellar agenesis associated microencephaly and agyria: report of an autopsied case in a newborn infant and a review of the literature. Arg Neuropsiquiatr. 1988; 46: 385-392.
6. Sener RN. Cerebellar agenesis versus vanishing cerebellum in Chiari malformation. Comput Med Imaging Graph. 1995; 19: 491-494.
7. Leech RW, Johnson SH, Brumback RA. Agnesis of cerebellum associated with arrhinencephaly. Clin.Neuropathol. 1997; 16: 90-97.
8. Ronald L, Hamilton, Marjorie R et al. Complete absence of the cerebellum: a report of two caess. Acta Neuropathol 1994; 88 : 258-261.
9. Rubenstein HS, Freeman W. Cerebellar agenesis.J Nerv Ment Dis 1940; 92: 489-482.
10. Macchi G, Bentivoglio M. Handbook of clinical neurology. In: Vinken PJ, Bruyn GW (ed.). Agnesis or hypoplasia of cerebellar structures. Amsterdam, Elsevier 1977; 367-393.
11. Larroche JC. Greenfield's neuropathology. In: Adams, Corsellis JA, Duchen LW (ed). Malformations of the cerebellum. New York, Wiley. 1984; 402-406.
12. Velioglu K.S, Kuzeyli K, Özmenoğlu M. Cerebellar agenesis: a case report with clinical and MR imaging findings and a review of the literature. European Journal of Neurology 1998; 5: 503-506.