

Chondroblastic Osteosarcoma of the Right Clavicle (A Case Report)

Nevzat DABAK, M.D.¹, Sancar BARIŞ, M.D.², Birol GÜLMAN, M.D.¹,
Yılmaz TOMAK, M.D.¹, Selçuk TEPE, M.D.¹,

Ondokuz Mayıs University Medical Faculty, Orthop. and Traum. Dept.¹, and Pathology Dept.², SAMSUN

- ✓ Chondroblastic osteosarcoma is seen in less than 5% of osteosarcomas. The clavicle is an unusual site for any primary tumor, including osteogenic sarcoma and it is reported that the clavicle is the primary site in 0.45% of 13000 primary bone tumors. In this article, a chondroblastic osteosarcoma case which is located in the clavicle is presented and literature is reviewed.

Key words: Osteogenic sarcoma, clavicle

- ✓ **Sağ Klavikula'nın Kondroblastik Osteosarkomu (Olgu Bildirimi)**

Kondroblastik osteosarkom, osteosarkomların %5'inden daha azında görülür. Klavikula osteosarkomlar da dahil, primer tümörler için alışıldık bölge değildir. Yaklaşık olarak, 13000 primer kemik tümöründe klavikula tutulumu %0.45 oranındadır. Bu yazıda, klavikulada yerleşim gösteren bir kondroblastik osteosarkom olgusu sunuldu ve literatür bilgileri ile tartışıldı.

Anahtar kelimeler: Osteosarkom, klavikula

INTRODUCTION

The clavicle is an unusual site for any primary tumor, including osteogenic sarcoma. Klein et al. reviewed series reported by Memorial Sloan-Kattering Cancer Center, the Netherlands Committee on Bone Tumors and Mayo Clinic and estimated that the clavicle was the site in 0.45% of 13000 primary bone tumors⁽¹⁾. In series of Dahlin and Unni involving 8542 bone tumors, primary tumors of the clavicle were reported to occur with a frequency of 0.73%⁽²⁾. The most common primary malignancy affecting the clavicle in the Mayo Clinic series was myeloma, followed by Ewing sarcoma and osteosarcoma⁽²⁾.

Chondroblastic osteosarcoma as a variant in which more than 90% of the tissue is cartilaginous. Less than 5% of osteosarcomas

produce this degree of chondrosarcomatous tissue⁽³⁾.

CASE REPORT

A 27-year-old male patient was admitted to Ondokuz Mayıs University Medical Faculty Hospital because of a right supraclavicular mass and pain. From his anamnesis it has been learned that the lesion was first noted as a painless mass 1 years ago. Since the mass enlarged and became painful, an excisional biopsy was applied six months previously in another health center and pathologic examination reported reactive bone tissue. At the chest radiograph taken at this time, a round, regular shaped and sclerotic mass can be seen (Figure 1).

On physical examination, a 10 x 10 cm. fixed, hard, irregular shaped, painless mass

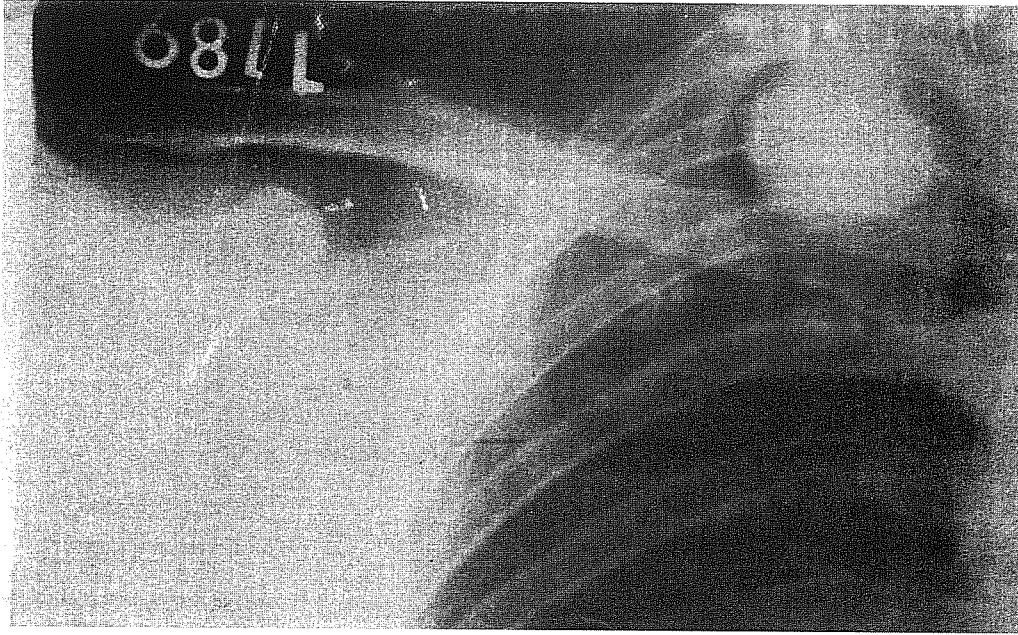


Figure 1. The radiograph of patient that was taken at the first application. Round shaped, sclerotic mass in the medial part of right clavicle.

was determined. Direct radiologic examination showed that the medial part of the right clavicle was invaded by tumor tissue with manifest sclerosis and calcification, and there were popcorn-like calciferous nodules in the soft tissue (Figure 2). There was no additional pathology in the radionuclide bone scanning, chest radiographs, or computerized tomography. A core needle biopsy was performed and mature bone trabeculae and neoplastic tissue formed of calcified malign cartilage was observed. With a diagnosis of chondrosarcoma and probable parosteal osteosarcoma marginal excision was performed.

In the macroscopic examination of the surgical specimen, it was determined that the tumor mass formed of bone and cartilage surrounded and destroyed the clavicle cortex. The mass was 13 x 9 x 8 cm. in dimensions, pearly-white at the sectioned surface and hard in nearly all areas (Figures 3 and 4).

Microscopic evaluation revealed mature bone trabeculae besides grade 1 malignant cartilage as well as grade 2-3 malignant cartilage in some areas (Figures 5 and 6). The diagnosis of chondroblastic osteosarcoma was made by determining atypical cells that formed osteoid in some areas (Figures 7 and 8). Besides surgical excision, adjuvant chemotherapy was applied. Patient presented with local recurrence at 10 months, and at present he is alive with disease at 14 months.

DISCUSSION

Clavicle is an unusual site for any primary bone tumor, including osteogenic sarcoma^(4,5). In the last decade literature, 5 cases of radiation induced osteosarcoma and only 3 cases of primary clavicle osteosarcoma were reported; one for them was chondroblastic like our case⁽⁴⁻⁸⁾. Long history and despite inappropriate management slow progressive nature of the

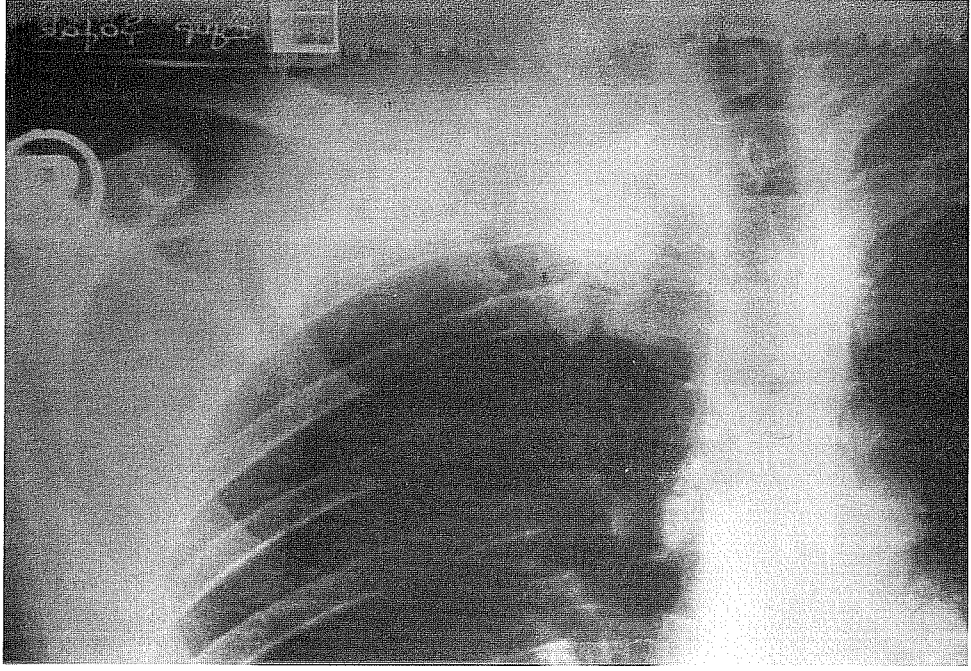


Figure 2. Radiograph that is taken in our hospital. Calciferous recurrent mass at the same lozalization.

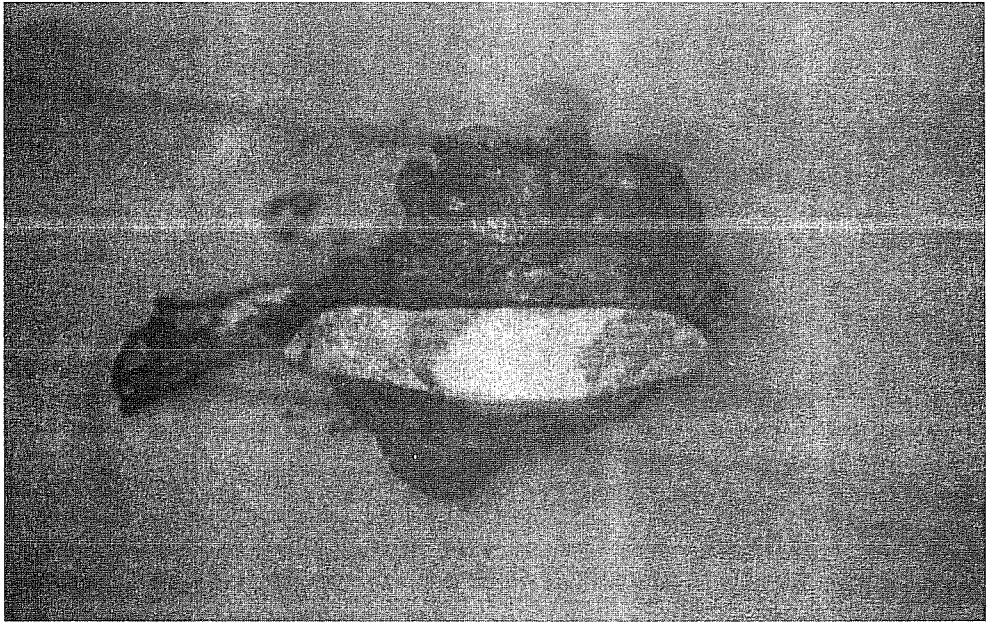


Figure 3. The resection specimen. Tumor has recovered the clavicle and destructed the cortex.

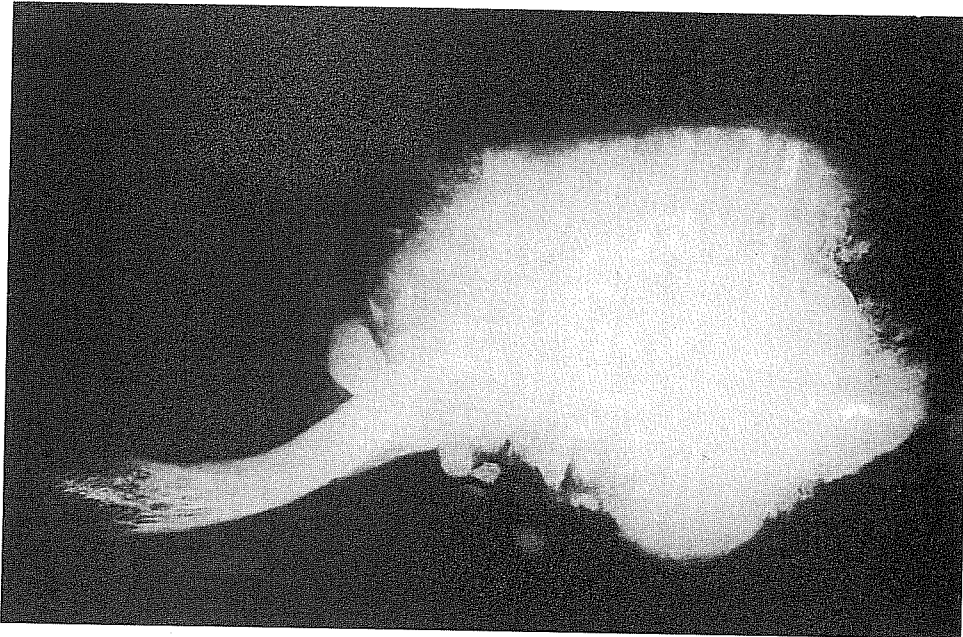


Figure 4. Diffuse sclerotic tumor in the specimen radiograph.

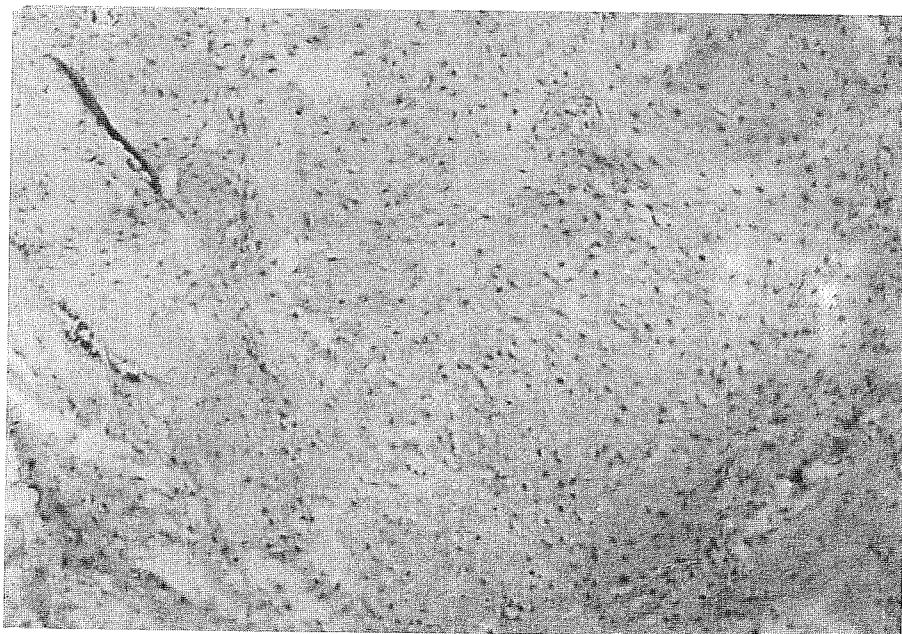


Figure 5. The general view of chondroblastic areas in low power magnification (hematoxylin eosin; x 25).

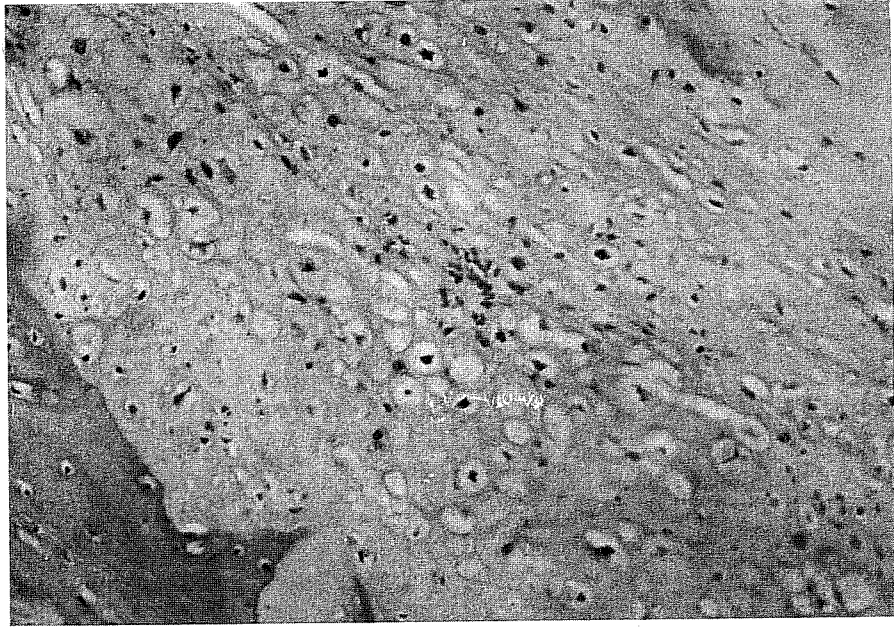


Figure 6. Malign cartilage creeping through mature bone spicules (hematoxylin eosin; x 100).

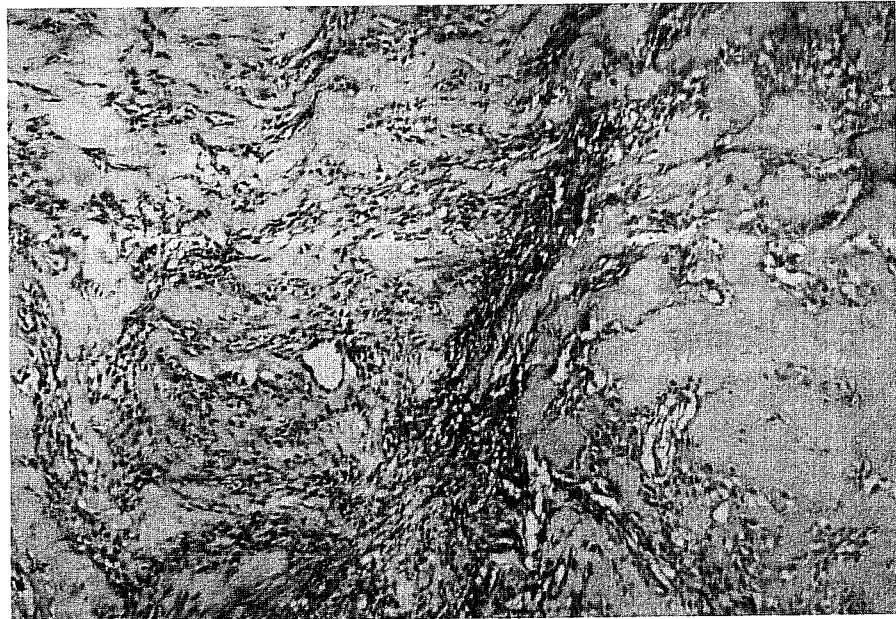


Figure 7. The general view of the osteoblastic areas (hematoxylin eosin; x 25)

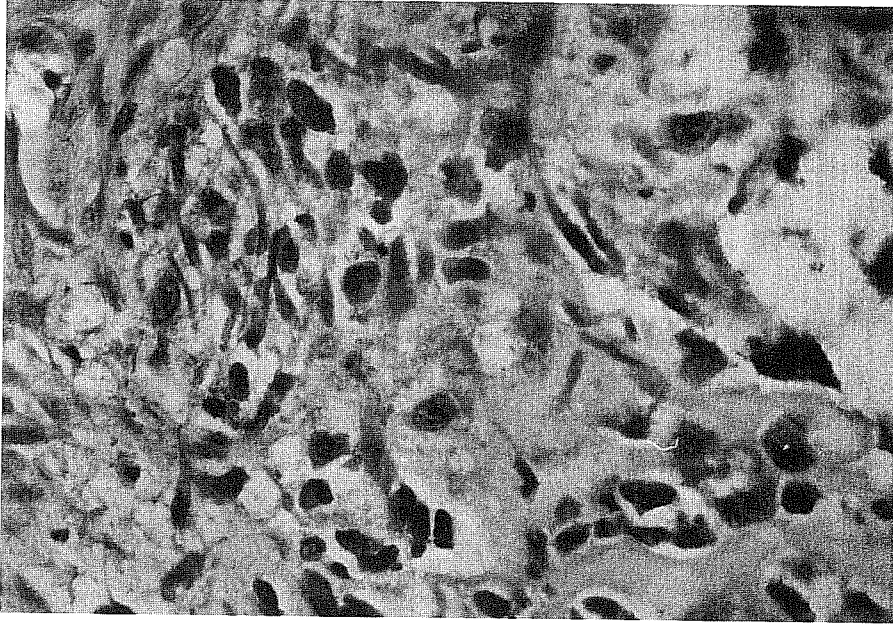


Figure 8. Tumor cells showing atypia and osteoid deposition (hematoxylin eosin; x 400).

tumor in our case suggest a low grade osteogenic sarcoma at least at the beginning and both histology and especially the first radiograph support this probability.

Tumors that appear in unusual localizations make diagnosis difficult. In the present case the differential diagnosis must include benign lesions like osteochondroma and malignant lesions like chondrosarcoma. Clinic and radiologic characteristics can help in the differential diagnosis, but definitive diagnosis in chondroblastic osteosarcoma could be settled by only the demonstration of malign osteoid. In similar lesions, to invent surgical treatment without adequate clinic, radiologic and pathologic evaluation make diagnosis and treatment difficult and the prognosis is effected negatively. Given its anatomical location, the lesion requires a multidisiplinary approach for optimal care, with each member of the health care team being important for maintaining and prolonging the quality of life for a patient.

Geliş tarihi : 16.05.1997

Yayına kabul tarihi : 12.06.1997

Corresponding address:

Dr. Nevzat DABAK

Ondokuz Mayıs Üniversitesi, Tıp Fakültesi,

Ortopedi ve Travmatoloji Anabilim Dalı

55139 SAMSUN

REFERENCES

1. Klein MJ, Lusskin R, Becker, Antopol SC : Osteoid osteoma of the clavicle. Clin. Orthop. 1979; 143: 162-166.
2. Dahlin DC, Unni KK. 4th ed. Thomas, Springfield, 1986; 143-183.
3. Mirra JM: Bone tumors: Osseous Tumors of Intramedullary Origin. Clinical, radiologic, and pathologic correlations. Edited by: Mirra JM. 1 st ed. Lea & Febiger, 1989; 309-311.
4. Smith J, Yuppa F, Watson RC: Primary tumors and tumor-like lesions of the clavicle. Skeletal Radiology 1988; 17(4): 235-246.
5. Greenspan A, Unni KK, Mann J. Case report 804: Chondroblastic osteosarcoma grade 3 of the left

- clavicle. *Skeletal radiology* 1993; 22 (6): 469-471.
6. Tobin HE, Miles PA: Radiation induced osteosarcoma of the clavicle: a case report and literature review. *Military Medicine* 1987; 152 (2): 89-92.
 7. Byrd T, Gleis GE, Johnson JR: Primary osteogenic sarcoma of the clavicle. A case report. *Orthopedics* 1986; 9 (12): 1717-1720.
 8. Oda Y, Hashimoto H, Tsuneyoshi M, Masuda S: Case Report 793. Periosteal osteosarcoma of the clavicle. *Skeletal Radiology* 1993; 22 (5): 375-377.