



Clinical Research

A new approach for diagnosis of leiomyoma and leiomyosarcoma: A stereological study

Önder Şahin^a, Cemal Gündoğdu^b, Bünyami Ünal^c, Hüseyin Aslan^d, Bünyamin Şahin^e, Süleyman Kaplan^{f*}

^a Istanbul University, Institute for Experimental Medical Research, Istanbul, Turkey

^b Department of Pathology, Medical Faculty, Atatürk University, Erzurum, Turkey

^c Department of Histology and Embryology, Medical Faculty, Atatürk University, Erzurum, Turkey

^d Department of Histology and Embryology, Medical Faculty, Gaziosmanpaşa University, Tokat, Turkey

^e Department of Anatomy, Medical Faculty, Ondokuz Mayıs University, Samsun, Turkey

^f Department of Histology and Embryology, Medical Faculty, Ondokuz Mayıs University, Samsun, Turkey

ARTICLE INFO

Article History

Received 15 / 04 / 2010

Accepted 20 / 04 / 2010

* Correspondence to:

Süleyman Kaplan

Department of Histology and Embryology,
Medical Faculty Ondokuz Mayıs University,
Samsun, Turkey

e-mail: skaplan@omu.edu.tr.

Key Words :

Leiomyoma

Leiomyosarcoma

Mitotic Cell

Tumor

Stereology

Optical Disector

ABSTRACT

Leiomyoma is a common benign tumor of the genital system; diseases and other types of smooth muscle tumors in females is called leiomyosarcoma. The diagnosis of these tumors is based on differentiation of the degree of cellularity and cytological atypia, presence of necrosis and particularly the mitotic index. A treatment procedure is proposed regarding to the diagnosis of leiomyoma and leiomyosarcoma. There is no exact agreement on diagnosis of these tumors and the available methods are biased and dependent on the judgment of the observers. Our aim is to evaluate the leiomyoma and leiomyosarcoma type of tumors using design-based stereological methods. The number of cells showing mitosis within a reference volume was determined to diagnose the type of tumor as leiomyoma or leiomyosarcoma. Numerical density of mitotic figures was 8000-9000/mm³ for leiomyoma, 10.000-11.000/mm³ for leiomyoma with high mitotic activity, and 30.000-31.000/mm³ for leiomyosarcoma. The difference between leiomyoma and leiomyosarcoma was significant (p<0.001). These results show that the proposed method of providing the numerical density of mitosis for the diagnosis of leiomyosarcoma is unbiased, objective, and reliable. Moreover the method is more effective and easier to use than a morphometric method.

J. Exp. Clin. Med., 2009; 26:119-123

© 2009 OMU All rights reserved

1. Introduction

Smooth muscle neoplasms are common uterine tumors. One of them is leiomyoma. The overall incidence is between 4% and 11%, but it rises to nearly 40% in women over the age of 50 (Rosai, 2004). Leiomyosarcoma represents about 1.3% of uterine malignancies (Zaloudek and Hendricson, 2002). Clinical symptoms of the leiomyoma are asymptomatic, or metrorrhagia and menorrhagia. On the other hand, leiomyosarcomas cause abnormal vaginal bleeding, abdominal and pelvic pain, and formation of abdominal masses (Hart and Billman, 1978; King et al., 1982; Covens et al., 1987; Larson et al., 1990). The usual features of leiomyoma are characteristically a whorled cut surface, easily shelled out from the surrounding myometrium, and mitotic figures are none or rare. On a gross examination, the typical leiomyosarcoma is large, fleshy, infiltrative, necrotic and obviously malignant (Hendricso and Kempson, 1995). However, these clinical

features and gross appearance do not reflect an exact criterion for diagnosis. The clinical diagnosis of tumor types should be made with confidence using a handful of conventional light microscopic features (Hendricso and Kempson, 1995).

The differential diagnosis of these tumors is based on the degree of cellular differentiation and cytological atypia, the presence of necrosis and particularly the mitotic index. To know the number of mitotic figures is very important since treatment for the patient is proposed according to the diagnosis of leiomyoma or leiomyosarcoma (Marshall, 1986; Robboy et al., 2000; Mehning, 2003). The behavior of uterine smooth muscle cell tumors may be difficult to recognize when using traditional histopathological techniques (Robboy et al., 2000). Moreover, we are not able to find an unbiased approach independent of the observers for distinguishing the type of these tumors.

We propose a stereological approach for the assessment of the type of tumor using microscopic sections. For this purpose, we used the physical fractionator method, which is one of the most commonly used design-based stereological methods in morphometric analysis, with the combination of an optical disector counting method and a systematic uniform random sampling scheme.

2. Material and Methods

The present study was performed on 42 cases of leiomyoma (cellular, vascular and cases with low and high mitotic activity) and leiomyosarcoma in which the diagnosis was established following selection of macroscopically significant pieces at the Department of Pathology (in the Medical School of Ataturk University). The cases enrolled in the study were myomectomy, total abdominal hysterectomy, and oophorectomy. Specimens were obtained after the operations and sent to our department. We applied a combination of the physical fractionator with optic disector methods for the analysis of specimens taken from patients. The number of mitotic figures per unit volume was estimated. At the end of stereological analysis we divided the specimens into three groups, namely leiomyoma (n=17), leiomyosarcoma (n=20) and leiomyoma with high mitotic activity (n=5). This study was conducted according to institutional guidelines, and the Human Ethics Committee on the use of human tissues of Ataturk University School of Medicine approved the protocol.

2.1. Management of the fractionator method

A leiomyoma nodule was cut into 10-15 slices as the first step of the sampling procedure. Theoretically, during slicing and cutting process, each tissue piece should be parallel to each other. This can be achieved by visual estimation as well as with a special device called a fractionating knife that has been designed with knives fixed at equal distances (Gundersen, 1977; Gundersen, 1986; Sahin et al., 2001). The steps of this process are shown in detail at Fig. 1.

2.2. Obtaining the slices

The tissue blocks of the myoma nodules were obtained by the physical fractionating method according to a systemic random sampling scheme. The number of tissue blocks of the each nodule was changed depending on the size of the nodules. The selected samples were embedded in paraffin after routine histological processes. Each tissue block was cut in a forty-micron-thickness section from the beginning to the end of block. The section sampling fraction was 1/5, a fraction that was determined after a pilot study. After random determination of the first section within 5, then every 5th section was selected as a sample section (Gundersen and Jensen, 1987; Con et al., 2003). This sampling was recorded as a section sampling fraction (ssf, 1/5). The sampled sections were stained with hematoxylin and eosin.

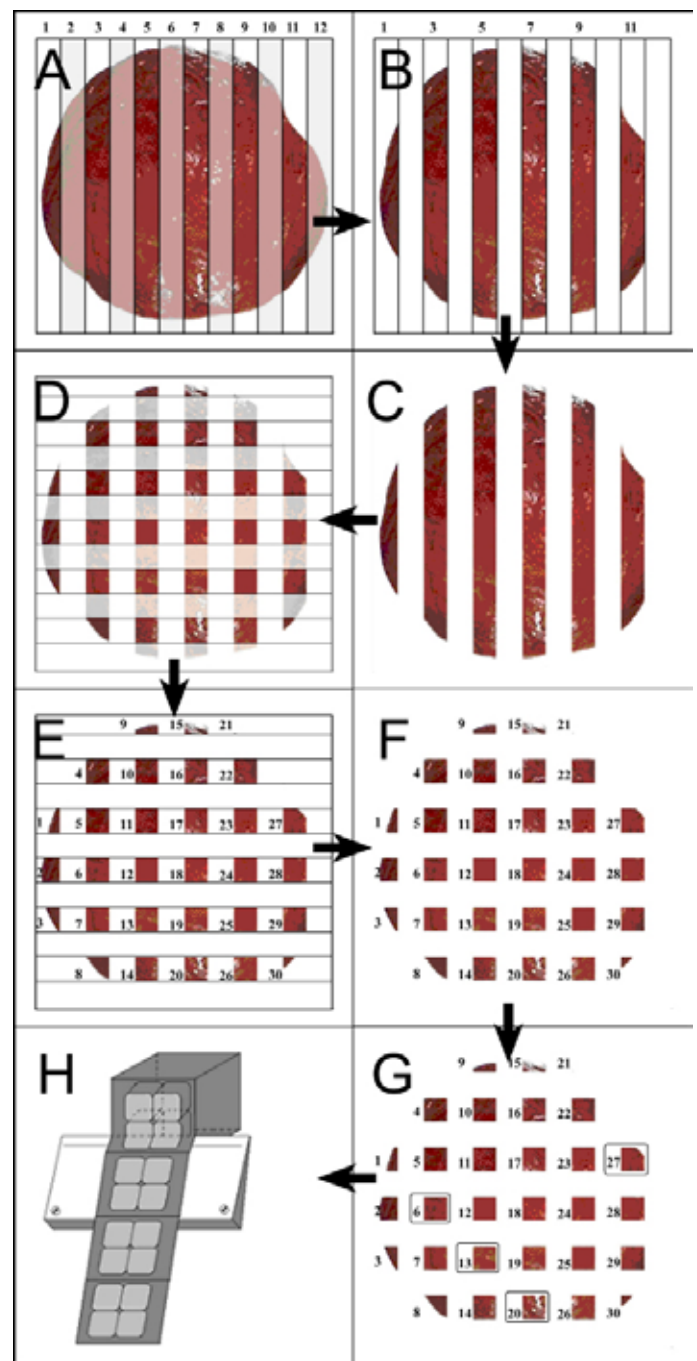


Fig. 1: The schematic view of the systematic random fractionating process on the myoma nodule. The sample is cut into parallel slabs (A) and at the end of the first systematic random fractionating step at $\frac{1}{2}$ ratio half of the slabs are retained (B, C). All the obtained slabs are subsequently put into a row and the following steps are taken. The slabs are cut into strips and finally cubed (D). The last cubic rows are sampled at $\frac{1}{2}$ ratio and one out of two rows are excluded (E). The remaining cubic samples are given consecutive numerals (E, F), and the selected fragments following the $\frac{1}{7}$ random sampling at the last sampling step is shown in (G). All the remaining cubes are embedded in paraffin and these tissues are again fractionated with a microtome knife as consecutive sections (H).

2.3. Microscopy stages

The mitotic figures in the stained sections were counted using the optical disector counting method at a semiautomatic stereology workstation for stereological analyses composed of a CCD digital camera (Nikon Coolpix E 4500, Tokyo, Japan), image capture card (Flash Point 3D, Integral Technologies, Indianapolis, Ind., USA); a personal computer and computer controlled motorized specimen stage (Prior, Rockland, MA, USA), a microcator

(Heidenhein, Traunreut, Germany) and a light microscope (Nikon, Eclipse E 600, Tokyo, Japan) were used. Mitotic figures were counted using a 100× Nikon Plan Apo objective (NA = 1.40) and total magnification was 1680, which allowed for accurate recognition. Each mitotic figure was counted according to the unbiased counting rules of the optical disector (Howard and Reed, 1998).

According to the pilot work, it was found that a step size with 280900 μm^2 (530×530 in X and Y axis) for microscopic sampling would be suitable to perform stereological analysis on sampled sections of myoma nodules. In all the steps, an unbiased counting frame with 900 μm^2 size was used (Fig. 2). Thus, an area sampling fraction for this analysis was 900/280900.

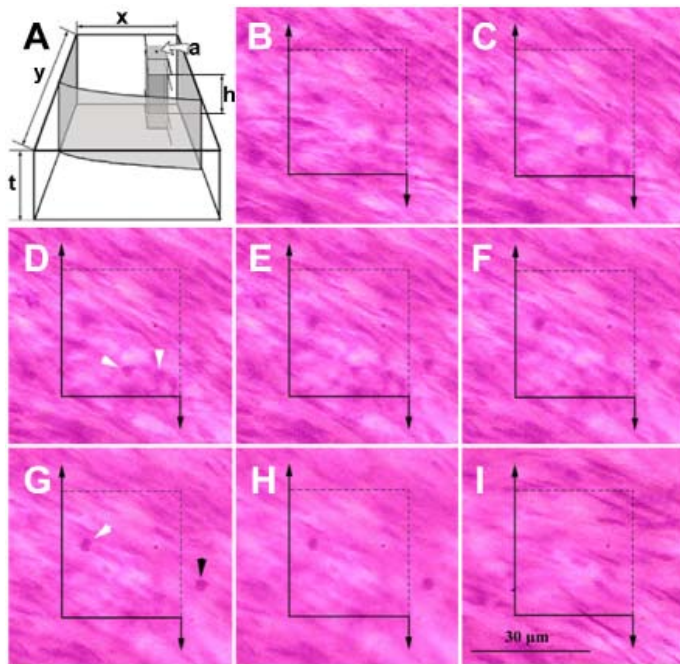


Fig. 2: The micrographs belong to the optical section of the disector in a thick section. These micrographs were taken through the upper to lower surface of the section. The forbidden lines of unbiased counting frame and its extensions were drawn as a solid line; countable edges were drawn as an interrupted line. The focal plane of the lens is changed from the upper to the bottom surface of section; if a mitotic figure is within the unbiased counting frame or superimposed with interrupted lines of the frame but not with solid lines and their extensions, these figures count as a disector particle. Prior to the focus plane approach to section, images taken from the top of the section to the bottom are changed, the first optical section being seen in (A). The upper surface of section determined if the type of tissue could be clearly distinguished. After determination of the upper surface of the section, 5- μm -thickness of a guard zone from the surface of section was left. Counting of mitotic figures was begun after this zone (B). While the focal plane of lens goes into the section, micrographs in the optical section were taken in a 3- μm -interval. The disector particle (i.e. mitotic figure) was counted at the focus plane in which they were observed clearly in the largest number according to the counting rules of the disector counting rule. Three mitotic figures, shown by a white arrowhead, were enrolled in the unbiased counting frame and counted as a disector piece (C-G). The mitotic figure, shown by a black arrow, was kept out of the frame (G). The view plane seen clearly is the lower plane of section (H). There was not a tissue view out of the focal plane of the section at the bottom (I). The distance between lower and upper face of section (h) was measured as 28m. In this disector volume, three disector particles were counted (white arrow head). Hematoxylin and eosin staining.

According to the optic disector counting rules, each disector probe means that a three-dimensional counting box had to be smaller in height than the section

thickness. Hence, the height of the disector probe was 15- μm . The thickness sampling fraction was disector height/mean section thickness (t). All mitotic figures were counted in each sampled disector probe on the sampled sections during stereological analysis (Gray, 1996).

All the specimens taken from 42 patients were analyzed using the stereological approach described above. The mean numbers of the mitotic figures for each patient were calculated. At the conclusion of the stereological analysis the specimens were divided into three groups: namely, leiomyoma (n=17), leiomyosarcoma (n=20) and leiomyoma with high mitotic activity (n=5). Further investigations were done according to the group classification.

2.4. Statistical Analysis

The mean total numerical values (N), mean numerical densities (Nv) and mean volume values of patients with uterine smooth muscle tumors were compared individually and correlated. Kruskal-Wallis variation analysis and Mann Whitney U tests were used to define any relationship between them. P=0.001 was accepted as significant.

3. Results

The comparison of the mitotic figure counts of leiomyoma (17 cases), leiomyosarcoma (20 cases), and leiomyoma with mitotic activity (5 cases) showed that there were significantly higher levels of mean total mitotic figure in leiomyosarcoma than in leiomyoma and leiomyoma with high mitotic activity. This difference was statistically significant (P<0.001) (Fig. 3). The numerical densities of mitotic figures in cases of a leiomyoma nodule, leiomyoma with high mitotic activity and leiomyosarcoma were estimated by dividing the total number of mitotic figures by mean volumes (mm^3) of the tumor. It was found that the mean numerical densities of a leiomyoma nodule,

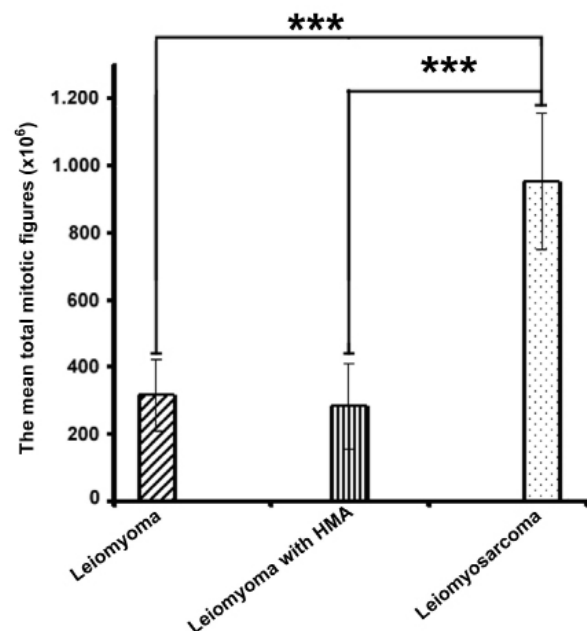


Fig. 3: The comparison of the mean total mitotic figures of the cases (P<0.001).

a leiomyoma with mitotic figure and leiomyosarcoma showed significant differences from each other ($P < 0.001$) (Fig. 4 and Fig. 5).

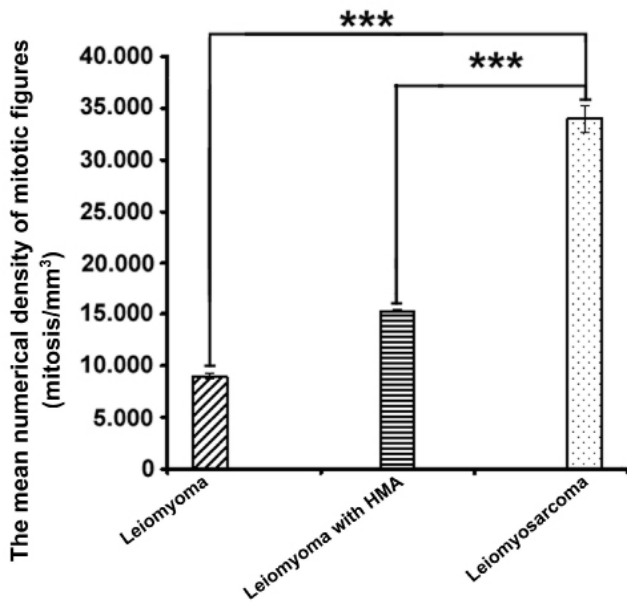


Fig.4: The comparison of the numerical densities of total mitotic figures of cases with leiomyoma, leiomyosarcoma and leiomyoma with mitotic activity (Nv) ($P < 0.001$).

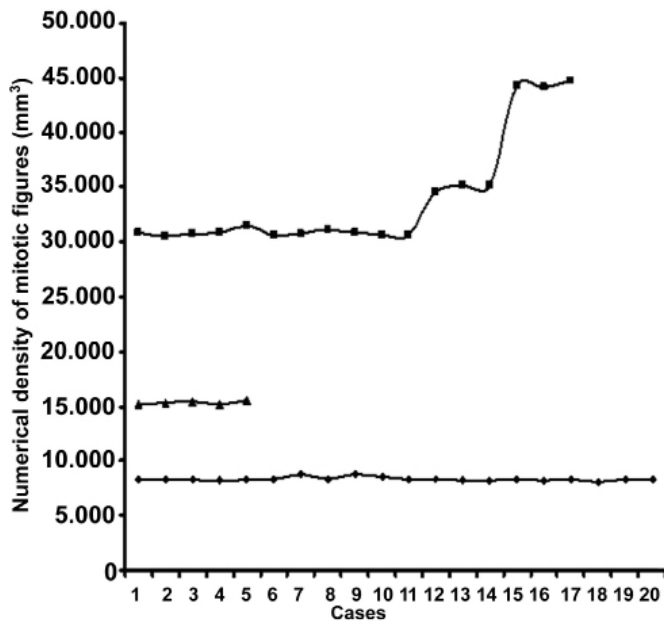


Fig.5: The numerical density value distribution (Nv) of total mitotic figures in cases with leiomyosarcoma (squares), leiomyoma (diamond) and leiomyoma with mitotic activity (triangles).

4. Discussion:

Uterine leiomyosarcoma is a rarely seen smooth muscle neoplasm and has an extremely high malignant potential. It comprises 1% of all uterine malignancies and 25-36% of sarcomas. Five-year survival of patients with leiomyosarcoma is approximately 65% (Leibsohn et al., 1990). Clinical symptoms of patients with uterine leiomyosarcoma are abnormal bleeding, abdominal pain and/or pelvic mass. The prognostic categorization at light microscopic evaluation is essential in uterine smooth

muscle tumors. Multiple prognostic parameters such as mitosis rate, nuclear polymorphism, presence or absence of necrosis are suggested. Unfortunately it has been seen that these parameters have not been sufficient (Mehring, 2003). Most of the smooth muscle neoplasms arising from myometrium are classified as benign or malign according to their degree of mitotic index and nuclear atypia, but such an approach is inadequate to determine the character of the neoplasm (Layfield et al., 2000). In several studies, five or more mitosis/cytological atypia at 10x magnification were defined as leiomyosarcoma. But this definition is inadequate and fails as an unambiguous diagnosis, because some cases defined as benign by this method were later found to be malignant (Layfield et al., 2000). Most of the preliminary classifications are based on the mitotic rate and their prognosis is related to the mitotic index. Evaluation of the nuclear atypia is also subjective. Although the mitosis number is an objective parameter, the sampled microscopical area and its size, fixation type, severity of the tumor, and section thickness may affect the estimation of the mitotic figure number (Andersen et al., 1992; Layfield et al., 2000). Moreover observer variance among pathologists on the number of mitotic figures is very high. Because of the innate difficulty of evaluating mitotic activity, some smooth muscle neoplasms exhibiting very low mitotic activity at the beginning have later been shown to have a high mitotic activity, and may show multiple metastatic focuses in the tissue (Layfield et al., 2000). Bell and a coworker recommended a classification that depended on a combination of nuclear atypia, absence or presence of tumor necrosis and mitosis rate (Andersen et al., 1992). But these parameters are still subjective and biased (Gundersen et al., 1988).

A neoplasm of uterine smooth muscle has been studied with new advances of technological developments, and also the insufficiency of H.E. stained sections for diagnosis of a neoplasm has also been discussed (Layfield et al., 2000). In particular, studies dealing with mitosis, atypia and the prognostic parameters of leiomyosarcoma have been done between 1935-1990 (Mayerhofer et al., 1999). However, the difficulties in determining the mitotic figure at different microscopic magnifications also affect the diagnosis of a tumor. Necrosis, differentiation degree, vascular invasion, and morphology of adjacent tissues were also included in mitosis and atypia criteria. But all these parameters could not be met each time because of the difficulties in getting all of them in each inspected area (Mayerhofer et al., 1999). In recent years, technological inventions, new image analysis systems and stereological methods offer a new reliable and accurate approach to the subjective criteria for tumor diagnosis. These methods give us new windows for accurate diagnosis of leiomyoma and leiomyosarcoma.

In the present study we have reported an unbiased, simple and reliable method to distinguish leiomyoma from leiomyosarcoma using stereological methods. If the mean total mitotic figure number and numerical density of

figure in unit volume (mm^3) is estimated in leiomyoma, leiomyoma with high mitotic activity and leiomyosarcoma, the result might show the real message of neoplastic tissue. One of the important parameters in the present approach is that the numerical density of mitotic figures was evaluated within the unit volume. As seen from the results, the numbers of mitotic figures in each group are significantly different from each other. If one uses the proposed stereological methods, results of tumor diagnosis might be reliable and accurate, since clearly there is a very sharp border between estimated figures, for example 8000-9000/ mm^3 for leiomyoma versus to 30000-31000/ mm^3 for leiomyosarcoma, since the difference between the two tumors is about threefold. It should also be kept in mind that the numerical density parameter should be estimated

by dividing the total number of mitotic figures by the volume of the tumor. If numerical density is calculated from such approach it would be more objective than the routinely used subjective criteria that are affected by tissue process, selected area for examination, section thickness, interobserver and intraobserver variation. The application of the present method on more samples than used in this study could provide a cut-off level for the differential diagnosis of leiomyoma and leiomyosarcoma.

These results show that the proposed method of providing the numerical density of mitotic figure for the diagnosis of leiomyoma, leiomyoma with mitotic figures and leiomyosarcoma is unbiased, objective, and reliable. However, the application of the method requires following the procedure of the described stereological steps.

REFERENCES

- Andersen, B.B., Korbo, L., Pakkenberg, B., 1992. A quantitative study of the human cerebellum with unbiased stereological techniques. *J. Comp. Neurol.* 326, 549-560.
- Con, N., Canbilien, A., Bradley, P.M., 2003. Quantitative features of the nucleus rotundus in the brain of pre and post hatch chicks. *Dev. Brain Res.* 146, 71-77.
- Covens, A.L., Nisker, J. A., Chapman, W. B., 1987. Uterine sarcoma: an analysis of 74 cases. *Am. J. Obstet. Gynecol.* 156, 370-374.
- Gray, T., 1996. Quantitation in histopathology. In: Bancroft JD, Stevens A, eds. *Theory and Practice of Histological Techniques*. New York: Churchill Livingstone. 641-673.
- Gundersen, H. J., Bagger, P., Bendtsen, T. F., 1988. The new stereological tools: disector, fractionator, nucleator and point sampled intercepts and their use in pathological research and diagnosis. *APMIS.* 96, 857-881.
- Gundersen, H. J. G., Jensen, E. B., 1987. The efficacy of systematic sampling in stereology and its prediction. *J. Microsc.* 147, 229-263.
- Gundersen, H. J. G., 1977. Notes on the estimation of the numerical density of arbitrary particles: the edge effect. *J. Microsc.* 111, 219-223.
- Gundersen, H. J. G., 1986. Stereology of arbitrary particles. A review of unbiased number and size estimators and the presentation of some new ones, in memory of William R. Thompson. *J. Microsc.* 143, 3-45.
- Hart, W. R., Billman, J. K. 1978. A reassessment of uterine neoplasms originally diagnosed leiomyosarcomas. *Cancer.* 41, 1902-1910.
- Hendricso, M., Kempson, R. L., 1995. Pure mesenchymal neoplasms of the uterine corpus. In: Fox H, Wells M, eds. *Haines&Taylor Obstetrical and Gynecological Pathology*. New York: Churchill Livingstone. 511-586.
- Howard, C. V., Reed, M. G., 1998. *Unbiased Stereology: Three dimensional measurement in microscopy*, Oxford: Bios Scientific Publishers.
- King, M. E., Dickersin, G. R., Scully, R. E., 1982. Myxoid leiomyosarcoma of the uterus: a report of six cases. *Am. J. Surg. Pathol.* 6, 589-598.
- Larson, B., Silfversward, C., Nilsson, B., 1990. Prognostic factors in uterine leiomyosarcoma. A clinical and histopathological study of 143 cases. The Radiumhemmet series 1936-1981. *Acta. Oncol.* 29, 185-191.
- Layfield, L. J., Liu, K., Dodge, R., 2000. Utility of classification by proliferation, ploidy, and prognostic markers versus traditional histopathology. *Arch. Pathol. Lab. Med.* 124, 221-227.
- Leibsohn, S., d'Ablaing, G., Mischell, D. R., 1990. Leiomyosarcoma in a series of hysterectomies performed for presumed uterine leiomyomas. *Am. J. Obstet. Gynecol.* 162, 968-974.
- Mayerhofer, K., Obermair, A., Windbichler, G., 1999. Leiomyosarcoma of the uterus: A clinicopathologic multicenter study of 71 cases. *Gynecol. Oncol.* 74, 196-201.
- Marshall, R. J., Braye, S. G., Jones, D. B., 1986. Leiomyosarcoma of the uterus with giant cells resembling osteoclasts. *Int. J. Gynecol. Pathol.* 5, 260-268.
- Mehring, P. M., 2003. Alterations in the female reproductive system. In: Carol P, Gaspard Kathryn J, eds. *Essentials of Pathophysiology*. New York: Lippincott Williams & Wilkins. 602-626.
- Robboy, S. J., Bentley, R. C., Butnor, K., 2000. Pathology and pathophysiology of uterine smooth-muscle tumors. *Environ Health Perspect.* 108, 779-844.
- Rosai, J., 2004. *Surgical Pathology*. Edinburg: Mosby.
- Sahin, B., Aslan, H., Unal, B., 2001. Brain volumes of the lamb, rat and bird do not show hemispheric asymmetry: a stereological study. *Image Anal. Stereol.* 20, 9-13.
- Zaloudek, C., Hendricson, M. R., 2002. Mesenchymal tumors of the uterus. In: Kurman RJ, ed. *Blaustein's Pathology of the Female Genital tract*. New York: Springer-Verlag. 561-615.