

Preventive Effects of Bovine Gallstone on Murine Colon Neoplasia: Room for Improvement?

● Ibrahim DEMIRKAN*¹, ● Ece KAVAS², ● Mehmet Fatih BOZKURT³,
● Musa KORKMAZ¹, ● Ibrahim KILIÇ⁴, ● Taner KAVAS⁵

¹Department of Surgery, Faculty of Veterinary Medicine, Afyon Kocatepe University, 03200, Afyon, Turkey.

²School of Medicine, İstanbul Medipol University, 34810, Beykoz, İstanbul/Turkey.

³Department of Pathology, Faculty of Veterinary Medicine, Afyon Kocatepe University, 03200, Afyon, Turkey.

⁴Department of Biostatistics, Faculty of Veterinary Medicine, Afyon Kocatepe University, 03200, Afyon, Turkey.

⁵Department of Material Sciences and Engineering, Faculty of Engineering, 03200, Afyon Kocatepe University, Afyon, Turkey.

Received 20-08-2021 Accepted 04-05-2023

Abstract

Bovine gallstone (BGS) has been suggested to be used in the treatment of many diseases including neoplastic maladies in traditional medicine. Thus, this study aimed at evaluating the possible protective effects of BGS in mice colon tumor models. In the experiment, 8-week-old 30 male BALB/c mice weighing 25-30 g were randomly allocated into the control group (n=6), tumor group ((n=6; tumor induced by 1,2- dimethylhydrazine? [DMH]), BGS>DMH group (n=6; BGS given before DMH challenge), BGS//DMH group (n=6; simultaneous administration of BGS and DMH) and DMH>BGS group (n=6; tumor induced by DMH then BGS given). The colonic tumor was induced by weekly subcutaneous injection of DMH at a 20 mg/kg/mouse dose for consecutive 11 weeks. BGS preparations were given to mice cyclically. Atypical cryptic foci formation in the colon was examined by histopathological staining. The lowest rate of colon tumor was noted in BGS>DMH group where BGS was given prior to tumor challenge. In addition, simultaneous administration of DMH and BGS to mice inhibited tumor formation and development more significantly than those in other groups (except for BGS>DMH group). It was concluded that BGS significantly prevented colonic tumor formation if given to subjects before or during tumor challenge however, therapeutic capacity of BGS was not promising in this study.

Keywords: Bovine, colon, gallstone, mouse, neoplasia.

Introduction

Humans and animals during their lifetime encounter several diseases and make use of various methods and strategies to tackle them in advance. Colon cancer (CC) is probably one of the most common malignant maladies associated with significant mortality both in humans and animals, worldwide. In cats and dogs, the most common gastrointestinal tract tumors occur in the colon and rectum after tumors in the oral cavity. The average age of gastrointestinal tumors is observed between the age of 6-9 years.^{1,2} Adenomatous polyps are the most common tumor type in the canine and feline colon and rectum.³⁻⁵ 40% of these are benign and 60% are malignant tumors.⁶ In humans, the incidence may reach up to the highest rate at the ages of 60 and over, however, 20% of patients experiencing colon

tumors are under 50 years old. Men concerning women have a higher predisposition due to age-related deaths.⁷ Prevalence of CC shows significant differences between geographic regions, as frequently observed in the USA, Australia, New Zealand, Scandinavia and western Europe while less commonly in Asian and African countries.⁸ In the USA, it was reported that 5% of the population developed CC and 40% died because of the high metastatic nature.⁹ Once metastasized, aggressive therapies are indicated which generate significant side effects on patient's physiologic and moral status. There is no gold standard or therapy protocol that safely and significantly regresses the condition. Such chemotherapy, radiotherapy, surgery and advanced modalities are all used with great concern to reduce complications though they are not always successful. The location and size of CC are highly crucial for the selec-

* Corresponding author: İbrahim Demirkan, Department of Surgery, Faculty of Veterinary Medicine, Afyon Kocatepe University, 03200, Afyon, Turkey. Tel: 0532 635 5630, E-mail: idemirkan@aku.edu.tr

tion of surgical intervention. In most cases, partial colectomy is the choice of treatment once performed at early the stages.¹⁰ Most of the anti-tumor agents are cytotoxic and designed to inhibit the growth of the mass including a great amount of healthy cells. Thus, the need for alternative treatment options especially a preventive approach is inevitable for colon tumors in this context.

In traditional medicine, animal-derived bile and gallstones that contain high amounts of bile acids, have been used for a long history in many countries including China, Japan, Korea, and India. Moreover different species of biles have been recorded in national pharmacopoeias.¹¹⁻¹³

Gallstone is a naturally occurring stone in the gallbladder of humans and animals.¹⁴⁻¹⁷ They are usually brown, but sometimes close to yellowish colour. These stones are formed anywhere in the bile ducts, including the gallbladder and bile ducts. BGS can be of various sizes from sandstone to walnut. The understanding of the formation process of gallstone has improved considerably in recent years. Hereditary factors, body weight, gallbladder movement and possibly feeding have been shown to cause BGS generation.^{18,19} The process of formation of gallstone and how it is used for treatment purposes in many acute and chronic ailments, has been known and applied by Traditional Chinese Medicine (TCM) since ancient times (c.a. 7th century).²⁰⁻²¹

In TCM, cholelithiasis (chole = gall; lith = stone), laymen call gallstones, has been used for several centuries for several diseases such as heart disorders, oral wound and throat infections, cancer and mental disorders. They inhibit involuntary spasms and prevent loss of consciousness due to elevated body temperature.²² However, some researchers claim that the therapeutic effect of gallstone comes from ancient Indian medicine and that this information was later used by the Chinese. Contrary to this information, it is possible to come across many arguments that gallstone is a commercial commodity (today it is commercially available online market as 1 g price is \$1-10). Thus, this study aimed at setting a scientific light on a traditional understanding of anti-tumorigenic effect of bovine gallstone (BGS) in a model of murine colon tumor induced by chemical agent 1,2-dimethylhydrazine (DMH).

Material and Methods

Statement of Ethics: The animal procedure used here was approved by the local ethical committee of Afyon Kocatepe University, Turkey (No: AHU-HADYEK-49533702/106-508-15) and all interventions

were carried out under the laboratory animal handling and animal experiments guidelines of the University.

Preparation and analysis of BGS: Afyon city in Turkey is the leading large animal husbandry and abattoir in the country. Within the scope of this study, BGS was obtained from local dealers who traditionally hold them for various purposes. Stones were dried at 22 ± 2 °C for 3 days and then granulated down to very fine powder form in less than 45µm at the laboratory type ceramic coated ball mill because of undesired residue during the grinding process. The powder form of BGS was dissolved in pure water and freshly prepared before use.

For crystallographic evaluation, X-ray diffraction (XRD) analysis with a Cu-K α radiation source and a voltage of 40 kV with an ampere of 30 mA was carried out via Bruker D8 Advance (Afyon, Turkey). The measurements were performed in the range of 2° to 80° by applying a step size of 0.02°. The BGS specimens were subjected to microstructural analysis and examined by scanning electron microscopy (SEM). Chemical analyses were achieved by the EDX device (LEO 1430, Afyon/Turkey).

Animals and handling: Eight-week-old BALB-c mice (n=30) weighing 25-30 g were housed in cages with no contact between groups. Fresh water and standard mouse feed were provided ad libitum. Room temperature was set at between 19 and 21 °C with a humidity of $50\pm 20\%$ and 12 hours light-12 hours dark.

Production of colon tumors: To induce a high rate of colon tumors mice were subcutaneously administered at a dose of 20 mg DMH/kg body weight weekly for 11 consequent weeks. DMH was freshly prepared in 0.05% EDTA and NaHCO₃ at pH of 6.5 before use.

Experiment: Animals were randomly allocated into five groups. The control group (n=6) were fed only normal ration, DMH group (n=6) was tumor control group that received DMH, animals in BGS>DMH group (n=6) had per oral BGS for 5 days before the DMH injection, then weekly subcutaneous DMH administration for 11 weeks and the cyclic BGS administration (every other day) continued until the end of the study. In the BGS//DMH group (n=6) DMH injection (once a week for 11 weeks) and the cyclic BGS (until the end of the experiment) were simultaneously administered and DMH>BGS group (n=6) after the last injection of DMH (once a week for 11 weeks) the BGS administration was initiated until the end of the experiment.

Histopathologic examination: The experiment was terminated in the 8th week after the last DMH administration. All animals were sacrificed by cervical dislocation under general anaesthesia by intramuscular administration of 15 mg/kg xylazine (Rompun®, Bayer, Germany) and 50 mg/kg ketamine HCl (Alfamine®, Egevet, Turkey). The colon was removed from abdomen, cleaned and prepared for histopathological examination. In order to obtain full length of colon and observe the maximum tissue thickness, Swiss-roll method was carried out.²³ Briefly, the colon was slit open longitudinally and the contents carefully removed. Then the colon was rolled up longitudinally, taking care with the mucosa facing outwards, using a wooden stick. Finally, Swiss roll was kept in 10% formalin at 4 °C for 48 h for fixation. From paraffine embedded colon 5 µm thick sections were prepared and stained with hematoxylin and eosin (HE).




Figure 1. SEM image of BGS.

In order to count hyperplastic and dysplastic atypical cryptic foci (H-acf and D-acf, respectively) analysis, acfs were counted by histopathological examination by a modified method of Sengottuvelan et al.²⁴ A table was created by counting H-acf, D-acf and hyperplastic lymph follicles (H-lf) one by one in all colon areas in the sections prepared by Swiss roll technique. Acf detected microscopic fields were counted and scored as 3 degrees as mild (1-3 acf), moderate (4-6 acf) and severe (more than 6 acf).

Statistical analysis: Differences between groups, according to the degrees of the H-acf, D-acf and H-lf parameters, were determined by the Chi-square test. The significance was set at $p < 0.05$. The data were analysed with SPSS 21.0 for windows program.

Results

SEM images confirmed that the microstructure of BGS was not polycrystalline but included branched, quite amorphous micro-porous and formed by creating a mesh in a three-dimensional plane (Figure 1). In XRD pattern, it can be seen that the structure of BGS was amorphous and supported by the microstructure image taken. This means that it did not have a uniformly ordered structure (Figure 2). In addition, the hump shape was visible. Further, elementary analysis was achieved by EDX technique. It was revealed that the BGS consisted of main calcium (Ca), sodium (Na), sulfur (S) and oxygen (O) elements, respectively (Figure 3).

BGS powder dissolved in water was given at a dose of 5 mg/kg for each mouse by oral route at a volume of 0.5 ml. Stool structure, urination, feed and water consumption were in the normal range in all animals studied at this dose.

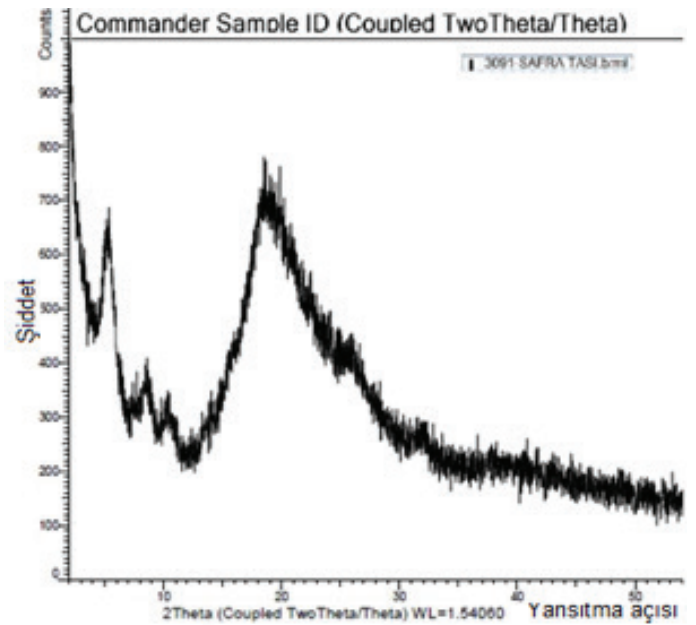


Figure 2. X-ray diffraction of BGS by XRD.

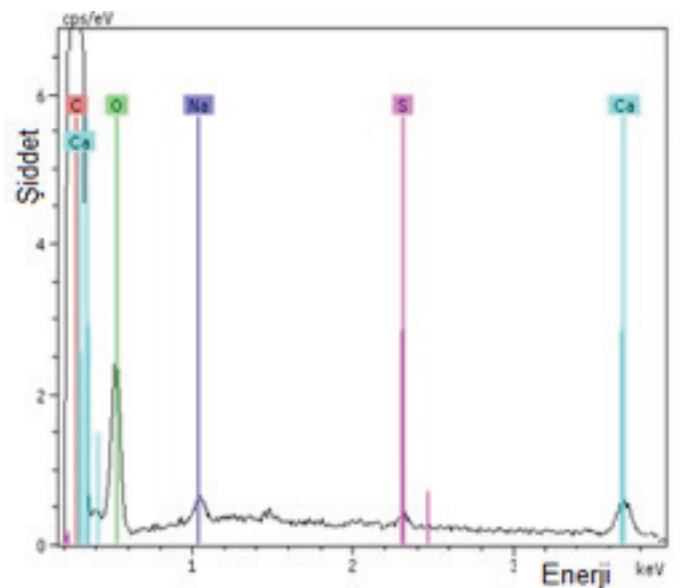


Figure 3. Chemical analysis of BGS by EDX.

Table 1 Comparisons of groups for H, D and L parameters with respect to atypical cryptic foci (ACF).

Groups	N	Mi	Mo	S	N	Mi	Mo	S	N	Mi	Mo	S	N	Mi	Mo	S	
Control	n	6	0	0	0	6	0	0	0	6	0	0	0	18	0	0	0
	%	100	0,0	0,0	0,0	100	0,0	0,0	0,0	100	0,0	0,0	0,0	100	0,0	0,0	0,0
DMH	n	1	5	0	0	1	3	2	0	1	2	0	3	3	10	2	3
	%	16,7	83,3	0,0	0,0	16,7	50,0	33,3	0,0	16,7	33,3	0,0	50,0	16,7	55,6	11,1	16,7
BGS>DMH	n	0	6	0	0	2	4	0	0	2	4	0	0	4	14	0	0
	%	0,0	100	0,0	0,0	33,3	66,7	0,0	0,0	33,3	66,7	0,0	0,0	22,2	77,8	0,0	0,0
BGS//DMH	n	0	6	0	0	1	0	5	0	1	1	3	1	2	7	8	1
	%	0,0	100	0,0	0,0	16,7	0,0	83,3	0,0	16,7	16,7	50,0	16,7	11,1	38,9	44,4	5,6
DMH>BGS	n	2	4	0	0	0	2	1	3	0	3	2	1	2	9	3	4
	%	33,3	66,7	0,0	0,0	0,0	33,3	16,7	50,0	0,0	50,0	33,3	16,7	11,1	50,0	16,7	22,2
P		0,001*				0,001*				0,003*				0,001*			

*p<0,01; N: None, Mi: Mild, Mo: Moderate, S: Severe.

When histopathological sections were examined, significant differences were observed between the groups according to the H-acf, D-acf and H-lf values ($p<0.01$) (Table 1). For the H-acf parameter, 16.7% of mice were not developed H-acf while 83.3% developed mildly in the DMH group; 100% mild development of H-acf in BGS>DMH and BGS//DMH groups were observed; In the DMH>BGS group, 33.3% did not develop H-acf, while 66.7% developed mild H-acf. For parameter D-acf, 16.7% of the DMH group did not develop D-acf, while 50% was mild, 33.3% was moderate; in the BGS>DMH group, 33.3% did not generate D-acf while 66.7% developed mild D-acf; in the BGS//DMH group, 16.7% did not produce D-acf however 83.3% developed D-acf from moderate to severe degrees; in the DMH>BGS group, 33.3% developed mild, 16.7% moderate and 50% severe D-acf. For the H-lf parameter, 16.7% of the DMH group did not develop H-lf, while 33.3% developed mild and 50% severe; in the BGS>DMH group, 33.3% did not develop H-lf whereas 66.7% developed mild and 50% severe H-lf; in the BGS//DMH group, 16.7% did not display H-lf, but acf was mild in 16.7%, moderate in 50% and severe in 16.7% animals; in the DMH>BGS group, 50% of H-lf were mild, 33.3% of moderate and 16.7% of severe.

In terms of the sum of H-acf, D-acf and H-lf values, neither H-acf/D-acf nor H-lf development was observed in 16.7%

of animals whereas 55.6% developed mild, 11.1% moderate and 16.7% severe. While 22.2% did not develop any acf in the BGS>DMH group, 77.8% developed mildly. In the BGS//DMH group, 11.1% did not develop acf, while 38.9% developed mild, 44.4% moderate and 5.6% severe. No acf formation was seen in 11.1% of mice but 50% of them developed mild, 16.7% moderate and 22.2% severe acf in the DMH>BGS group.

According to these results, the degrees of acf in DMH and DMH>BGS groups were almost similar. In the BGS//DMH group, the moderate rate was the highest, whereas, in the BGS>DMH group, either none or mild rate was observed (Figure 4).

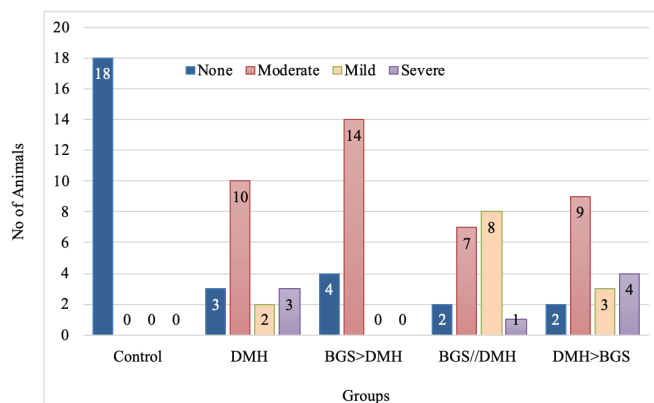


Figure 4. Comparison of all groups with respect to ACF formations.

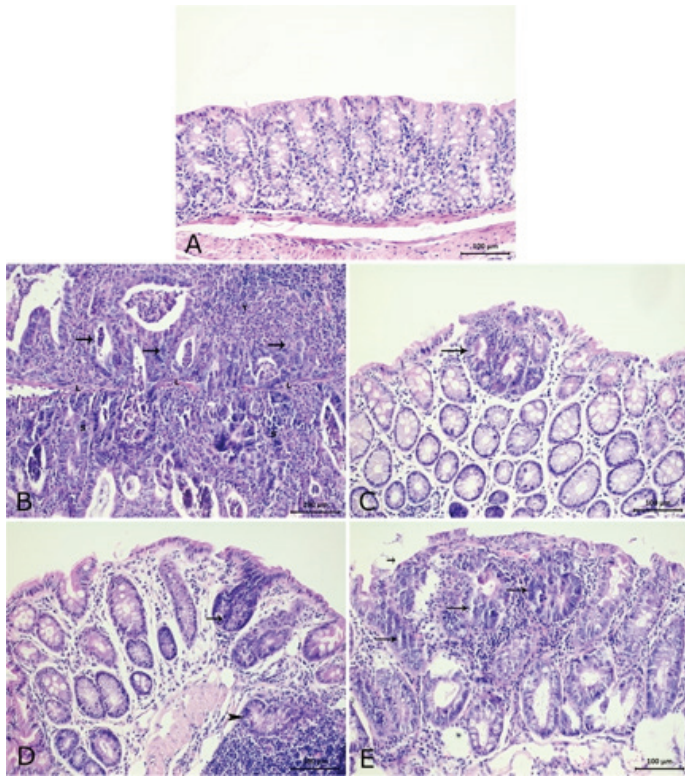


Figure 5. Histopathological staining (HE) of murine colon tissues. Bar=100 µm. A) Histologic view of normal colon in control group, B) Dysplastic glands (arrows) in DMH group with intensive mononuclear cell infiltration. C) Dysplastic glands in a restricted area (arrow) in BGS>DMH group. D) Dysplastic gland in propria mucosa (arrow) and a dysplastic gland within lymphoid hyperplasia (arrowhead) in DMH>BGS group. E) A large area of dysplastic glands (arrows) in DMH//BGS group.

For each group, a representative of histopathological stainings was given in Figure 5. In the control group, no acf were observed indicating a normal colon without any tumoral structure (Figure 5A). In acf developed colons a massive mononuclear cell infiltration and dysplastic glands were visible in DMH group (Figure 5B). The number of H-acf and D-acf tissues in DHM ve DMH>BGS groups were higher than particularly in BGS>DMH group followed by DMH//BGS group (Figure 5B-E). The lowest rate of tumor was noted in BGS>DMH group where BGS was given before tumor challenge. In addition, simultaneous administration of DMH and BGS to mice inhibited tumor formation and development more significantly than those in other groups (except for BGS>DMH group). BGS did not have a reversal effect on the tumor status once the tumor was already developed. However the number of H-acf and D-acf in lenfoid tissue were considerably higher in DMH and DHM>BGS groups with respect to BGS>DMH ve DMH//BGS groups.

Discussion and Conclusion

The most striking findings of this study were that BGS may

protect development of colon neoplasia consumed before tumor initiation. As stated that CC can be prevented and even curable with significantly lower morbidity and mortality if diagnosed in its early stage i.e. asymptomatic period^{22,25} supporting our results since timely intervention is crucial and highly promising for tumor prevention.

BGS formation is common in cattle at the of 7-8 years.²⁶ The qualitative chemical analysis of the gallstones obtained from slaughtered sheep (n=336) and cows (n=250) showed that calcium bilirubinate, cholesterol and calcium carbonate were present.²⁶ Even gallstone was observed in sheep fetuses. Sixteen Clun Forest and two Welsh Mountain fetuses of gestational age of 102-142 days with an incidence of 50% were earlier reported.¹⁴ However formed stones readily in the physiological conditions of uterine life disappear eventually within a ductal passage by physiological dissolution as seen in humans.²⁷ Calcium palmitate, which is the main constituent of the foetal gallstones in sheep, is also a constituent of human gallstones, and its incidence in these is about 36%.²⁸ In goats it was more frequent among adults despite the low prevalence (1.2%).²⁹

In human, gallstone disease occurs in over 10% of the adult population have been analysed by neutron activation, proton-induced X-ray emission and X-ray fluorescence. Calcium, phosphorus, sulphur, aluminium, manganese, copper and iodine were found at concentrations much higher than normal physiological levels. The distribution and form of calcium were examined qualitatively by SEM and infrared spectroscopy.³⁰

In our study, microstructural, chemical and mineralogical analysis of BGS showed that the structure was formed as amorphous over the time. That means, there is no evidence for ordered structure in BGS. Furthermore, porous structure was confirmed by microimages captured via SEM device. SEM/ EDX analysis highlighted BGS contained Ca, Na and S in a suitable chemical environment in the bile duct similar to previous reports.

Animals were well tolerated oral gavage of natural BGS in this study. No data were detected regarding the oral administration of BGS in mice so far. Thus this was the first report that the dose of 5 mg/kg can be used safely in BALB-c mice. However maximum tolerated dose of BGS has yet to be determined.

Chemical induction CC by DMH is one of the most commonly used method and is widely studied in in vivo experiments.³¹⁻³³ DMH with a high genotoxic effect is the choice

of CC in BALB-c mice.³⁴ Thus in our study murine was considered. In previous studies it was shown that colon neoplasia by DMH was achieved within 4.5 month³⁴ as observed in our study. DMH, which mutagenically acts by methylating DNA molecules, also disrupts RNA and therefore protein synthesis. DMH is converted to azoxymethane and azoxymethanol in the liver mimicking carcinogenic effects. The azoxymethanol is then conjugated to glucuronic acid and biliary excreted. In the colon lumen, glucuronoids are converted to active carcinogenic metabolites by bacterial hydrolysis and are associated with colon neoplasia.³⁵ It can be speculated that BGS may exhibit its effect by enhancing intestinal immune system, chelating cancerogens or covering intestinal lumen to protect absorption of carcinogen.

In our study, for the H-acf parameter, in DMH and DMH>BGS groups acf were mostly mild, while in BGS>DMH and DGS//DMH groups were all mild. For the D-acf parameter, DMH and BGS>DMH groups were highly mild, while the BGS//DMH group was highly moderate and it was highly severe in DHM>BGS group. The H-lf parameter was highly severe in the DMH group, slightly high in the BGS>DMH and DMH>BGS groups, and it was moderately high in the DMH group. When evaluated in terms of the sum of H-acf, D-acf, and H-lf parameters, both moderate and severe acf were not observed in the BSG>DMH group, and it was mostly mild.

The role of nanobacteria in pigment gallstone formation in Japanese white rabbits was experimentally validated. Nanobacteria were successfully cultured from cholecystolithiasis patient's gallbladder (without acute cholecystitis) bile samples and it was concluded that the nanobacteria exists in gallbladder bile of cholelithiasis patients and causes the formation of black pigmented gallstones in rabbits. Thus, an animal model of black pigment gallstones caused by nanobacteria was successfully established.³⁶ Moreover, Deng and Gao³⁷ managed to develop an artificial cow-bezoar as a substitute by mixing cattle bile, cholic acid, hydoxycholic acid, taurine, bilirubin and cholesterol to mimic natural cow-bezoar. However, their artificial preparation of cow-bezoar was cheaper than the natural form but less effective.³⁷

It was concluded that in this experimental colon tumor model the consumption of BGS was closely associated with a beneficial effect on colon tumors merely consumed before or during exposure to carcinogen but not subsequently resulting in a significant decrease in the incidence of colon tumors. Thus, the use of BGS for its antitumori-

genic effect appears to have some medicinal benefit rather than mystical controversy. The need for further analysis of whether BGS can be a candidate for the protection/treatment of colon tumors should be investigated in detail, etc. in vitro. Moreover, in the presence of chemically suitable medium and ions BGS-like substances can be artificially produced and their effects on colon tumors may be accordingly evaluated to observe maximum tolerated dose with minimum concerning with respect to natural counterparts.

References

1. Herstad KM, Gunnes G, Rørtveit R, et al. Immunohistochemical expression of β -catenin, Ki67, CD3 and CD18 in canine colorectal adenomas and adenocarcinomas. *BMC Vet Res.* 2021;17(1): 1-9.
2. Saito T, Nibe K, Chambers JK, et al. A histopathological study on spontaneous gastrointestinal epithelial tumors in dogs. *J Toxicol Pathol.* 2020;33(2): 105-113.
3. Holt PE, Kucke VM. Rectal neoplasia in the dog: A clinicopathological review of 32 cases. *Vet Rec.* 1985;116: 400.
4. Slawienski M. Malignant colonic neoplasia in cats: 46 cases. *J Am Vet Med Assoc.* 1997;211(7):878-881.
5. Brodsky E. Cancer of the small and large intestine. In: Bruyette DS, ed. *Clinical Small Animal Internal Medicine.*, John Wiley & Sons, Inc, 2020:1287-1292.
6. Cho SH, Seung BJ, Kim SH, et al. Overexpression and mutation of p53 exons 4–8 in canine intestinal adenocarcinoma. *J Comp Pathol.* 2020;175:79-84.
7. Erben V, Carr PR, Holleczeck B. et al. Dietary patterns and risk of advanced colorectal neoplasms: a large population based screening study in Germany. *Prevent Med.* 2018;111:101-109.
8. Bresalier RS, Kim YS. Malignant neoplasms of the large intestine. In: Feldman M, Friedman LS, Brandt LJ eds. *Sleisenger and Fordtran's Gastrointestinal and Liver Diseases.* 6th ed. vol 2., Philadelphia, USA: WB Saunders Company, 1998;1906-1942.
9. Perdue DG, Perkins C, Jackson-Thompson J. et al. Regional differences in colorectal cancer incidence, stage, and subsite among American Indians and Alaska Natives, 1999-2004. *Cancer.* 2008;113:1179-1190.
10. Tonooka T, Takiguchi N, Ikeda A. et al. Laparoscopic partial colectomy for transverse colon cancer after open laparotomy for gastric cancer resection. *Gan to Kagaku Ryoho Cancer Chemoth.* 2020;47(2):382-384.
11. Watanabe S, Kamei T, Tanaka K. et al. Roles of bile acid conjugates and phospholipids in in vitro activation of pancreatic lipase by bear bile and cattle bile. *J Ethnopharmacol.* 2009;125:203-226.

12. Feng Y, Siu K, Wang N. et al. Bear bile: dilemma of traditional medicinal use and animal protection. *J Ethnobiol Ethnomed.* 2009;5:2.
13. Chinese Pharmacopoeia Commission, Pharmacopoeia of the People's Republic of China: vol. 1, Chinese Medical Science and Technology Press, Beijing, 2010;A-27, 6:299, A-26.
14. Wood JR, France VM, Sutor DJ. Occurrence of gallstones in foetal sheep. *Lab Anim.* 1974;8(2):155-159.
15. Good LI, Edell SL, Soloway RD. et al. Ultrasonic properties of gallstones: Effect of stone size and composition. *Gastroenterology.* 1979;77(2):258-263.
16. Lamain G, Frisee V, Ramery E. et al. Successful reduction of cholelithiasis in a Holstein cow. *Cattle Pract.* 2012;20 (1):93-98.
17. Grigoreva IN, Romanova TI. Gallstone disease and microbiome. *Microorganisms.* 2020;8(6):835.
18. Jarrar BM, Al-Rowaily MA. Epidemiological aspects of scorpion stings in Al-Jouf province, Saudi Arabia. *Ann Saudi Med.* 2008;28(3):183-187.
19. Moore EW. Biliary calcium and gallstone formation. *Hepatology.* 1990;12(3): 206S-214S.
20. Still J. Use of animal products in traditional Chinese medicine: Environmental impact and health hazards. *Complement Ther Med.* 2003;11(2): 118-122.
21. Qiao X, Ye M, Pan DL, et al. Differentiation of various traditional Chinese medicines derived from animal bile and gallstone: simultaneous determination of bile acids by liquid chromatography coupled with triple quadrupole mass spectrometry. *J Chromatogr A.* 2011;1218(1):107-117.
22. Qian ZZ, Dan Y, Liu YZ, et al. Pharmacopoeia of the People's Republic of China (2010 edition): a milestone in development of China's healthcare. *Chinese Herb Med.* 2010;2(2):157-160.
23. Moolenbeek C, Ruitenber El. The 'Swiss Roll': A simple technique for histological studies of the rodent intestine. *Lab Anim.* 1981;15:57-59.
24. Sengottuvelan M, Viswanathan P, Nalini N. Chemopreventive effect of trans-resveratrol - A phytoalexin against colonic aberrant crypt foci and cell proliferation in 1,2-dimethylhydrazine induced colon carcinogenesis. *Carcinogenesis,* 2006;27 (5):1038-1046.
25. Min L, Zhu S, Chen L, et al. Evaluation of circulating small extracellular vesicles derived miRNAs as biomarkers of early colon cancer: a comparison with plasma total miRNAs. *J Extracell Vesic.* 2019;8(1):1643670.
26. Khaki Z. Gallstones in sheep and cows slaughtered at Tehran abattoirs. *J Vet Res.* 2005;60(4):401-403.
27. Dworken H. Recent experiences with spontaneously disappearing gallstones. *Gastroenterology.* 1960;38:76.
28. Sutor DJ, Wooley SE. A statistical survey of the composition of gallstones in eight countries. *Gut.* 1971;12:55.
29. Rahmani Shahraki AR, Namjoo A, Momtaz H. Prevalence and pathological findings of cholelithiasis in goats. *Iranian J Vet Med.* 2012;6(2):73-77.
30. Al-Kinani AT, Watt DE, East BW, et al. Minor and trace element analysis of gallstones. *Analyst.* 1984;109(3):365-368.
31. Oh BY, Hong HK, Lee WY, et al. Animal models of colorectal cancer with liver metastasis. *Cancer Lett.* 2017;387:114-120.
32. Deschner EE, Long FC. Colonic neoplasms in mice produced with six injections of 1,2-dimethylhydrazine. *Oncology.* 1977;34(6):255-257.
33. Ali MS, Hussein RM, Kandeil MA. The pro-oxidant, apoptotic and anti-angiogenic effects of selenium supplementation on colorectal tumors induced by 1,2-dimethylhydrazine in BALB/C mice. *Rep Biochem Mol Biol.* 2019;8(3):216.
34. Lei Q, Bi J, Chen H, et al. Glucagon-like peptide-2 improves intestinal immune function and diminishes bacterial translocation in a mouse model of parenteral nutrition. *Nutr Res.* 2018;49:56-66.
35. Venkatachalam K, Vinayagam R, Arokia Vijaya Anand M, et al. Biochemical and molecular aspects of 1, 2-dimethylhydrazine (DMH)-induced colon carcinogenesis: a review. *Toxicol Res.* 2020;9(1):2-18.
36. Wang L, Shen W, Wen J, et al. An animal model of black pigment gallstones caused by nanobacteria. *Digest Dis Sci.* 2006;51(6):1126-1132.
37. Deng ML, Gao SX. *Animal Drugs in China.* Jilin People's Press, Jilin. 1981;449.