



OLGU

Spontaneous resolution of a scar pregnancy after an unsuccessful dilatation and curettage procedure: A case report

Skar gebeliğinin başarısız dilatasyon ve kürtajdan sonra spontan rezolusyonu: Olgu sunumu

Ömer Demirtaş¹, Gülşah Demirtaş², Emre Gültekin², Bülent Yeşilyurt³

¹Pamukkale University, Faculty of Medicine Hospital, Department of Obstetrics and Gynecology, Denizli, Türkiye.

²Department of Obstetrics and Gynecology, Iğdır State Hospital, Iğdır, Turkey.

³Department of Radiology, Iğdır State Hospital, Iğdır, Turkey.

Abstract

Cesarean scar pregnancy (CSP) is the rarest kind but serious complication of ectopic pregnancy. We presented a 35 year-old woman gravida 4, para 3, with a prior history of cesarean section before 6 months ago was admitted to our department with minimal vaginal bleeding and pelvic pain. Ultrasonographic evaluation revealed a regular well-defined gestational sac (GS) located in the lower segment of anterior uterine wall, adjacent to the vesicouterine space, 12*16*11 mm in size (5week 6 day). The case was managed by dilatation and curettage but procedure was unsuccessful. Patient was followed up by expectant management. The hCG resolution time was 40-50 days. Normal uterin anatomy was achieved after 103 days without complications. About 6 months later the patient has conceived intrauterin pregnancy. CSP should be diagnosed and treated as soon as possible to reduce morbidity and preserve fertility. Expectant management can be performed for selected patients detected in early first trimester.

Keywords: Cesarean scar pregnancy, ectopic pregnancy, expectant treatment, evacuation treatment.

Introduction

Cesarean scar pregnancy is an ectopic pregnancy embedded in the myometrium of a previous cesarean scar, outside the uterine cavity. CSP is considered to be a rare form of ectopic pregnancy that may have serious complications affecting the woman's future fertility and may even affect her own life (1). Its incidence was reported between 1/1800 and 1/2200 pregnancies (2,3). However, incidence is increasing worldwide due to the rise in cesarean rates. The most possible mechanism is believed to develop as a result of the presence of a microscopic tract in the poorly healed uterine scar allowing the blastocyst to be implanted deep in the myometrium (4). Trauma from previous uterine surgeries like dilatation and curettage, myomectomy, metroplasty and caesarean section are considered to be the reasons. It is important to consider this possibility in patients with the above-mentioned risk factors. The outcome is dependent on early diagnosis and timely intervention. This is because early diagnosis with an ultrasound scan can offer treatment options. Early diagnosis of CSP pregnancy is essential to avoid catastrophic complication such as uterine rupture, severe, uncontrolled hemorrhage

Özet

Sezaryen skar gebeliği (SSG), ektopik gebeliğin çok nadir görülen ancak ciddi komplikasyon oluşturabilecek bir türüdür. 35 yaşında, gravida 4, parite 3 ve 6 ay önce geçirilmiş sezaryen öyküsü bulunan hasta, minimal vajinal kanama ve orta derecede pelvik ağrı şikayetleri ile hastanemize başvurdu. Ultrasonografik incelemede, uterus alt segment ön duvarına yerleşmiş, vezikouterin alana bitişik, düzgün sınırlı, 12*16*11 mm boyutlarında (5 hafta 6 günlük) gebelik kesesi izlendi. Olguya dilatasyon küretaj uygulandı ancak prosedür başarısız oldu. Sonrasında hasta izlem tedavisine alındı. HCG rezolusyon zamanı 40-50 gün idi. Normal uterin anatomiye, komplikasyon olmadan 103 gün sonra ulaşıldı. 6 ay sonra hasta tekrar normal intrauterin gebelik sahibi oldu. SSG'de, morbiditeyi azaltmak ve fertilitiyi korumak için olabildiğince erken tanı konulmalıdır. İlk trimesterde, erken haftalarda tespit edilen seçilmiş vakalarda, izlem tedavisi seçenek olabilir.

Anahtar Kelimeler: Sezaryen skar gebeliği, ektopik gebelik, izlem tedavisi, aspirasyon tedavisi.

which may require hysterectomy and result in subsequent loss of fertility. It constitutes a life-threatening condition if is not diagnosed and treated early (5). Diagnosis is based on high level of suspicion when a gestational sac is seen at sonography on the anterior lower part of the uterus in a woman with a previous Cesarean section. When the gestational sac is seen in the lower part of the uterine cavity, it can be difficult to differentiate from spontaneous abortion and cervico-isthmical pregnancy. It is essential to get a proper history and a high resolution ultrasound scanning in order to avoid wrong diagnosis (3). In this study, we report the difficulties in early diagnosis and the therapeutic challenges.

Case

35-year-old woman, gravida 4, para 3 was admitted to hospital with mild vaginal bleeding for the last 10 days, moderate pelvic pain and menstrual delay. The patient's obstetric history included three cesarean sections, the last one was 6 months ago. Physical examination demonstrated stable vital signs and bimanual examination revealed a slightly enlarged and slightly tender uterus on movement with no adnexal masses.

Yazışma Adresi/Corresponding: Ömer Demirtaş
Department of Obstetrics and Gynecology, Pamukkale University Faculty of Medicine Hospital,
Denizli, Turkey.
Tel: +90 505 765 66 51
E-mail: -

Müracaat tarihi: 02.07.2013
Kabul tarihi: 20.01.2014

The cervical canal was closed. Transvaginal ultrasonography (USG) revealed an ectopic pregnancy with a 12*16*11 mm situated in the lower part of the anterior uterine wall at the site of the cesarean section scar with no fetal parts (Figure 1).

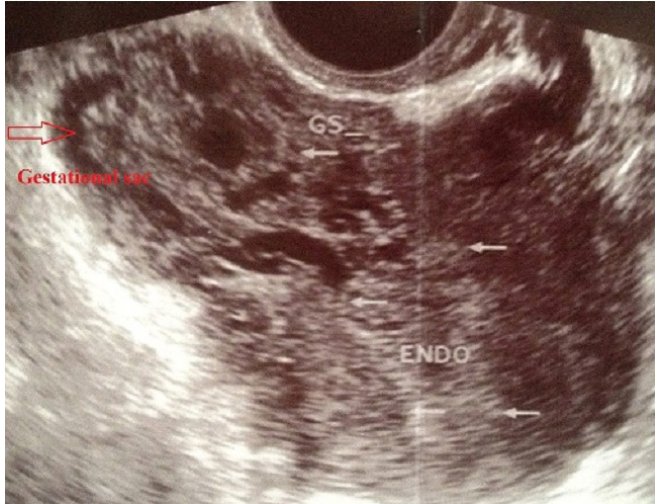

Figure 1. Endovaginal ultrasonography. Ectopic gestational sac was seen in the lower part of the anterior uterine wall at the site of the cesarean section scar with no fetal parts and yolk sac. Endometrial cavity is empty. Red arrow shows GS: gestational sac. Endo: Endometrium.

Magnetic resonans imaging (MRI) axial and coronal section image showed an empty uterin cavity, cervical canal and gestational ectopic sac positioned laterally to cavity (Figure 2).

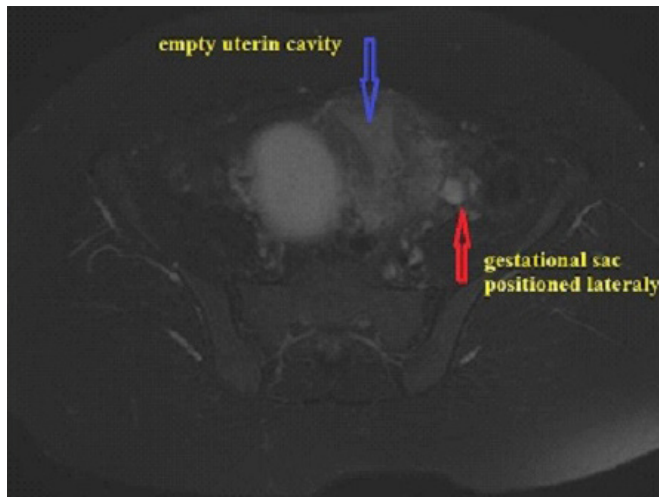


Figure 2. T2A-Axial and sagittal MRI Images. Empty endometrial cavity and cervical canal. Blue arrow shows empty endometrial cavity and red arrow shows gestational sac positioned anterolaterally.

Both transabdominal and transvaginal USG revealed a CSP according to the Jurkovic criteria (2). No normal myometrium was visualized between the bladder and the gestational sac; only 4,76 mm thickness of myometrium separated the sac from the urinary bladder. No fluid was seen in the pelvic cavity. The serum beta-human chorionic gonadotrophin (b β -hCG) level was 7857 IU/mL. Therapeutic options

(including suction evacuation, and medical therapy) were offered to mother. She preferred to go for surgical intervention. In our patient, evacuation was performed 2 days after the diagnosis. There was no massive uterine bleeding after dilatation and curettage (D&C). β -hCG level was 6717 after D&C. 10 days after the evacuation, the β -hCG level was 3204 IU/L. USG and MRI coronal section images revealed persistant gestational sac measuring 5,7 * 4,8 cm and hematometra (Figure 3).

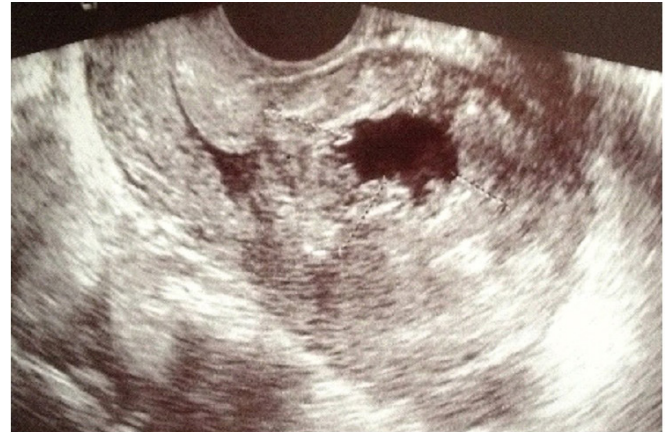

Figure 3. Transvaginal ultrasonography 1 week after curettage. Persistent ectopic gestational sac was still present in the lower part of the anterior uterine wall at the site of the cesarean section scar. Irregularity of the inner wall of the ectopic gestational sac was detected.

Histopathological examination of the removed tissue revealed degenerated endometrial glands and stroma with blood clots. After D&C, the patient's hemodynamic status was normal, fetal node was absent, gestational age was early, inner wall of gestational sac was irregular, and there was minimal vaginal bleeding so we decided to follow up the patient. Pain was relieved after 1 week and vaginal bleeding was delayed up to 1 months. The β -hCG resolution time was 40-50 days. Normal uterin anatomy was achieved after 103 days. There was no need for additional interventions and therapy. Spontan resolution was occurred. About 6 months later the patient has conceived normal intrauterine pregnancy.

Discussion

CSP is an ectopic pregnancy that completely surrounded by the myometrium and the fibrous tissue of the scar. Endometrial cavity is empty. CSP should be diagnosed as early as possible in order to avoid severe complications and provide conservative treatment. It's important to differentiate between cervical pregnancy and spontan abortus in progress when the gestational sac was seen at the lower segment of uterus. High index of suspicion is essential for patients with the history of cesarean, D&C, myomectomy. Suspicious findings should be evaluated with the USG for CSP. Proposed ultrasound diagnostic criterias, allowing a differential diagnosis with cervical ectopic pregnancy are:

- A gestational sac located between the bladder wall and the fibrous tissue of the scar. Sac is completely surrounded

by the myometrium.

- Empty uterine cavity and cervical canal. Internal cervical canal is closed.
- Clearly visible circular blood flow surrounding the sac characterized by high-velocity (peak velocity >20 cm/s) and low-impedance (pulsatility index <1).
- Negative 'sliding organs sign', defined as the inability to displace the gestational sac from its position at the level of the internal os using gentle pressure applied by the transvaginal probe (2,3,6,7).

In our case, circular blood flow surrounding the sac was detected with transvaginal ultrasonographic doppler, so the diagnosis of spontan abortus in progress was excluded. To provide a 'panoramic view' of the uterus and obtain additional information on the thickness of the myometrium between the bladder and the gestational sac, we performed an abdominal USG. We didn't try to verify 'sliding organ sign because this might provoke vaginal bleeding and even rupture in rare situations of a prerrupture myometrium (8). Some authors recommend MRI simultaneously with vaginal doppler sonography as an additional diagnostic tool (9). But some authors don't recommend MRI because sonography combined with Doppler flow imaging are adequate for diagnosing (8,10). We performed MRI to determine the treatment option. We detected the distance between the bladder and myometrium with USG and MRI. The shortest distance was 4,76 mm. We didn't perform cystoscopy because there was no invasion sign to the bladder, the pregnancy was 5-6 weeks and fetal node was absent. Two different types of CSP were proposed by Vial et al. (7). In the first case, continuous connection to the cavum uteri was present. Pregnancy progresses towards the uterine cavity so expectant management selected. In the second case, deep placental attachment in the lower segment to decidua basalis and myometrial tissue progresses towards rupture and creates a risk for dangerous bleeding. Treatment methods vary according to gestational weeks, symptoms and clinical experience (11). Most of the publications recommend the termination of such pregnancies when the correct diagnosis was made (8,12). The patient's hemodynamic stability, fetal cardiac activity, gestational age, severity of vaginal bleeding, β -hCG level and the desire future fertility must be considered. Some authors reported an uneventful outcome with expectant management of missed abortion at 6 and 8 weeks (2,8). In our case, pregnancy was 5-6 weeks, fetal node was absent and inner wall of gestational sac was irregular. So we decided to follow up the patient. Post-treatment evaluation is important for expactant management. We planned outpatient follow-up with weekly measurement of β -hCG until they are undetectable similar to Jurkovic and Maymon's cases (2,8). Ultrasound examination was made to evaluate the size of the retained products monthly. According to our experience, the hCG resolution time was 40-50 days. Our findings were similar with Seow and Jurkovic et al.'s reports with a range of 21–188 days for serum β -hCG to reach undetectable levels with MTX treatment (2,3). Rahvon et al. reported that

complete clearance of the serum β hCG takes 9 weeks and complete disappearance of the gestational sac leads 3 months (13). Similar to those reports, we achieved normal uterin anatomy after 103 days (figure 4).

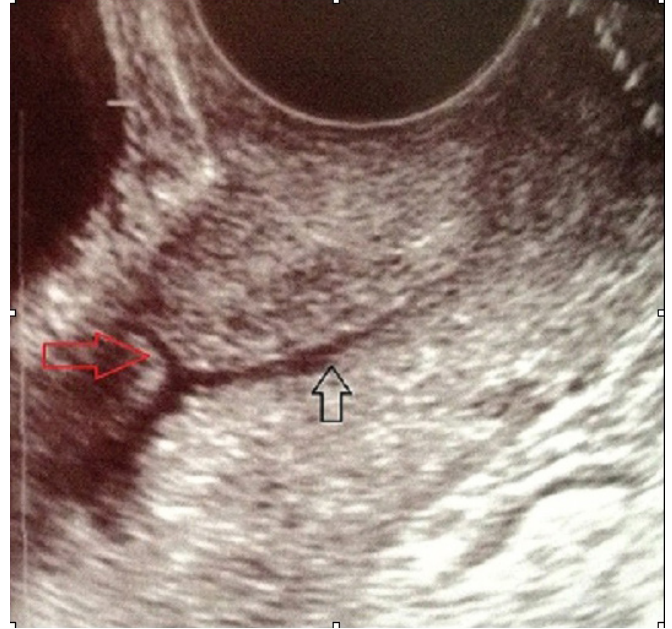


Figure 4. Transvaginal ultrasonography; normal uterin anatomy was received 103 days after spontan resolution of ectopic scar pregnancy. Red arrow shows scar line. Black arrow shows cervical canal.

Conclusion

In conclusion, because of the rarity of these cases, the management of CSP is not well established and it is impossible to draw any firm conclusion as to the predisposing factors. At the moment, no universal treatment guidelines have been established to date. So all scar pregnancies should be reported so that more data may be obtained for indications, contra-indications, efficacy and the safety of the different management modalities. Conservative treatment for the early pregnancy may be considered, probably before 7 weeks of gestation. Treatment policy should be tailored to each patient and take into consideration the viability of the pregnancy and the gestational age as well as future family planning. So it is important to know and keep in mind the radiological criteria of CSP. Development of diagnostic methods and early diagnosis of CSP by the radiologists alter the clinical outcome for the patient.

References

1. Kurt S, Uyar İ, Gürbüz T, Arıcı A, Demirtaş Ö, Taşyurt A. Sistemik Metotreksat Sonrası Vakum Küretajla Tedavi Edilen Sezaryen Skar Gebeliği: 2 Olgu Sunumu(Treatment of Cesarean Scar Pregnancy with Vacuum Curettage After Systemic Methotrexate Administration: Report of Two Cases). *Turkiye Klinikleri J Gynecol Obst* 2013; 23(2):123-126.
2. Jurkovic D, Hillaby K, Woelfer B, Lawrence A, Salim R, Elson C. First trimester diagnosis and management of pregnancies implanted into the lower uterine segment cesarean section scar. *Ultrasound Obstet Gynecol* 2003; 21: 220–227.

3. Seow K, Huang L, Lin Y, Yan-Sheng Lin M, Tsai Y. Cesarean scar pregnancy: issues in management. *Ultrasound Obstet Gynecol* 2004; 23: 247–253.
4. Adel AN, Lama O, Manal W, Tahrir A, Mariam A. Ectopic intramural pregnancy developing at the site of a cesarean section scar: a case report. *Cases Journal* 2009; 2: 9404
5. Donald F. Ectopic pregnancy within a cesarean scar: a review. *Obstet Gynecol Surv* 2002; 57: 537–543.
6. Sugawara J, Senoo M, Chisaka H, Yaegashi N, Okamura K. Successful conservative treatment of a cesarean scar pregnancy with uterine artery embolization. *Tohoku J Exp Med* 2005; 206: 261-265.
7. Vial Y, Petignat P, Hohlfeld P. Pregnancy in a cesarean scar. *Ultrasound Obstet Gynecol* 2000; 16: 592-593.
8. Maymon R, Halperin R, Mendlovic S, Schneider D, Herman A. Ectopic pregnancies in a caesarean scar: review of the medical approach to an iatrogenic complication. *Hum Reprod Update* 2004; 10: 515-523.
9. Shufaro Y, Nadjari M. Implantation of a gestational sac in a cesarean section scar. *Fertil Steril* 2001; 75: 1217.
10. Nawroth F, Foth D, Wilhelm L, Schmidt T, Warm M, Romer T. Conservative treatment of ectopic pregnancy in a cesarean section scar with methotrexate: a case report. *Eur J Obstet Gynecol* 2001; 99: 135–137.
11. Aksüt H, Yılmaz B, Mavi Ş, Soylu F, Yalçın Y. Koitus sonrası akut abdomen ile başvuran sezaryen skar gebeliği (Cesarean scar pregnancy presenting with acute abdomen after coitus). *Pam Tıp Derg* 2013;6(3):150-152.
12. Roberts H, Kohlenber C, Lanzarone V, Murray H. Ectopic pregnancy in lower segment uterine scar. *Aust N Z J Obstet Gynaecol* 1998; 38: 114-116.
13. Ravhon A, Ben-Chetrit A, Rabinowitz R, Neuman M, Beller U. Successful methotrexate treatment of a viable pregnancy within a thin uterine scar. *Br J Obstet Gynecol* 1997; 104: 628–629.