



## OLGU

### Large Sialolith Of The Submandibular Gland: Report Of A Case And Comparison Of Sialolithotomy vs Sialoadenectomy

#### Submandibuler Bezde Büyük Tükürük Bezi Taşı: Olgu Sunumu ve Sialolitotomi ile Sialoadenektominin Karşılaştırılması

Poyzan Bozkurt<sup>1</sup>, Mehmet Eray Kolsuz<sup>2</sup>, Erdal Erdem<sup>1</sup>

<sup>1</sup>Ankara University Faculty of Dentistry, Department of Oral and Maxillofacial Surgery, Ankara, Türkiye.

<sup>2</sup>Ankara University Faculty of Dentistry, Department of Oral Diagnosis and Radiology, Ankara, Türkiye.

#### Abstract

In this report we present a patient with a large sialolith of the submandibular gland and its treatment by sialolithotomy. Sialoadenectomy vs. sialolithotomy for treatment of large submandibular gland calculi has been discussed.

A 49 year-old male administered to our clinic with an ultrasonography report specifying submandibular gland calculi. An orthopantomograph was obtained and a large radio opaque lesion was detected just below the left mandibular border, in alignment with the second molar tooth. Computerized tomography examination was made and the calculus was designated to be in the posterior part of the gland. The sialolith was removed under general anesthesia, sialoadenectomy was not performed. At 3 months, 6 months and 1-year follow-up patient did not have any complaints.

We are in the opinion that sialolithotomy should be preferred primarily for large submandibular sialoliths and sialoadenectomy should be considered only if symptoms occur.

**Keywords:** Sialolith, Submandibular Gland, Sialoadenectomy, Sialolithotomy.

#### Introduction

Sialolithiasis is the most common disease affecting adult salivary glands, accounting for more than 50% of all salivary gland pathologies (1). Males are affected more than females. The origin of this condition is believed to be related to the deposition of calcium around bacteria, epithelial cells of the duct, or foreign bodies (2). As in our case the most common location is the submandibular gland. There are two sharp edges in the submandibular duct, the first is around the posterior edge of the mylohyoid muscle and the second is before the duct joins to the oral cavity. These particular areas are therefore prone to salivary stone formation. Clinical symptoms include intermittent swelling, tenderness of the salivary gland, and altered salivary flow from the ductal orifice (3) or can be asymptomatic as in our case. Most of the salivary sialoliths are small in size, usually less than 1 cm in diameter. Sialoliths bigger than 1 cm are reported as megaliths or giant calculi in

#### Özet

Bu olgu sunumunda submandibular bezinde büyük bir sialolit bulunan hastanın sialolitotomi ile tedavisini sunuyoruz. Büyük submandibular bez sialolitlerinin tedavisinde sialoadenektomi ve sialolitotomi tedavileri tartışılmıştır.

49 yaşında erkek hasta mandibular bez taşı olduğunu belirten ultrasonografi raporu ile kliniğimize başvurdu. Alınan ortopantomografa sol mandibula alt kenarında ikinci molar diş hizasında radyopak lezyon teşhis edildi. Yapılan kompüterize tomografi incelemesinde taşın bezin posterior kısmında lokalize olduğu görüldü. Sialolitotomi genel anestezi altında yapıldı fakat sialoadenektomi uygulanmadı. 3 ay, 6 ay ve 1 yıl takiplerinde herhangi bir komplikasyona rastlanmadı.

Büyük submandibular bez sialolitlerinin tedavisinde sialolitotominin birincil tedavi seçeneği olması gerektiği, sialoadenektominin semptomların devam etmesi durumunda gündeme getirilmesi gerektiği görüşündeyiz.

**Anahtar Kelimeler:** Sialolit, Submandibular Bez, Sialoadenektomi, Sialolitotomi.

the literature (4). A salivary calculus arises and enlarges by continuous deposition at a rate of approximately 1 to 1.5 mm per year, and it could be anticipated that it could take at least 10 years to obtain a stone classified as megalith.

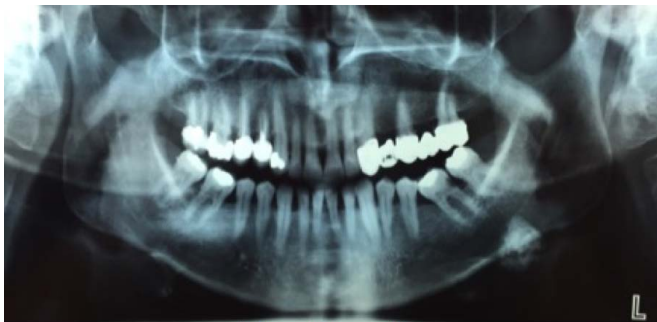Diagnosis is usually made with orthopantomographs and occlusal radiographs. Computerized tomography (CT), sialography, ultrasonography, and sialoendoscopy are also commonly used. Ultrasonography is widely used because it is the least invasive and cheapest method and 90% of stones larger than 2 mm in diameter can be detected as echo dense spots. Ultrasonography was also used in our case for initial diagnosis. Sialography has been introduced as a minimally invasive intervention for the diagnosis of salivary ductal diseases by injecting radiopaque dye into salivary duct; orifice sialography can display radiolucent calculi as filling defects. Application of sialography is restricted and contraindicated in acute infectious manifestations. 3D-CT, with slice thicknesses

of 0.2 to 0.5 mm, can successfully display small or semi-calcified calculi. 3D-CT also displays anatomic details of the gland and the duct. Additionally precise localization of the calculi can be achieved and surgical planning can be performed accurately according to the revealed CT data. MRI is a valuable additional diagnostic method in complicated cases, or when further soft tissue diagnosis is essential. Nevertheless it is not generally used because of its cost.

When located in the duct orifice, smaller sialoliths can be removed by gland massage. Larger sialoliths can be removed via intraoral approach, extra oral approach, or an endoscopic approach, depending on the location, shape, and size of the calculus as well as the experience of the surgeon (2). The ones located in the posterior region of the duct or within the gland may require total gland removal.

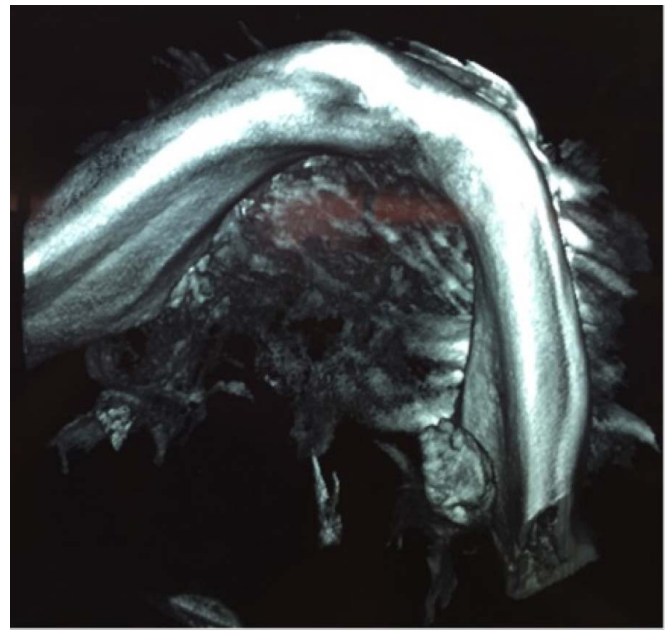
### Case Report

49-year-old male patient with no systemic diseases administered to our clinic. Patient provided an ultrasonography report from another center specifying submandibular gland calculi. An orthopantomograph was obtained from the patient. During radiological examination a large radio opaque lesion was detected on the orthopantomograph just below the left mandibular border, in alignment with the second molar tooth (Figure-1). Computerized tomography (CT) examination

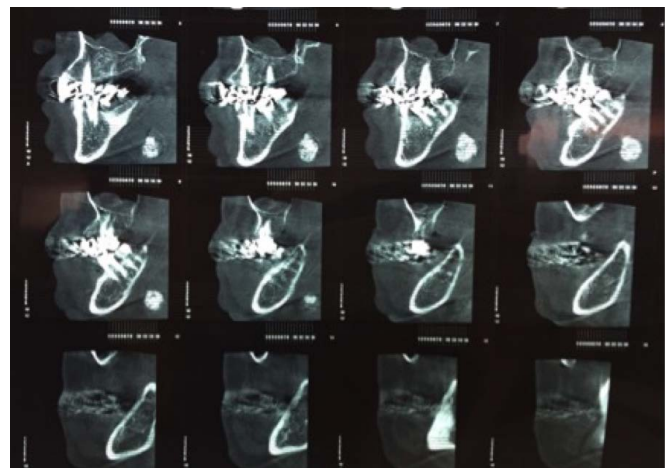


**Figure 1.** Panoramic radiograph of the patient.

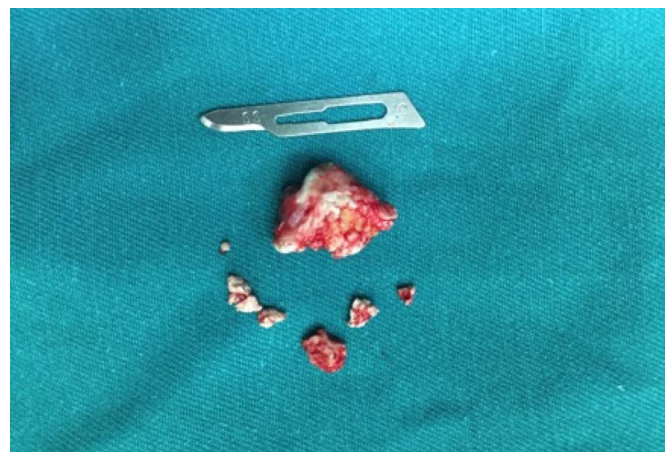was made to detect the exact location of the sialolith before surgery (Figure-2,3). According to CT findings calculi was designated to be in the posterior part of the gland. Patient was informed thoroughly about treatment options. Surgery under general anesthesia was planned. After 6 hours of fasting patient was taken to the operating room, nasal intubation was used for anesthesia in order to maintain a better view of the surgical site. The sialolith was palpated bilaterally from below the mandibular corpus and under the tongue. The trace of the stone was intraorally observed. Mucosal incision was made along the trace of the sialolith while the tongue was being retracted to the opposite side and the sialolith was being pushed upwards. Submucosal and submandibular gland tissues were dissected to maintain access to the sialolith. Lingual nerve was seen during the dissection and dissection movement was made parallel to the lingual nerve to preserve it. The sialolith was then again pushed upwards and anteriorly from below the mandibular and the stone was removed using a curved elevator from the posterior of the large sialolith in



**Figure 2.** 3D computerized tomography view.



**Figure 3.** Sagittal views from computed tomography scans.



**Figure 4.** Macroscopic view of the sialolith.

order to not push it into the deep tissues. The removed sialolith was hard in texture, porous and yellow (Figure-4).

Once the large sialolith was out irrigation was made with physiological serum in order to remove any remnants of the sialolith from the submandibular space, furthermore lingual nerve was once again checked for interruptions. A plastic catheter was inserted to the cavity and stabilized using a 3.0 vicryl thread in order to drain any bleeding from the submandibular space. Incision was then primarily sutured again using a 3.0 vicryl thread. Submandibular tissues were not sutured in order to provide drainage. Patient was extubated and sent to service. Amoxicillin 1gr twice a day, 25mg of dexketoprofen trometamol three times a day and use of mouthwash containing benzydamine hydrochloride three times a day was prescribed, and patient was discharged. Drain was removed on the second postoperative day and patient had no complaints. At 3 months, 6 months and 1-year follow-up the patient did not have any complaints. Radiological examinations revealed no new calculi formation.

### Discussion

Submandibular gland excision is recommended in cases of substantial intra-glandular silaloliths, which are inaccessible via a trans-oral approach. Also, when multiple small stones are present in the vertical and comma portions of Wharton's duct, sialoadenectomy is recommended (1). Excision of the gland is reported to carry a risk of up to 8% for temporary or permanent marginal mandibular nerve palsy (5). Nevertheless Dag et al. (6) concluded that epidermal growth factor deficiency achieved by sialoadenectomy caused ultrastructural changes in gingival epithelium.

Our patient at 1-year follow-up had no complaints. This raises doubts on the common knowledge that this type of calculus leads to chronic sialoadenitis, which is the main reason for sialoadenectomy procedure. In contrary with our case Jung et al. (7) reported a case of sialolith in the submandibular gland parenchyma, with a similar size of 14x10mm, which they treated with sialoadenectomy. Liu et al. (3) reported a research of 90 patients (78 submandibular glands and 12 parotid glands) with sialoliths who underwent sialolithotomy using a semi-rigid endoscope (endoscopy alone or endoscopy assisted surgery). Only one patient developed postoperative complications and required sialoadenectomy. Walvekar et al. (8) reported a study on 30 patients who underwent endoscopic sialolith removal. As in our study none of the patients developed any complications and required sialoadenectomy. In contrast to our case Markou et al. (9) reported a case of sialolith removal from the submandibular gland, which was concluded with a giant submandibular gland mucocele. The cyst was surgically excised and the specimen included the sublingual gland, in order to prevent recurrence.

### Conclusion

Excision of the gland for sialolith treatment carries risks of temporary or permanent marginal mandibular nerve palsy and the absence of the submandibular gland causes ultrastructural changes in gingival epithelium. Primary treatment option

for well-palpated and distally located stones should be sialolithotomy. Sialoadenectomy should be considered if symptoms occur.

### References

1. Fowell C, MacBean A. Giant salivary calculi of the submandibular gland. *Journal of Surgical Case Reports* 2012; 9:6.
2. Santos TS, Araujo FAC, Frota R, Caubi AF, EDO Silva; Intraoral Approach for Removal of Large Sialolith in Submandibular Gland. *J Craniofac Surg* 2012; 23:1845-1847.
3. Liu DG, Zhang ZY, Zhang Y, Zhang L, Yu GY. Diagnosis and management of sialolithiasis with a semirigid endoscope. *Oral Surg Oral Med Oral Pathol Oral Radiol Endod* 2009; 108:9-14.
4. Graziani F, Vano M, Cei S, Tartaro GP, Mario G. Unusual Asymptomatic Giant Sialolith of the Submandibular Gland: A Clinical Report, *The Journal of Craniofacial Surgery* 2006; 17(3):549-552.
5. Wallace E, Tausin M, Hagan I. et al; Management of giant sialoliths: Review of the literature and preliminary experience with interventional sialendoscopy. *Laryngoscope* 2010;120(10):1974-1978.
6. Dag A, Ketani MA, Zengingul AI, Ketani S. The effects of Sialoadenectomy and Epidermal Growth Factor on Gingival Tissues in Rats: An ultrastructural Study 2008; 22:1002-1004.
7. Jung JH, Hong SO, Noh K, Lee DW; A Large Sialolith on the Parenchyma of the Submandibular Gland: A case report. *Experimental and Therapeutic Medicine* 2014; 8:525-526
8. Walvekar RR, Carrau RL, Schaitkin B. Endoscopic sialolith removal: orientation and shape as predictors of success. *American Journal of Otolaryngology-Head and Neck Medicine and Surgery* 2009; 30:153-156.
9. Markou K, Dova S, Krommydas A, Psillas G, Blioskas S, Karkos PD. Giant submandibular gland mucocele as a complication of previous sialolith removal. *Am J Otolaryngol* 2015;36(1):114-116.