

Increased intraocular pressure as an initial presentation of normal-pressure hydrocephalus

Yavuz Bardak*, Osman Çekiç*, Handan Bardak**,
Memduh Kerman***, Aykut Arslan Yıldız*

*Department of Ophthalmology, Süleyman Demirel University, Medical School, Isparta

**Division of Ophthalmology, State Hospital, Isparta

***Division of Neurosurgery, State Hospital, Isparta

Özet

Normal basınçlı hidrosefali olgusunda göziçi basınç artışı

67 yaşında bayan hasta baş ağrısı, görme azlığı ve göziçi basınç artışı ile kliniğimize başvurdu. Hastaya primer açık açılı glokom tanısı koyuldu. Nörolojik durumunun kötüleşmesi üzerine hasta 2 yıl sonra normal basınçlı hidrosefali nedeniyle ventrikülo-peritoneal şant operasyonuna alındı. Ameliyattan sonra olgunun hem nörolojik durumunun iyileştiği hem de yükselmiş olan göziçi basınç artışının normale döndüğü saptandı. Bu iki klinik durum arasındaki bağlantı ve ilişki benzer klinik durumlar düşünülerek göz önünde bulundurulmalıdır.

Anahtar kelimeler: Artmış göziçi basıncı, normal basınçlı hidrosefali

Abstract

A 67-year-old woman presented with headache, visual disturbance and increased intraocular pressure to the clinic. As her neurological state deteriorated gradually, she had underwent ventriculo-peritoneal shunt operation due to normal-pressure hydrocephalus 2 years later. Following the operation the patient's neurological symptoms improved and high intraocular pressures turned to normal. Possible coexistence and association of these two clinical situations should be taken into consideration for similar patients.

Key words: Increased intraocular pressure, normal-pressure hydrocephalus.

Introduction

Normal-pressure hydrocephalus (NPH) first described in 1965 by Hakim et al.(1), refers to a clinical entity consisting of the triad of gait disturbance, dementia, and incontinence, coupled with the laboratory findings of normal cerebrospinal fluid pressures and radiographic findings of ventriculomegaly (2-4). Glaucoma is a chronic disease characterised with retinal ganglion cell damage in which high intraocular pressure (IOP) may be the most important risk factor. As a result, visual field defects are revealed. We describe an adult case of NPH who presented with bilateral increased IOP. Intraocular pressure elevation may be related with NPH. There are physiological and pathological evidences which support the hypothesis of relationship between NPH, glaucoma

and Alzheimer disease (AD) (5). In our case, we observed a spectacular result such as IOP normalized following ventriculo-peritoneal shunt operation.

Case Report

A 67-year-old woman attended to the clinic with a 6-month history of headache and disturbance of vision in March 2002. She was known to be hypertensive for the last 20 years and was taking Varsaltan + Hydrochlorotiazide (CoDiovan®). Her past medical history revealed a total abdominal hysterectomy 10 years before. On ocular examination, her best-corrected visual acuity was 10/10 in the right eye and 9/10 in the left eye (Snellen Chart), with IOP of 23 mm Hg in the right eye and 24 mm Hg in the left eye (Goldman Applanation Tonometry). Diurnal variation measurements of IOP were in the range of between 23-26 mmHg. She had mild posterior subcapsular cataract in both eyes. Gonioscopy showed bilateral open iridocorneal angles. Fundoscopy of

Yazışma Adresi: Yavuz Bardak MD,
Chairman Department of Ophthalmology, Süleyman Demirel
University, Medical School, Çünür, Isparta, 32260 Turkey
Tel: +90-532 2415842
E-Mail: yavuzbardak@hotmail.com-yavuzbardak@med.sdu.edu.tr

both eyes disclosed mild hypertensive retinopathy and suspected glaucomatous cupping of the disc. The reliable serial visual field tests with automated perimetry revealed visual field defects on grey scale and global indices were consistent with glaucoma suspect, and a diagnosis of primary open angle glaucoma was made (Fig. 1, A and B). Central corneal thickness was 534 μm in both eyes. Topical timolol maleate 0.5% (Timoptic®) two times a day was started, and IOP decreased to 15 mmHg in both the eyes. Upon lack of improvement of headache as well as gradual appearance of proximal muscle weakness in extremities, she was referred to a neurologist 3 months later after initial presentation. Within a year, her mental state deteriorated rapidly, and the patient became entirely dependent. Frequent falls and urinary incontinence were also reported by her family. In June 2004, cranial magnetic resonance scan (Fig. 2) showed NPH; Normal lumbar puncture opening pressure and transient clinical improvement of neurologic symptoms on drainage of cerebrospinal fluid confirmed the diagnosis. Complete blood count, glucose, electrolytes, liver functions, renal functions, thyroid functions, vitamin B12, folate, chest radiograph, standard electrocardiogram and cardiac enzymes were found to be all normal.

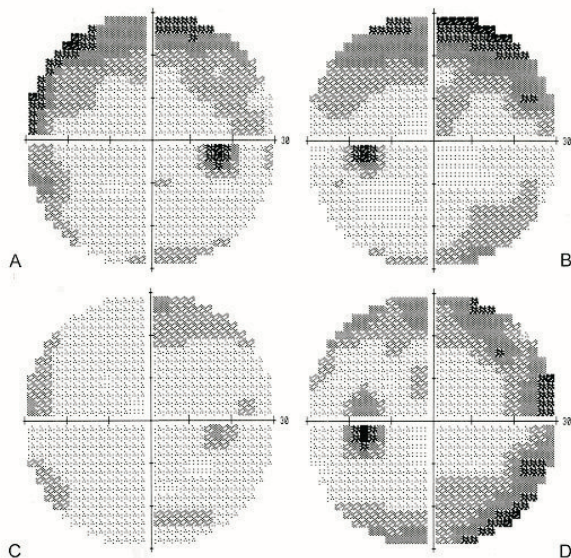


Fig. 1. (A and B) Baseline central 30-2 threshold test results of the right and the left eye. (C and D) Central 30-2 threshold test results of the right and the left eye at the last follow-up.

A ventriculo-peritoneal shunt operation was performed in January 2005. Dementia, gait disturbance, incontinence, headache, arterial hypertension as well

as IOP improved within 10 days following the operation. Five months after discharge, in June 2005, she was independently mobile and had no further drops and urinary incontinence. Best-corrected visual acuity was 9/10 in the right and 7/10 in the left eye. Slight progression of posterior subcapsular cataract was noted bilaterally. IOP was 17 mm Hg in both eyes without any glaucoma medication. Bilateral visual field defects were found to be improved comparing to baseline (Fig. 1, C and D).

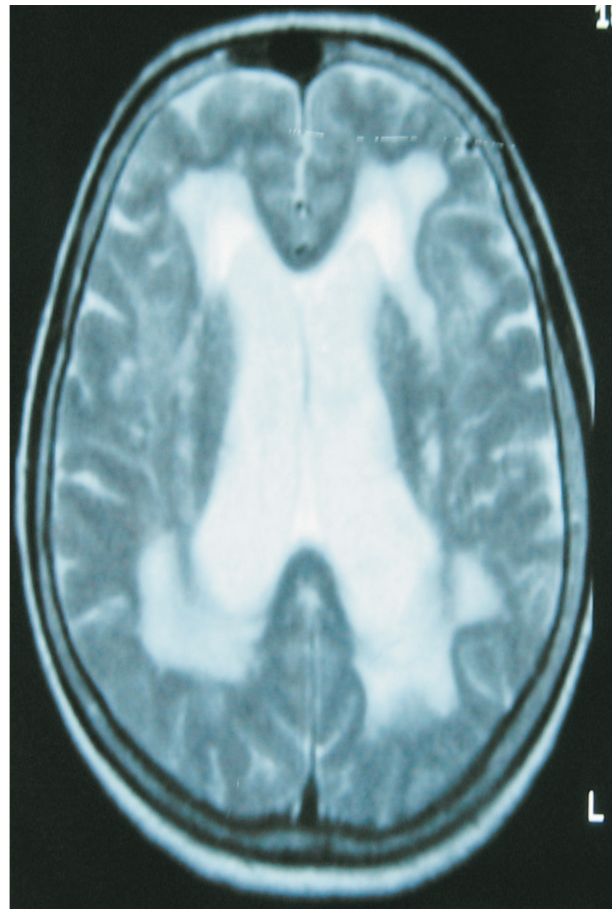


Fig.2. Cranial magnetic resonance scan of the patient.

Discussion

Normal pressure hydrocephalus differs from other causes of adult hydrocephalus. An increased subarachnoid space volume does not accompany increased ventricular volume (2). Clinical symptoms result from distortion of the central portion of the corona radiata by the distended ventricles. This includes the sacral motor fibers that innervate the legs and the bladder, thus explaining the abnormal gait and incontinence. Dementia results from distortion of the periventricular limbic system (3,4).

Glaucoma is a neurodegenerative disease characterised by a slow, progressive degeneration of retinal ganglion cells and their axons. Increased IOP is the most important risk factor for glaucoma. Association of hydrocephalus with congenital glaucoma has been reported (6), however, glaucoma due to NPH in elderly is unknown. In our patient, increased IOP was the initial presentation. Pronounced improvement of glaucoma after insertion of a shunt suggests that hydrocephalus might be the reason for her elevated IOP and visual field changes. As it's known IOP is the most important risk factor for glaucoma. Recently, similarities in pathophysiology between glaucoma and AD have been noted, with increased processing of amyloid precursor protein and up-regulation of β -amyloid protein expression in retinal ganglion cells. Given this link between AD and glaucoma, evidence for a causal relationship between repetitive intermittent intracranial pressure elevations and AD is gained from research indicating that high resistance wind instrument playing raises IOP and may result in glaucomatous damage (5).

Also there's a relationship between AD and NPH. In both NPH and AD, an important decrease in cerebrospinal fluid production was calculated. The resulting cerebrospinal fluid stagnation with impaired clearance and accumulation of neurotoxic substances may play an important role in the onset and progression of AD (5). They tested the hypothesis that improving cerebrospinal fluid turnover by means of an investigational low-flow ventriculoperitoneal shunt will delay the progression of dementia in patients with AD (5). In our case, we observed spectacular IOP recovery after undergoing ventriculoperitoneal shunt operation. Glaucoma, NPH and AD seems to be related with each other. Possible coexistence or association of these two clinical situations should be taken into consideration for similar patients.

References

1. Hakim S, Adams RD. The special clinical problem of symptomatic hydrocephalus with normal cerebrospinal fluid pressure. Observations on cerebrospinal fluid hydrodynamics. *J Neurol Sci.* 1965;2(4):307-27
2. Adams RD, Fisher CM, Hakim S, Ojemann RG, Sweet WH. Symptomatic occult hydrocephalus with "normal" cerebrospinal-fluid pressure: a treatable syndrome. *N Engl J Med* 1965; 273:117-126
3. Formiga F, Mascaro J, Chivite D, Pujol R. Reversible dementia due to two coexisting diseases. *The Lancet* 2000;355:1154
4. Yusuf SW, Booth SA, Mishra RM. Falls and urinary incontinence in a 66-year-old woman. *The Lancet* 1996;347:1738
5. Wostyn P. Can chronic increased intracranial pressure or exposure to repetitive intermittent intracranial pressure elevations raise your risk for Alzheimer's disease? *Medical Hypotheses.* 2004;62(6):925-30
6. Sekhsaria S, Rahbar F, Fomufod A, Mason R, Kosoko O, Truth J. An unusual case of congenital cytomegalovirus infection with glaucoma and communicating hydrocephalus. *Clin Pediat (Phila)* 1992;31:505-507