

Arachnoid herniation with needle trauma in regional anaesthesia: Case report

Nilgün Şenol*, Memduh Kerman**, Kerem Kenan Coskun**, Feride Korkmaz***.

*Suleyman Demirel University, Faculty of Medicine, Department of Neurosurgery, Isparta/Turkey.

**Fatih University, Sema Hospital, Department of Neurosurgery, Istanbul/Turkey.

***Fatih University, Sema Hospital, Department of Anesthesiology and Reanimation, Istanbul/Turkey.

Özet

Rejyonel anestezi sırasında iğne travmasına bağlı oluşan araknoid herniasyon: olgu sunumu

Giriş: Spinal ve epidural bloklar rejyonel anesteziye kullanılan tekniklerdir ve lomber ponksiyon yolu ile anestezi uygulanır. Lomber ponksiyon minimal riski olan bir yöntemdir. İğne ucunun dura matere hafif bir teması perforasyona neden olabilir. Ciddi komplikasyonlar çok nadir olarak görülebilir. Olgu: Bu çalışmada, rejyonel anestezi sonrasında araknoid herniasyon meydana gelen bir olgu sunulmuştur. Araknoid herniasyon rastlantısal olarak bel ve bacak ağrısı nedeni ile yapılan ucuncu operasyon sırasında görülmüştür. Dekompresyon ve posterior stabilizasyona ek olarak dura defekti primer tamir edilmiştir. Sonuç: Spinal ve epidural yöntemler oldukça sık kullanılmalarına rağmen nadiren komplikasyonlar gelişebilmektedir. Epidural tüp yerleştirme veya spinal ponksiyon sırasında minor dural travma ile araknoid herniasyon görülebilmektedir. Rejyonel anestezi esnasında komplikasyonlara neden olmamak için iğnenin boyutları önem kazanmaktadır.

Anahtar Kelimeler: araknoid herniasyon, epidural anestezi, dural hasar

Abstract

Background: Spinal and epidural blocks are accepted techniques for regional anaesthesia, and lumbar puncture is the way of application anaesthesia. Lumbar puncture is a procedure associated with minimal risk. Slight contact of the needle tip to the dura mater can cause perforation. Serious complications are relatively rare. Case Report: We report a rare case of an arachnoid herniation, occurred after regional anaesthesia. Arachnoid herniation was seen incidentally during the third operation for lumbar back and leg pain. Dural defect is primarily repaired additional to the decompression and posterior stabilization. Conclusion: Although spinal and epidural procedure is widely used for anaesthesia, it may rarely cause complications. Arachnoid herniations can be seen with the minor dural trauma from inserting the epidural tube or spinal puncture. Needle gauge is important during regional anaesthesia not to cause complications.

Key Words: arachnoid herniation, epidural anaesthesia, dural injury

Introduction

Lumbar puncture for spinal anaesthesia is a procedure with low morbidity and risk(1). One of the risks in this technique is that light contact to dura mater by the tip of the needle can cause perforation(2). Minor dural traumas that occurs from inserting the epidural tube or spinal puncture may cause arachnoid cysts or adhesive arachnoiditis(3). The effect of the needle size is important on severity of the injury. Smaller needles (24 gauge) may lead to less injury than larger needles (19 gauge)(4).

Corresponding Address: Nilgün Şenol M.D., Assistant Professor
Süleyman Demirel University, Faculty of Medicine,
Department of Neurosurgery, Çünür/ Isparta-Turkey
Tel: 0 246 2119298 / 0 533 2555009 **Fax:** 0 246 2112830
E-mail: drnilgunsenol@yahoo.com

Müracaat tarihi: 05.05.2014
Kabul tarihi: 14.05.2014

Case Report

A 68-year-old woman admitted to our hospital with low back and leg pain with numbness of bilateral lower extremities. The patient had previously undergone two surgery for L4-5 herniated disc with regional anaesthesia in another clinic fifteen years ago. Neurological examination revealed bilateral hypoactive deep tendon reflexes, bilateral straight leg raise test was positive. Magnetic resonance imaging revealed lateral recess stenosis with compression of left L5 root and spinal stenosis at L3 vertebra level. In the operation after L3 total laminectomy, an arachnoid herniation was seen at the L2-3 disc level which was thought to be a

complication of previous regional anaesthesia. (figure 1). Dura repaired primarily. Bilateral L3,L4,L5 foraminotomy and L2-3-4 posterior stabilization performed as there was a fusion at the level of L4-5.

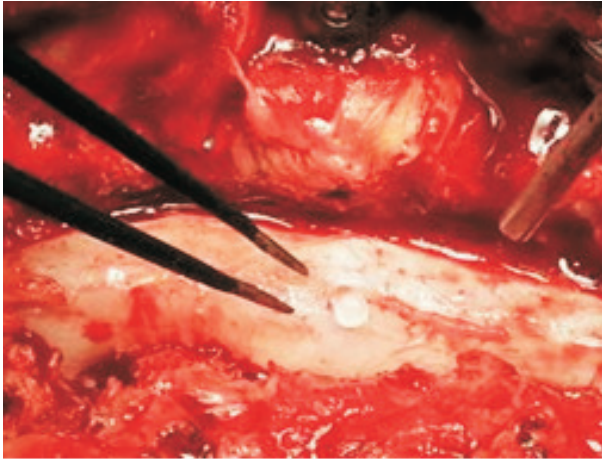


Figure 1: Arachnoid herniation at L2-3 disc level

Discussion

Anatomical structure of the membranes around the spinal cord has to be known well in order to prevent complications especially in regional anaesthesia. Mechanical disruption of dura mater may result in injury to the spinal cord, cerebrospinal fluid (CSF) leakage or herniation of endoneural contents. It is evident that dura has high tensile strength under pressure, that makes it resistant to puncture(2,5). If dura is damaged, arachnoid membrane under dura mater, makes the watertight barrier to CSF that constitute resistance to perforation(6,7). Fink and Walker reported the structure of dura mater after studying by transmission electron microscopy, and they notified the external surface of the dura consists of thin collagen fibers and thick elastic fibers organized in bands that aligned in various direction(8). Dura has multipl layers with a mean thickness of 4-5Mm, and each layer was connected with its surrounding through collagen bridges(8). Under dura mater, arachnoid lamina was separated as a thin and translucent membrane containing CSF within the subarachnoid space(9).

Inner part of the dura mater and the external part of the arachnoid lamina comprise the subdural compartment. Reina et al had examined the subdural compartment with transmission electron microscopy and they reported approximately 2-6 layers below

the dura and 10-14 layers adjacent to the arachnoid lamina(9). By scanning electron microscopic images they found dural and arachnoid layers continuity in some regions and by transmission electron microscopy they reported the characteristics of areas where the inner layer of the dura mater was separated from the outer layer of the arachnoid membrane. This structure is important for the formation of arachnoid herniation or CSF leakage and the other complications during regional anaesthesia(10).

The thin and fragile arachnoid laminae may cause the needle stay at this subdural compartment without CSF leakage, but with the CSF pressure this fragile structure can herniate from the dural gap. Also epidural fat has more fibrous stroma in adults as a barrier that prevents dissection of CSF in the epidural space(10).

The gauge of the Tuohy needle, needle angulation, bevel orientation, the number of attempts used to pass catheters and punctures are important in occurrence of complications.

Mehta and Salmon searched the sites of the Tuohy needle orifices in their study by using radiographic contrast and reported that the Tuohy needle bevel was located partially in the epidural space and partially in the subdural space in 7% of the cases(11). Selander et al demonstrated in their study that needle tip characteristics are also necessary in fascicular penetration as they used in peripheral nerve blokage, like long-bevel (12° - 15°) needles are more risky than short-bevel (45°) needles(12). Sala et al demonstrated the blunt (30°) and sharp (15°) needles for signs of fascicular damage microscopically in cadaveric sciatic nerve, and they reported damaged fasciculus with sharp-tip group(13).

Pitkanen et al had reported the serious complications related to spinal and epidural anaesthesia in 216 patients like; fatalities, neuraxial haematoma, infections, paraparesis, nerve injury(1). Arachnoid herniations were not noted in this study as it is a minor complication.

Conclusion

Our suggest that multipl attempts at catheter passage can damage dura mater with different needle gauges, and with this needle-related dural trauma various complications may occur. Needle tip design, the length, the sharpness and the number of attempts are important.

References

1. Pitkanen MT, Aromaa U, Cozanitis DA, Forster JG. Serious complications associated with spinal and epidural anaesthesia in Finland from 2000 to 2009. *Acta Anaesthesiol Scand* 2013;57:553-564
2. Zarzur E, Goncalves JJ. The resistance of the human dura mater to needle penetration. *Regional Anaesthesia* 1992;17:216-218
3. Hirai T, Kato T, Kawabata S, enomoto M, Tomizawa S, Yoshii T, Sakaki K, Shinomiya K. Adhesive arachnoiditis with extensive syringomyelia and giant arachnoid cyst after spinal and epidural anaesthesia. *Spine* 2012;37(3):E195-E198
4. Steinfeldt T, Nimphius W, Werner T, et al. Nerve injury by needle nerve perforation in regional anaesthesia: does size matter? *Br J Anaesth* 2010;104(2):245-253
5. Reina MA, Dittmann M, Garcia AL, van Zundert A. New prospectives in the microscopic structure of human dura mater in the dorsolomber region. *Reg Anaesth* 1997;22:161-6
6. Reina MA, De Leon Casacola O, Lopez A, De Andres JA, Mora M, Fernandez A. The orijin of the spinal subdural space: ultrastructural findings. *Anesth Analg* 2002;94:991-5
7. Hardy PAJ. Can epidural catheters penetrate dura mater? An anatomical study. *Anaesthesia* 1986;80:747-53
8. Fink BR, Walker S. Orientation of fibers in human dorsal lumbar dura mater in relation to lumbar puncture. *Anaesth Analg* 1989;69:768-772
9. Reina MA, Collier CB, Prats-Galino A, Puigdellivol-Sanchez A, Maches F, Andres JA. Unintentional subdural placement of epidural catheters during attempted epidural anaesthesia. *Regional Anaesthesia and Pain Medicine* 2011;36(6):537-541
10. Ng WH, Drake JM. Symptomatic spinal epidural CSF collection after lumbar puncture in a young adult: case report and review of literature. *Childs Nerv Syst* 2010;26:259-262
11. Mehta M, Salmon N. Extradural block. Confirmation of the injection site by x-ray monitoring. *Anaesthesia* 1983;40:1009-1012
12. Selander D, Dhuner KG, Lundborg G. Peripheral nerve injury due to injection needles used for regional anaesthesia. An experimental study of the acute effects of needle point trauma. *Acta Anaesthesiol Scand* 1977;21(3):182-188
13. Sala-Blanch X, Ribalta T, Rivas E, et al. Structurel injury to the human siatic nerve after intraneural needle insertion. *Reg Anesth Pain Med* 2009;34(3):201-205