

Olgu Sunumu (Case Report)

An Atypic Presentation Of Spontaneous Hemopneumothorax: A Case Report

Atipik Bir Spontan Hemopnömotoraks Olgu Sunumu

Umut Yücel ÇAVUŞ¹, Fatih KIRAR², Ezgi HASBEK¹, Macit AYDIN¹, Mehmet Sait DOĞAN³

¹ Emergency Department, Dışkapı Yıldırım Beyazıt Training and Research Hospital, Ankara

² Emergency Department, Dr. Lütfi Kırdar Kartal Training and Research Hospital, İstanbul

³ Radiology Clinic, Mardin State Hospital, Mardin

Özet

Spontan pnömotoraks genellikle göğüs ağrısı, nefes darlığı gibi klasik semptomlarla tanı alırken nadiren farklı ve yanıltıcı semptomlarla da ortaya çıkabilir. Aynı zamanda nadiren hemopnömotoraks tablosuna dönüşebilir. Özellikle acil serviste bu hastaların zamanında ve doğru tanı alabilmesi hayati önem arz eder. Biz bu yazımızda acil servise konversiyon bozukluklarına benzer atipik semptomlarla gelen bir spontan hemopnömotoraks olgusunu sunmayı amaçladık.

Anahtar kelime: hemopnömotoraks, göğüs ağrısı, dispne.

Abstract

Spontaneous pneumothorax generally takes diagnosis with general symptoms such as chest pain and dyspnea. However, it may rarely exist with atypical and misleading symptoms. Furthermore, it may turn into hemopneumothorax uncommonly. In time, correct diagnosis of these patients establishes vital importance in the emergency department. In this report, we aimed to present a spontaneous hemopneumothorax case arriving to the emergency department with atypical symptoms mimicking conversion disorder.

Key words: hemopneumothorax, chest pain, dyspnea.

Introduction

Spontaneous hemopneumothorax (SHP) may be mixed with conversion disorder (CD) because presentation of clinical symptoms is observed rarely. Coexistence of air and blood in the pleural cavity is called SHP that's not associated with trauma¹. Most of the patients with SHP are adolescent and male. SHP is usually seen with chest pain and dyspnea². However it may also presented with rare and nonspecific symptoms like presyncope and feeling of faint. We reported a patient who

was frequently admitted to the emergency department with feeling of faint and presyncope with delayed diagnosis SHP because of mimicking CD.

Case Report

A 23 year-old male patient was admitted to the emergency department with the complaint of presyncope and feeling faint. In the patient's background information, the patient specified that he has applied to the emergency service with the

complaints of presyncope and feeling faint frequently and he has been using an antidepressant for the last month. There was no history of trauma, lung diseases, bleeding diathesis, Systemic Lupus Erythematosus, Marfan's Syndrome, congenital afibrinogenemia, sarkoidosis which are rare causes of SHP. His vital signs were as the following: temperature was 36.6 °C, pulse was 72 /min, blood pressure was 120/70 mmHg, respiratory count was 14 /min.

His physical examination was normal, except the decreased respiratory sound of the left lung at the inferior zone.

His white cell blood count was 14.280 / μ L and hemoglobin was 10.3 g/dl. His posteroanterior lung x-ray showed hemopneumothorax on the left side (fig 1). His thorax computed tomography (CT) showed massive hemopneumothorax on the left side (fig 2). Emergency thoracotomy was planned after diagnosis of hemopneumothorax with thorax CT. 3000 cc hemorrhagic fluid was deflated during the operation. Two arterial collaterals were observed to extend from subclavian artery to the left upper lobe apical bullae where the bleeding is originated from. Intraoperative bleeding control was made. There was no postoperative complication and the patient was discharged with full recovery.

Discussion

SHP is usually observed in young males who are in the 20-40 year-old age group. SHP is an infrequent clinical entity that was initially described by Laennec, in 1828. In the pleural cavity, presence of more than 400 ml of blood with spontaneous pneumothorax is defined as SHP, that has appeared in our patient with spontaneous pneumothorax at the rate of 1% to 12%². SHP is frequently presented with chest pain and dyspnea. In addition, hypotension may occur in association with the severity of bleeding. Symptoms like dizziness, syncope, and blurred vision are seen during the change of blood pressure cause of bleeding in the pleural cavity. These symptoms mimic the clinical presentation of psychiatric disorders, especially CD. Likewise, although our patient has frequently been admitted to the emergency department, feeling faint and with presyncope, the clinic has been misdiagnosed CD. In our evaluation, hemodynamic status of patient was stable. However 3000 cc hemorrhagic fluid is evacuated. CD is frequently presented with neurological symptoms like decrease of coordination or balance, paralysis, difficulty in swallowing, inability to speak, vision problems, deafness, seizures or convulsions^{3,4}.

In a reported case, CD is approximately mimicked neurological disorders but simulation symptoms of SHP is not reported as interesting. Conventional radiograph is the first choice of imaging used for demonstration of SHP. Blunt costophrenic

angle and ipsilateral air-fluid level is determined in the posteroanterior chest x-rays and a supine chest radiograph may show apical capping of fluid surrounding the superior pole of the lung. Nevertheless, SHP may be confirmed with Thoracic Computed Tomography¹. In our patient, posteroanterior chest X-ray revealed massive hemopneumothorax on the left side. The treatment of SHP includes; tube thoracostomy, management of hypovolemia and surgery for treatment of the bleeding source with thoracotomy or video-assisted thoracoscopic surgery (VATS). Hypovolemic shock, continuous bleeding (>100ml/hour), persistent air leak, impaired lung expansion, pachypleuritis or recurrent pneumothorax are supposed to occur during emergency thoracotomy or VATS [5]. VATS is a minimally invasive technique and is decreases mortality and recurrence rates⁶. Total blood volume of humans is about 60 ml/kg in females and 66 ml/kg in males⁷. Blood loss in an amount greater than 30% of total blood volume is performed as hypovolemic shock. If the bleeding is greater than 15% of total blood volume, clinical symptoms develop and surgery is needed at this stage⁸.

Conclusion

Although SHP is an important and vital disease in the emergency department, sometimes it may be presented with atypical symptoms and be misdiagnosed. The evaluation of patients should never be biased and physical examination should not be missing. Organic pathologies must always be ruled out primarily.

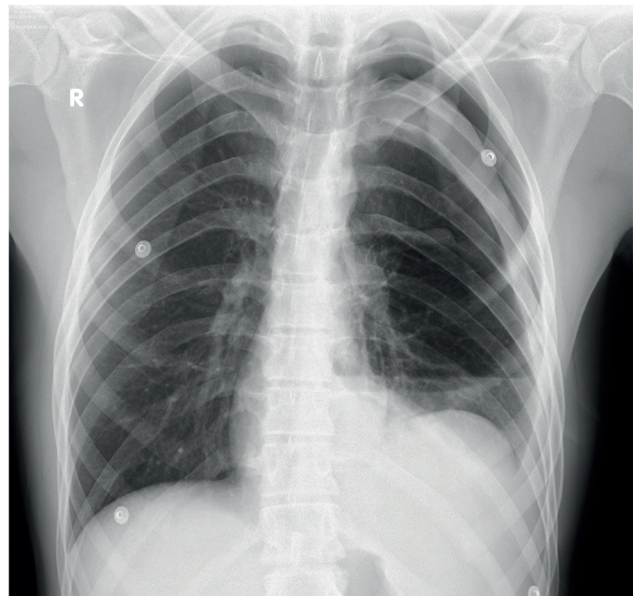


Figure 1. PA Lung X-Ray: Hemopneumothorax on the left side

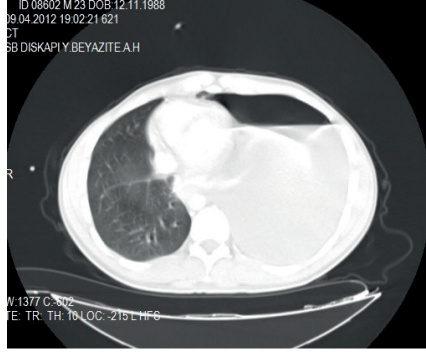


Figure 2. Thorax CT: Massive hemopneumothorax on the left side

References

1. Hsu CC, Wu YL, Lin HJ, Lin MP, Guo HR. Indicators of haemothorax in patients with spontaneous pneumothorax. *Emerg Med J*. 2005 Jun;22(6):415-7.
2. Ohmori K, Ohata M, Narata M, Iida M, Nakaoka Y, Irako M, Kitamura K, Nakamura S, Natori H, Sezaki Y. [28 cases of spontaneous hemopneumothorax]. *Nihon Kyobu Geka Gakkai Zasshi*. 1988 Jul;36(7):1059-64.
3. Ozer S, Ozcan H, Dinç GS, Ertuğrul A, Rezaki M, Uluşahin A. [Two stiff person cases misdiagnosed as conversion disorder]. *Turk Psikiyatri Derg*. 2009 Winter;20(4):392-7.
4. Cheng YL, Yu CP, Hsu SH, Lee SC. Hemangiopericytoma of the pleura causing massive hemothorax. *J Formos Med Assoc*. 2000 May;99(5):428-30.
5. Battistella FD, Benfield JR. Blunt and penetrating injuries of the chest wall, pleura and lungs. IN: Shields TW, Locicero J 3rd, Ponn RB, editors. *General thoracic surgery*. 5th ed. Philadelphia:Lippincott Williams &Wilkins 2000;p. 815-31.
6. Hwong TM, Ng CS, Lee TW, Wan S, Sihoe AD, Wan IY, Arifi AA, Yim AP. Video-assisted thoracic surgery for primary spontaneous hemopneumothorax. *Eur J Cardiothorac Surg*. 2004 Nov;26(5):893-6.
7. Hsu NY, Shih CS, Hsu CP, Chen PR. Spontaneous hemopneumothorax revisited: clinical approach and systemic review of the literature. *Ann Thorac Surg*. 2005 Nov;80(5):1859-63
8. Marino PI: Hemorrhage and hypovolemia. In: Eiichi Inada, translator. *THE ICU book*, 2nd Japanese Ed. Tokyo: Medical Sciences International 2001;169-171

Yazışma Adresi / Correspondence:

Umut Yücel Çavuş

Emergency Department, Dışkapı Yıldırım Beyazıt Training and Research Hospital, Ankara

e-posta: acildrumut@yahoo.com