



## Olgu Sunumu

# Papillon Lefevre Syndrome and Oral Findings in Pediatric Patient: A Rare Case Report

Pediyatrik Bir Hastada Papillon Lefevre Sendromu ve Oral Bulguları: Nadir Bir Olgu Sunumu

Serkan Dündar<sup>1</sup>, Mustafa Ersöz<sup>2</sup>, Eriş Sinan Yücel<sup>3</sup>, Özge Çelik<sup>2</sup>, Abubekir Eltas<sup>1</sup>

<sup>1</sup> Inonu University, Faculty of Dentistry, Department of Periodontology, Malatya, Türkiye

<sup>2</sup> Inonu University, Faculty of Dentistry, Department of Orthodontics, Malatya, Türkiye

<sup>3</sup> Selcuk University, Faculty of Dentistry, Department of Periodontology, Konya, Türkiye

<sup>4</sup> Inonu University, Faculty of Dentistry, Department of Orthodontics, Malatya, Türkiye

### Abstract:

Papillon-Lefevre Syndrome (PLS) is a rare autosomal recessive disorder. Cathepsin C Gene mutation are responsible for the etiology. PLS characterized by palmoplantar keratosis and severe periodontal destruction in early ages, affecting the primary and permanent dentition. In this case, we aimed to present a rare PLS and its oral findings.

**Key Words:** Papillon-Lefevre syndrome, palmoplantar keratosis, periodontitis, Cathepsin C Gene.

### Özet:

Papillon-Lefevre Sendromu (PLS) nadir görülen otozomal resesif genetik geçişli bir hastalıktır. Etyolojisinde Cathepsin C Gen mutasyonu sorumlu tutulmaktadır. PLS, palmoplantar keratosis ve yaşamın erken dönemlerinde süt ve daimi dişleri etkileyen şiddetli doku yıkımıyla birlikte görülen periodontitis ile karakterizedir. Bu vakada PLS ve oral bulgularını sunmayı amaçladık.

**Anahtar kelimeler:** Papillon-Lefevre sendromu, palmoplantar keratosis, periodontitis, Cathepsin C Geni

### Introduction

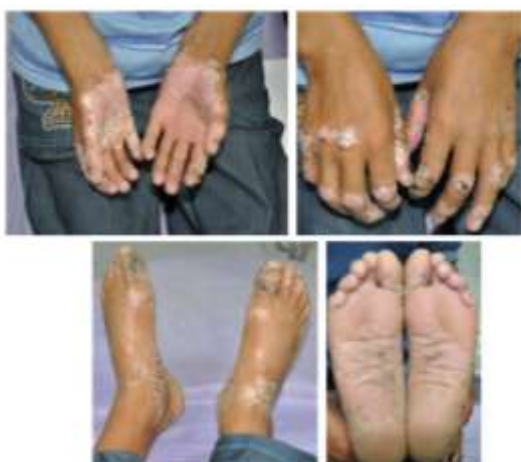Papillon-Lefevre syndrome (PLS) is an autosomal recessive hereditary disease that was first described in 1924 by Papillon and Lefevre. PLS is characterized by palmoplantar keratosis (hyperkeratosis in the palms and soles due to a keratinization disorder) and the premature loss of both the deciduous and permanent teeth because of severe periodontitis. This syndrome is rare, with a prevalence of 1–4 cases per million people (1). Thus far, more than 300 cases have been reported throughout the world (2). PLS cases have been reported more frequently in consanguineous marriages. The incidence is equal in men and women (3, 4). Chemotactic and phagocytic disorders and a reduction in antibacterial activity have been described in the polymorphonuclear cells of PLS patients (5). An increased susceptibility to infection was observed in approximately 20% cases of PLS, and lack of neutrophil function and intracranial calcification were among the other findings of the disease (6).

Mutations of the Cathepsin C (dipeptidyl aminopeptidase 1) Gene (CCG) are a known cause of the etiology of the disease, and a greater than 90% reduction in Cathepsin C activity has been observed in PLS patients. Genetic defects have been observed on chromosome 11q14–q21, a region that includes the CCG (7). Cathepsin C is an enzyme that plays key roles in the immune-inflammatory responses of myeloid and lymphoid cells and the function of the extracellular matrix, which is secreted by the palms, soles, and gum epithelial cells; further, it is responsible for processing

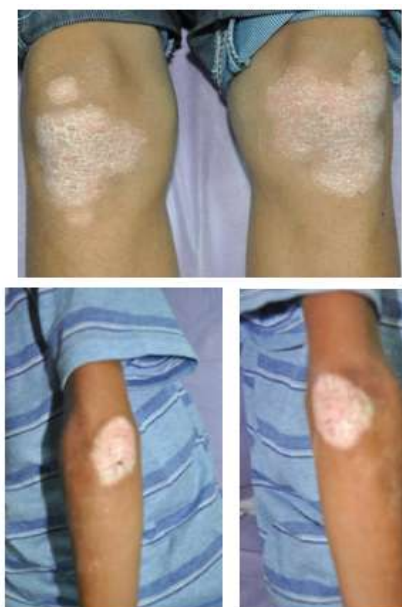and activating a variety of granule serine proteases (8). In PLS cases, the main cause of the predisposition to periodontal diseases and infection is due to the decreased phagocytic ability of neutrophils, bacterial infection, and the decreased mitogenic activity of B and T cells (2). Studies that have evaluated the periodontal status of PLS patients have shown loss of all deciduous teeth by 4 years of age as a result of prepubertal periodontitis, which begins with the development of an advanced degree of inflammation in these patients at 2–4 years of age. The inflammation disappears with the loss of the deciduous teeth, but reoccurs during the period of eruption of the permanent dentition, resulting in periodontitis and the subsequent loss of teeth. The atrophic alveolar crest are seen after the severe loss of bones that occurs on alveolar bone (7). Previous case reports proposed that non-surgical treatments, (such as oral hygiene education, scaling, root planing and curettage) and periodontal treatment including systemic antibiotherapy can fail and edentulous which is part of the syndrome in these cases (7). In such PLS cases, several publications recommend extracting the teeth early in order to protect the remaining alveolar bone (9). However, the results of various studies have shown that the success of the periodontal treatment and the prognosis vary according to specific differences in the individual (7). In this report, we present a rare case of PLS syndrome and the oral findings.

### Case Report

A 9-year-old boy presented to the Department of Periodontology, Faculty of Dentistry, İnönü University. His extra-oral examination revealed hyperkeratotic lesions on his palm, soles, the back of his foot/hand, which extended up to his fingers, and the knee and elbow regions (Figure 1, 2). We learned that the thickening had started on his hand and soles after he turned 1 year of age and had continued to increase gradually after he turned 3 years of age. In the patient's was detected any other problem mentally and systemically. No PLS findings had been reported in other family members, and the patient's parents are not related. He had been diagnosed with psoriasis after a previous dermatological examination.



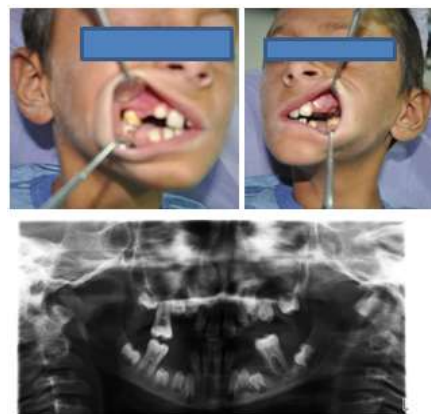
**Figure 1.** Hyperkeratotic lesions over the skin of the case. Lesions on the hands and feet.



**Figure 2.** Hyperkeratotic lesions over the skin of the case. Lesions on the elbows and knees.

The intra-oral examination revealed that he lost his deciduous teeth by 4 years of age. In the radiological and

periodontal examination, severe periodontal destruction was observed in the teeth that had first erupted: 16, 36, and 46. We decided to extract tooth 36 because maximum destruction and third-degree mobility were observed at this tooth. We determined that tooth 26 had been previously lost. Periodontal destruction was also observed in the patient's upper and low jaw anterior region teeth (the central and lateral teeth). The canines, premolar, and second molar teeth had not yet erupted. The patient's panoramic film showed an atrophic alveolar bone (Figure 3). After routine scaling and root planning, the patient was followed at the periodontology clinic.



**Figure 3.** Intraoral view of patient and panoramic radiograph showing generalized severe periodontal tissue loss especially molar teeth.

The patient was given a pre-diagnosis of PLS and was sent to İnönü University Faculty of Medicine department of dermatology for a consultation. In dermatologic clinic, from the lesions on the hands and the feet soles of the patient, the biopsy with the psoriasis and PLS preliminary diagnosis was obtained. The hyperkeratosis with irregular parakeratosis, acanthosis and perivascular infiltrate was available. The mycological examination made on the foot-sole-lesion was negative. The laboratory examinations were normal. In the examination of the other system, not any pathological findings were determined.

The result of the consultation was consistent with the pre-diagnosis of PLS. The patient was prescribed Neotigason (10 mg 1 × 1; acitretin) and Vaseline at the dermatology clinic.

### Discussion

PLS is a syndrome that is characterized by diffuse palmoplantar keratoderma and aggressive periodontitis. The diagnosis is essentially based on clinical findings, and dermatologic, periodontal, and radiographic findings are important indicators for a diagnosis of PLS (Figure 1, 2, 3) (10). PLS palmoplantar keratotic lesions begin to appear at 1–5 years of age, which later spread to the front of the arms and legs. Because similar lesions may rarely be observed over the Achilles tendon, knee, and elbow, this syndrome might be incorrectly diagnosed as psoriasis (11, 12). The hair

usually has a normal appearance. A claw-like phalange with convex nails and osteolysis may be found in some types of PLS (10). The typical symptoms of PLS, namely hyperkeratotic lesions on the hand, foot, knee, and elbows, were observed in the patient described herein. Palmoplantar keratosis and severe periodontitis are found in Haim-Munk syndrome as well; however, symptoms such as arachnodactyly, acroosteolysis, and onychogryphosis distinguish this syndrome from PLS (10). Although physical and mental retardation have been reported in some cases, these characteristics were not detected in this patient (13).

Prepubertal periodontitis begins at the start of deciduous tooth eruption and ends with the loss of deciduous teeth by 4 years of age in PLS patients (7). In accordance with the findings of this syndrome, our patient had lost all of his deciduous teeth by the age of 4–5 years (Figure 3). Inflammation regresses after tooth loss, but reoccurs during the period of eruption of the permanent dentition, leading to subsequent loss of most of the permanent teeth. Conventional periodontal therapy (scaling, root planing, and antibiotic therapy) often does not yield satisfactory results in these patients, and an atrophic alveolar crest results from severe bone loss in the alveolar bone (7). Usually, total losses of the deciduous teeth and the permanent teeth occur at approximately 4 years of age and at 16 years of age, respectively (5). In the literature, several publications propose early tooth extraction to prevent the loss of alveolar bone and the secondary infection of the unerupted teeth for these patients (14). In our patient, severe periodontal destruction in the permanent teeth was identified in accordance with the oral findings of the syndrome. Scaling and root planing were performed for the permanent teeth associated with periodontal destruction, and tooth 36, which was associated with the maximum destruction, was extracted. The atrophic alveolar crest observed in this case, which resulted from premature loss of the deciduous teeth, is compatible with the previously observed cases; moreover, most of the permanent teeth had not erupted and severe periodontal destruction was present (Figure 3) (7).

The polymorphonuclear leukocytes (PMNLs) that are observed in PLS patients are thought to be related to rapid periodontal destruction due to chemotactic and phagocytic defects (7). Bacteria such as *Actinobacillus actinomycetemcomitans*, *Prevotella nigrescens*, *Fusobacterium nucleatum*, and *Peptostreptococcus micros* can be isolated from the periodontal lesions (5). *Actinobacillus actinomycetemcomitans*, in particular, is an aggressive periodontitis microflora that characteristically causes severe destruction (15). But in this case we did not perform any microbiological examination.

Several studies that have evaluated the host defense in PLS suggested immunological dysfunction in these patients, which included suppressed chemotactic and phagocytic functions in PMNLs, low integrin expression, and increased superoxide production. In

contrast to these results, other studies have reported normal PMNL chemotaxis function and no difference in the peripheral lymphocyte populations in these patients (7).

Cathepsin C is a lysosomal proteinase that plays an important role in the intracellular degradation of proteins and it activates a variety of leukocyte and mast cell serine proteinases. It is present in PMNLs, alveolar macrophages and osteoclasts, the lung, the kidney, and the oral keratinized gingiva; further, it is present in keratinized epithelial areas such as the palms, the soles, and the knee. A greater than 90% reduction in Cathepsin C activity has been observed in PLS patients (7). A defect in the CCG causes severe infection by disrupting the immune response of PLS patients (8). Liver abscesses were observed due to the presence of *Staphylococcus aureus* in some pediatric cases of PLS (10). In the present patient, the presence of aggressive periodontitis, which is compatible with a lack of neutrophil function and is characterized by severe periodontal destruction, as in other cases, suggests CCG mutation.

Only in recent years has an effective treatment for PLS patients been reported. In the few cases that have been described in recent years, palmoplantar and periodontal lesions have been treated successfully with etretinate, isotretinoin, and acitretin (16, 17).

### Conclusion

Herein, we have presented the case of a patient with a rare genetic disease, PLS. A reduced host response is an important factor in periodontal tissue destruction, and dermatological findings combined with oral findings can be considered important factors when diagnosing PLS in patients.

*Note: The information presented in this manuscript was reported at the 42<sup>th</sup> Annual Scientific Meeting of the Turkish Association of Periodontology, November 08 to 10, 2012, Ankara / TURKIYE.*

*Acknowledgments: We have not a financial relationship with the organization that sponsored the research.*

### References

1. Uçmak D, Yeşilova Y, Er MN, Dal T. Three cases of Papillon-Lefevre syndrome : Case Report. *Journal of Clinical and Experimental Investigations* 2011; 2 (2): 222-224.
2. Bicer AZY, Peker I, Demirel O. Papillon-Lefevre Syndrome: Report of two cases in the same family. *Cumhuriyet Dent J* 2012;15(2):149-155.
3. Hattab FN, Amin WM. Papillon-Lefevre syndrome with albinism: A review of the literature and report of 2 brothers. *Oral Surg Oral Med Oral Pathol Oral Radiol Endod* 2005;100:709-716.
4. Dhanrajani PJ. Papillon-Lefevre syndrome:

- Clinical presentation and a brief review. Oral Surg Oral Med Oral Pathol Oral Radiol Endod 2009;108:e1-e7.
5. Ghaffer KA, Zahran FM, Fahmy HM, Brown RS. Papillon-Lefèvre syndrome: neutrophil function in 15 cases from 4 families in Egypt. Oral Surg Oral Med Oral Pathol Oral Radiol Endod 1999; 88: 320-325.
  6. Wiebe CB, Hakkinen L, Putnins EE, Walsh P, Larjava HS. Successful periodontal maintenance of a case with Papillon-Lefevre syndrome: 12-year follow-up and review of the literature. J Periodontol 2001;72:824-830.
  7. Haytaç MC, Özçelik O. Papillon-Lefevre Syndrome Periodontitis: 1 Year Follow-up (A Clinical Report). Journal of Ankara University Faculty of Dentistry. 2006,33(1) 127-133.
  8. Allende LM, Moreno A, de Unamuno P. A genetic study of cathepsin C gene in two families with Papillon-Lefèvre syndrome. Mol Genet Metab 2003; 79: 146-148.
  9. Etöz OA, Ulu M, Kesim B. Treatment of Patient With Papillon-Lefevre Syndrome With Short Dental Implants: A Case Report. Implant Dent 2010;19:394–399.
  10. Yıldırım ZK, Derelioğlu SS, Kantarcı M, Yılmaz Y, Büyükavcı M. Papillon-Lefèvre syndrome: report of three cases in the same family. The Turkish Journal of Pediatrics 2012; 54: 171-176.
  11. Nazarro V, Blanchet-Bardon C, Mimos C, Revuz J, Puis-sant A. Papillon-Lefevre syndrome. Arch Dermatol 1998;40(6):533-539.
  12. Pratchyapruit WO, Kullavavanijaya P. Papillon-Lefevre syndrome: a case report. J Dermatol 2002; 29(5):329-335.
  13. Judge MR, Mclean WHI, Munro CS. Disorders of Keratinization. Rook's Textbook of Dermatology. ED. Burns T, Berathnach S, Cox N, Griffiths C. Oxford, Blackwell Publishing 2004;34,111.
  14. Woo I, Brunne DP, Yamashita DD, Le BT. Dental implants in a young patient with Papillon-Lefevre syndrome: A case report. Implant Dent. 2003;12:140-144.
  15. Nickles K, Schacher B, Ratka-Krüger P, Krebs M, Eickholz P. Long-term results after treatment of periodontitis in patients with Papillon-Lefevre syndrome: success and failure. J Clin Periodontol 2013; 40: 789–798.
  16. Pacheco JJ, Coelho C, Salazar F, Contreras A, Slots J, Velazco CH. Treatment of Papillon-Lefevre syndrome periodontitis. J Clin Periodontol 2002;29(4):370-374.
  17. Rudiger S, Petersilka G, Flemming TF. Combined systemic and local antimicrobial therapy of periodontal disease in Papillon-Lefevre syndrome. A report of 4 cases. J Clin Periodontol 1999;26(9):847-854.

Serkan Dundar, Research Assistant  
Address: Inonu University, Dentistry Faculty,  
Department of Periodontology 44280, Malatya,  
TURKEY  
E-mail : [dtserkandundar@gmail.com](mailto:dtserkandundar@gmail.com),  
[serkan.dundar@inonu.edu.tr](mailto:serkan.dundar@inonu.edu.tr)