

Orijinal Araştırma

Intentional Replantation and Alternative Root Surface Treatment with an Er, Cr: YSGG Laser: 36-Month Follow-up of a Case

Kasıtlı Replantasyon ve Er, Cr: YSGG Lazer ile Alternatif Kök Yüzey Tedavisi: 36 Aylık Vaka Takibi

Esra Ercan¹, Davut Çelik², Cihan Uysal³, Güneş Bulut Eyüpoğlu⁴

¹Karadeniz Technical University, Department of Periodontology, Trabzon, Turkey

²Karadeniz Technical University, Department of Endodontics, Trabzon, Turkey

³Private Practice, Dent Group, İstanbul, Turkey

⁴Karadeniz Technical University, Department of Restorative Dentistry, Trabzon, Turkey

Özet

Kasıtlı replantasyon periodontal olarak umutsuz dişlerin tedavisinde bir tedavi seçeneğidir. Bu işlem sırasında, uygun kök yüzey muamelesi kritik bir aşamadır ve ankilozu geciktirerek sonucu pozitif etkilemektedir. Bu amaçla farklı yöntemler kullanılmaktadır. Bu vaka raporunda kök yüzey muamelesinde Er, Cr: YSGG lazer kullanılmıştır. Aşırı kemik kaybı olan periodontal açıdan umutsuz dişin tedavisinde replantasyon kararı verilmiştir. Kök kanal tedavisinden sonra çekim gerçekleştirilmiş ve Er, Cr: YSGG lazer ile kök yüzey muamelesi yapılmıştır. Otuzaltı ayın sonunda kök rezorpsiyonu izlenmemiştir. Klinik olarak da herhangi bir inflamasyon bulgusuna rastlanmamış ve ilave ataçman kazancı olduğu görülmüştür. Bu vaka raporuna göre Er, Cr: YSGG lazer, periodontal olarak umutsuz dişlerin replantasyonunda kök yüzey muamelesi aşamasında umut vadeci sonuçlar ortaya koymuştur. Er, Cr: YSGG lazerin kasıtlı replantasyondaki etkinliğini ortaya koymak için uzun dönemli kontrollü klinik ve histolojik çalışmalara ihtiyaç vardır.

Anahtar Kelimeler: Kasıtlı Replantasyon, Er, Cr: YSGG Lazer, Kök Yüzey Muamelesi.

Abstract

Intentional replantation is a treatment option for periodontally hopeless teeth. During the process, appropriate treatment of the root surface, a critical treatment step, has a positive effect by delaying ankylosis. Different methods are used for this purpose. In this case report, the root surface of the maxillary first incisor was treated with an Er, Cr: YSGG laser. The patient had a hopeless tooth with excessive bone resorption and we decided to attempt replantation. After root canal treatment, extraction was performed and the root surface was treated with an Er, Cr: YSGG laser. After 36 months, there was no evidence of root resorption. Periodontal attachment gain was seen, with no gingival inflammation. In this case report, the root surface of a periodontally hopeless tooth was treated with an Er, Cr: YSGG laser with promising results. Long-term controlled clinical trials and histological studies are needed to investigate the potential impact of Er, Cr: YSGG laser treatment in intentional replantation.

Keywords: Intentional Replantation, Er, Cr: YSGG Laser, Root Surface Treatment.

Introduction

Intentional replantation has been defined as “the act of deliberately removing a tooth and following examination, diagnosis, endodontic manipulation and repair returning the tooth into its original socket” (1). In patients with severe periodontal disease characterized by advanced bone degeneration, the extraction of periodontally unsalvageable teeth is the only treatment option. In these cases, replantation may be an alternative for at least some period of time. Although intentional replantation is contraindicated in periodontally involved teeth, several clinical reports have documented successful results (2-5). Various techniques are used for intentional replantation. Demiralp et al. (2) treated periodontally involved unsalvageable teeth with intentional replantation using

tetracycline–hydrochloric acid (HCl), and reported improvement in clinical periodontal parameters. In a case report, the intentional replantation of a periodontally unsalvageable incisor using autologous platelet-rich plasma was considered to be a promising method for the induction of wound healing and bone formation around the tooth (3). Another technique involves the combined use of platelet-rich plasma, bioactive glass grafting material, and a non-resorbable membrane (4).

During replantation, most authors have recommended that the clinician avoid touching the root surfaces of the tooth to be replanted if a viable periodontal ligament (PDL) attachment is present (6-8). However, the removal of diseased PDL and necrotic cementum prior to replantation improves wound healing and prevents root

resorption (9, 10). A variety of mechanical and chemical methods of root-surface treatment have been reported (2, 3, 5). Laser therapies have recently been shown to satisfactorily remove subgingival calculus and affected cementum in periodontally involved teeth (11, 12). Erbium- and chromium-doped yttrium scandium gallium garnet (Er, Cr:YSGG) lasers have been used adjunctively or as alternatives to conventional hand instruments (13-15). Hakki et al. (16) recently described the positive effects of laser on attachment, spreading, and orientation of PDL cells in periodontally involved human teeth.

This case report describes the intentional replantation of a periodontally unsalvageable tooth with Er, Cr:YSGG laser irradiation of diseased root surfaces, and presents 3-year follow-up results.

Case Report

Patient evaluation

A 45-year-old non-smoking male with no systemic disorder was referred to the Department of Periodontology with grade III mobility of the maxillary right central incisor. Detailed clinical and radiographic examinations revealed excessive bone resorption necessitating extraction. Replantation was selected as the treatment strategy and the patient was given detailed information about the procedure.

Clinical periodontal parameters, including probing depth (PD), clinical attachment level (CAL), and plaque and gingival indices, were recorded at baseline and 6, 12, and 36 months postoperatively (Table 1).

Table 1. Clinical periodontal parameters measured during the 36-month follow-up period.

| Timepoint | Plaque Index | Gingival Index | Attachment Level (mm) | Probing Depth (mm) |
|-----------|--------------|----------------|-----------------------|--------------------|
| Baseline | 2 | 2 | 9 | 5.3 |
| 6 months | 0 | 0 | 6 | 2.6 |
| 12 months | 0 | 0 | 6 | 2.3 |
| 36 months | 0 | 0 | 6 | 2.3 |

Surgical Procedure

The endodontic therapy was completed in two sessions using 2.5% sodium hypochlorite solution as the irrigant and calcium hydroxide as an inter-appointment canal dressing for 1 week. Root canal obturation was completed with gutta-percha and resin sealer (AH Plus; Dentsply De Trey, Konstanz, Germany) using the lateral condensation technique.

The access cavity was restored with composite resin (Filtek Z-250; 3M ESPE). One week later, the tooth was extracted atraumatically under local anesthesia. After the administration of local anesthesia, the tooth was extracted atraumatically.

The diseased root surface was irradiated with an Er, Cr:YSGG laser (2,780 nm wavelength, 10 Hz, 1.5 W, 65% air and 55% water, H mode) with a 14-mm Z6 tip suitable for periodontal use in non-contact mode. The apical area of the alveolus was curetted and rinsed with sterile saline. During replacement, the tooth was repositioned carefully to achieve the ideal position. Composite material was placed interproximally to stabilize the tooth.

Postoperative Care

The patient received systemic antibiotic therapy (oral doxycycline, 200 mg on day 1 and 100 mg/day thereafter for 2 weeks) and was instructed to rinse with 0.12% chlorhexidine solution for 2 weeks. The patient was recalled after 3 weeks to receive professional oral care. He was then recalled for maintenance every 3 months.

Results

The patient healed without complications. Preoperative and postoperative clinical periodontal parameters are presented in Table 1. Radiographs taken before and 12 and 36 months after the operation are shown in Figures 1 to 3. Radiographs taken 12 months postoperatively revealed no root resorption and significant bone gain (Fig. 2). Ankylosis of the apical third of the root can be seen in the 12-month radiograph. This situation was maintained at 36 months (Fig. 3). The gingiva appeared healthy and PD was reduced. CAL increased due to gingival recession (Fig. 4). The periodontal status was the same and stable at the 36-month follow-up visit.

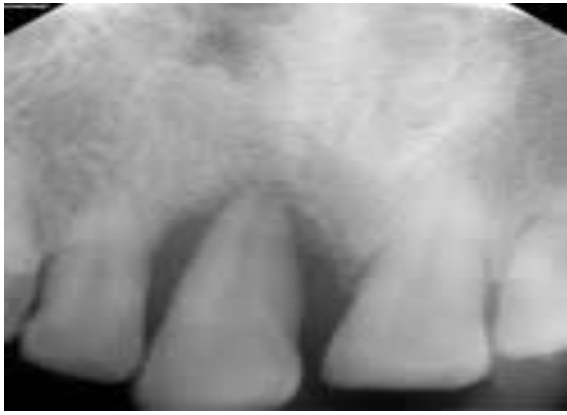

Figure 1. Baseline radiograph

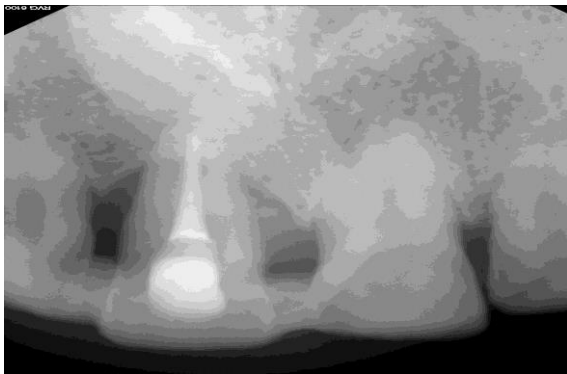


Figure 2. 12th month radiograph

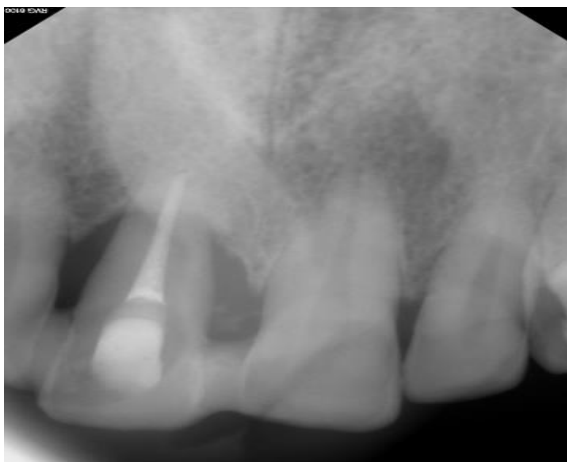


Figure 3. 36th month radiograph

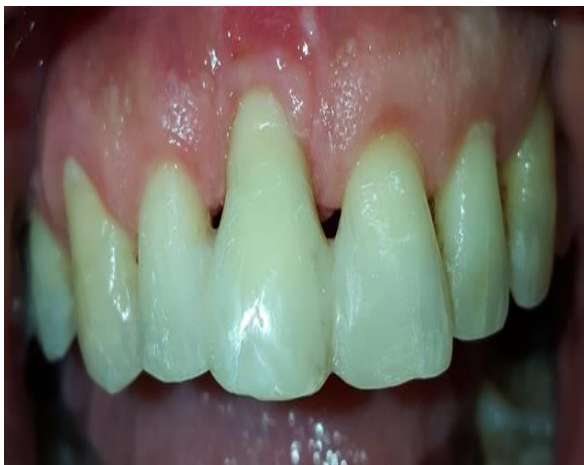

Figure 4. Clinical photograph of patient at 36th month

Discussion

Although general consensus has been reached regarding the contraindication of intentional replantation in periodontally involved teeth, many clinical reports have demonstrated that it can be used successfully as an alternative treatment of last resort for periodontally involved unsalvageable teeth (2, 5). In the case reported here, the affected tooth was associated with severe periodontal destruction that provided insufficient periodontal support, resulting in grade III mobility. We replanted this periodontally involved unsalvageable tooth and treated the root surfaces with an Er, Cr: YSGG laser. To our knowledge, this case report is the first published description of the use of laser irradiation during intentional replantation.

A wide variety of techniques have been applied during replantation. Regenerative techniques have been used successfully to enhance new bone formation. Demiralp et al (2) reported a decrease in PD and an increase in the amount of alveolar bone following intentional replantation using tetracycline-HCl. In 2006, Tözüm et al (3) reported successful bone regeneration around a replanted tooth that was treated with autologous platelet-rich plasma. In another case report (4), intentional replantation was performed with platelet-rich plasma in combination with bioactive glass grafting material and a non-resorbable polytetrafluoroethylene membrane. We did not use regenerative biomaterial in the case reported here, but alveolar bone gain and ankylosis were observed radiographically 12 and 36 months postoperatively. This may have been due to the laser treatment. Er, Cr: YSGG laser irradiation has been reported remove calculus without causing visible morphological changes of the root surface (17). The gingiva seemed healthy with no bleeding on probing and no periodontal pockets, with only gingival recession, at the end of 36 months (Figure 4, Table 1).

The baseline mean pocket depth (5.3 mm) was reduced to 2.3 mm at the 6-month follow-up and remained 2.3 mm at the end of 36 months. The patient has maintained his periodontal health for 3 years. The patient's oral hygiene at the last visit was also good, with no plaque around the tooth compared to baseline. The plaque index was scored 2 at baseline. The oral hygiene also improved and was 0 at the 6-month follow-up and has remained stable since then.

Surface topography is important for cell adhesion. Hakki et al (16) observed spindle-

shaped and well-attached fibroblasts on the root surfaces of periodontally involved teeth after Er, Cr:YSGG laser irradiation with parameters similar to those used in the present case. They showed that periodontally diseased root surfaces reduced the survival of PDL fibroblasts. The use of short-pulse laser treatment seems to provide superior conditions for the attachment of PDL fibroblasts to roots in comparison with long-pulse irradiation or hand instrumentation, or with untreated healthy root surfaces. In our patient, however, ankylosis occurred with no root resorption. We observed ankylosis in the 12- and 36-month radiographs (Figures 2 and 3). In our case, the laser treatment appeared to be successful for detoxifying the root surface and removing infected and necrotic periodontal ligament and cementum. At the end of this process, ankylosis occurred. One of the advantages of this technique was seen as additional bone gain. At baseline, the bone resorption had extended to the apical end of the tooth, as seen in Figure 1. However, the crestal bone level was between the apical and middle thirds of root surface (Figures 2 and 3).

To our knowledge, no previous report has demonstrated the role of laser irradiation in intentionally replanted periodontally unsalvageable teeth. In conclusion, Er, Cr:YSGG laser irradiation of periodontally involved root surfaces during replantation appears to be a promising technique. However controlled clinical trials are needed to investigate the potential impact of Er, Cr:YSGG laser treatment on bone formation in intentional replantation.

References

1. Grossman LI. Intentional replantation of teeth: a clinical evaluation. *J Am Dent Assoc* 1982; 104(5): 633-9.
2. Demiralp B, Nohutcu RM, Tepe DI, Eratalay K. Intentional replantation for periodontally involved hopeless teeth. *Dent Traumatol* 2003; 19(1): 45-51.
3. Tozum TF, Keceli HG, Serper A, Tuncel B. Intentional replantation for a periodontally involved hopeless incisor by using autologous platelet-rich plasma. *Oral Surg Oral Med Oral Pathol Oral Radiol Endod* 2006; 101(6): 119-24.
4. Demir B, Demiralp B, Guncu GN, Uyanik MO, Caglayan F. Intentional replantation of a hopeless tooth with the combination of platelet rich plasma, bioactive glass graft material and non-resorbable membrane: a case report. *Dent Traumatol* 2007; 23(3): 190-4.

5. Baltacioglu E, Tasdemir T, Yuva P, Celik D, Sukuroglu E. Intentional replantation of periodontally hopeless teeth using a combination of enamel matrix derivative and demineralized freeze-dried bone allograft. *Int Periodontics Restorative Dent* 2011; 31(1): 75-81.
6. Kratchman S. Intentional replantation. *Dental clinics of North America* 1997; 41(3): 603-17.
7. Dryden JA, Arens DE. Intentional replantation. A viable alternative for selected cases. *Dent Clin North Am* 1994; 38(2): 325-53.
8. Sharma NK, Duggal MS. Replantation in general dental practice. *Br Dent J* 1994; 176(4): 147-51.
9. Lindskog S, Pierce AM, Blomlof L, Hammarstrom L. The role of the necrotic periodontal membrane in cementum resorption and ankylosis. *Endod Dent Traumatol* 1985; 1(3): 96-101.
10. Mahajan SK, Sidhu SS. Periodontal ligament, extra-oral period and use of fluorides in replantation of teeth. *Indian J Med Res* 1982; 75: 441-5.
11. Cobb CM. Lasers in periodontics: a review of the literature. *J Periodontol* 2006; 77(4): 545-64.
12. Hakki SS, Berk G, Dundar N, Saglam M, Berk N. Effects of root planing procedures with hand instrument or erbium, chromium:yttrium-scandium-gallium-garnet laser irradiation on the root surfaces: a comparative scanning electron microscopy study. *Lasers in medical science* 2010; 25(3): 345-53.
13. Kelbauskiene S, Maciulskiene V. A pilot study of Er, Cr: YSGG laser therapy used as an adjunct to scaling and root planing in patients with early and moderate periodontitis. *Stomatologija* 2007; 9(1): 21-6.
14. Ishikawa I, Aoki A, Takasaki AA. Clinical application of erbium: YAG laser in periodontology. *J Int Acad Periodontol* 2008; 10(1): 22-30.
15. Crespi R, Cappare P, Toscanelli I, Gherlone E, Romanos GE. Effects of Er:YAG laser compared to ultrasonic scaler in periodontal treatment: a 2-year follow-up split-mouth clinical study. *J Periodontol* 2007; 78(7): 1195-200.
16. Hakki SS, Korkusuz P, Berk G, Dundar N, Saglam M, Bozkurt B, et al. Comparison of Er, Cr:YSGG laser and hand instrumentation on the attachment of periodontal ligament fibroblasts to periodontally diseased root surfaces: an in vitro study. *J Periodontol* 2010; 81(8): 1216-25.
17. Ting CC, Fukuda M, Watanabe T, Aoki T, Sanaoka A, Noguchi T. Effects of Er,Cr:YSGG laser irradiation on the root surface: morphologic analysis and efficiency of calculus removal. *J Periodontol* 2007; 78(11): 2156-64

Sorumlu Yazar

Esra ERCAN

Karadeniz Teknik Üniversitesi Diş Hekimliği

Fakültesi, Periodontoloji Anabilim Dalı

TRABZON, TÜRKİYE

E-mail: esraercan82@gmail.com