

LERICHE SYNDROME: A CASE REPORT

*Fatih ZOR, *Serdar ÖZTÜRK, *Doğan ALHAN, *Andaç AYKAN, *Selçuk IŞIK

*Department of Plastic and Reconstructive Surgery, Gulhane Military Medical Academy, Etlik Ankara, TURKEY

ABSTRACT

Leriche syndrome is a peripheric vasoocclusive disorder which primarily affects the abdominal aorta. This syndrome is usually treated by vascular surgeons. But complicated cases presents with various degree of tissue necrosis requiring reconstructive surgical procedures. But there is no report about this syndrome in thi plastic and reconstructive surgery literature. In this article a patient with leriche syndome is presented. Both the syndrome and the reconstructive options are discussed.

Keywords: Leriche syndrome, lower extremity reconstruction

LERICHE SENDROMU: OLGU SUNUMU

ÖZET

“Lerich” sendromu özellikle abdominal aortayı etkileyen periferik vazooklüziv bir hastalıktır. Bu sendrom genellikle vasküler cerrahlar tarafından tedavi edilir. Ancak çeşitli derecelerde görülebilen doku nekrozu ile komplike olan vakalarda rekonstrüktif cerrahi prosedürlere ihtiyaç duyulmaktadır. Bu duruma rağmen, bu sendrom, plastik ve rekonstrüktif cerrahi literatüründe hiç yer bulmamıştır. Bu makalede “lerich” sendromlu bir hasta sunulmaktadır. Sendrom hakkında genel bilgiler ve tedavi seçenekleri tartışılmıştır.

Anahtar kelimeler: Lerich sendromu, alt ekstremitte rekonstrüksiyonu

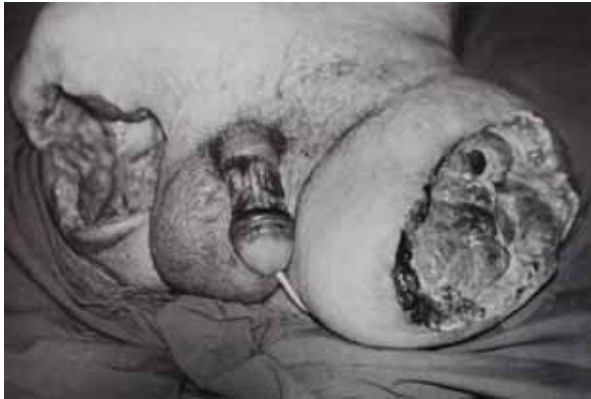INTRODUCTION

Leriche syndrome is a peripheric arterial occlusive disease, which has a high incidence as much as 18 % among persons over 70 years old.¹ The physiopathogenesis of the disease and the symptoms are similar with the other peripheric arterial occlusive pathologies. Progressive peripheric atherosclerosis is usually related to the age and the pathologic process starts much earlier than existence of the symptoms. There are many risk factors causing this syndrome. The mortality and morbidity of this rare syndrome is quite high leading 12 % of limb amputation². Although there have been many procedures explained focusing on reestablishing the arterial flow, there is no report about the reconstructive procedures. This article primarily aims to discuss the reconstructive procedures of a patient with bilateral lower extremity amputations due to Leriche syndrome.

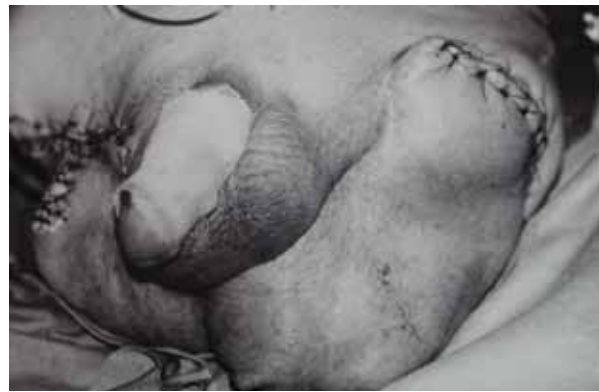Case report

A 59-year-old male patient was admitted to our department with diffuse infection and necrosis at the left proximal femoral and right hemipelvectomy amputation stumps and penile shaft (Figure 1). The history of the patient revealed an intermittent claudicatio starting 3 months ago. After palliative treatment for a while, left proximal femoral amputation and right hemipelvectomy had been performed at another facility 2 months ago. In order to eradicate the local wound infection, antibiotic treatment, local wound care and hyperbaric oxygen treatment were continued for 10 days. At the initial

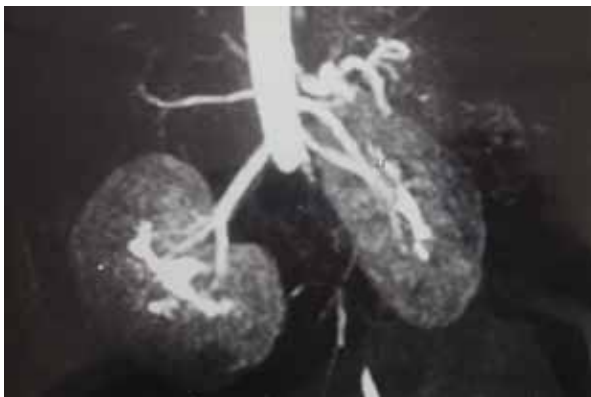
physical examination, mild hypotension, hyperthermia, tachycardia and confusion were found. Massive infection and necrosis at the right hemipelvectomy and left proximal femoral amputation stumps were observed with serious tissue defects. The proximal one third of the left femur and the right pelvic bones were exposed. A grade IV sacral pressure sore was also accompanied. The magnetic resonans angiography of the patient revealed total obstruction of the abdominal aorta just distal to the renal artery level (Figure 2). Thus both iliac arteries were completely occluded. Paranchymal infiltration was found at the lower zone of the right lung. Ampirical antibiotherapy and daily dressing changes were started. Blood, urine and wound cultures were obtained. Pseudomonas aeruginosa was cultured from the blood samples and specific antibiotherapy regimen consisting of Tienam and gentamycin were given. On the day 12 after admission, the patient was operated on. Wide debridement and left hemipelvectomy were performed. The sacral pressure sore which was in connection with left acetabulum was also debrided. And, the resulting defects were successfully covered with two musculocutaneous local transposition flaps including the external iliac muscles from both lomber areas and the skin defect on the penile shaft was grafted (Figure 3). During the postoperative period, the flaps stayed vital. On the postoperative day 5, the patient presented hypoxia and respiratory acidosis. The patient was supported with mechanical ventilation but unfortunately he died because of sepsis, on postoperative day 10. The wound healing was uneventful until the patient was died.



Resim 1: Preoperative appearance of the patient showing extensive soft tissue defect



Resim 2: Preoperative appearance of the patient showing extensive soft tissue defect



Resim 3: Preoperative appearance of the patient showing extensive soft tissue defect

DISCUSSION

Leriche syndrome is a peripheral arterial occlusive disorder. The etiology of this disease is similar with the other vasoocclusive disorders. So, the symptomatology is the same such as intermittent claudication, atrophy at lower extremities, impotence and so. The manifestations of the syndrome are lower extremity pain, which does not subside with rest, chronic wounds and necrosis.¹ Limb amputation was reported incidence as much as 12 %.² As there is chronic vascular disease, the reconstruction of the amputation stumps may be challenging for the reconstructive surgeon. There is not much information about this syndrome and the reconstructive options in plastic and reconstructive surgery literature.

In order to confirm the diagnosis, the method of choice is MR angiography. There is a risk for renal involvement so, the paramagnetic agent must be non-nephrotoxic.³ In the present case, the MR angiography revealed total obstruction of the aorta at the bifurcation of the iliac arteries.

The treatment of the syndrome is done at the acute, subacute and the chronic periods. The acute period treatment consists of desobliteration with Fogarty catheter followed by a thromboendarterectomy procedure.⁴ For the chronic cases, anatomical or extraanatomical by-pass is the first choice.⁵ These patients have high postoperative wound complications because of compromised vascularity. Sometimes coverage of the

defects of the amputation stumps may be challenging for the reconstructive surgeon. The amputation stumps of the patient in this article presented diffuse necrosis and infection. Since the patient was a heavy smoker with systemic peripheral vascular disease, microsurgical tissue transfer would be risky. Local transpositional musculocutaneous flaps including the external iliac muscles were preferred and the wounds were healed uneventfully.

Peripheral vascular disease is a common problem, with high mortality and morbidity.^{1,2,5} A rare form of this disease, Leriche syndrome and is mainly treated by cardiovascular surgeons. But, because of the characteristics of the syndrome, both chronic ischemic ulcers and the postoperative wound complications are not rare. The alternative reconstructive procedures of this syndrome are not described in the plastic surgery literature. Leriche syndrome usually presents with a small tissue defect on the foot by a podiatric physician.⁶ The reconstruction of these small defects are not difficult. But the severe forms of the syndrome may include the whole lower extremity, may cause serious tissue defects and may be challenging to overcome. The reported mortality rate of these severe forms of iliac arteries is over 70 %.^{7,8} Especially for the reconstruction of these serious tissue defects, local musculocutaneous flaps are superior to fasciocutaneous flaps or microsurgical tissue transfers because of the compromised vascular status.

Here, an extraordinary case with Leriche syndrome and the reconstructive procedure is presented. Although the patient died on the postoperative day 10, the reconstructive surgical procedure was successful and the wound healing was uneventful.

FATİH ZOR, MD
DEPARTMENT OF PLASTIC AND
RECONSTRUCTIVE SURGERY,
GULHANE MILITARY MEDICAL SCHOOL,
06018, ETLİK ANKARA, TURKEY
Tel: 0 312 304 54 13
Fax: 0 312 304 54 12
e-mail: fatihzor@yahoo.com

REFERENCES

1. Carman TL, Fernandez BB Jr. A primary care approach to the patient with claudication. *Am Fam Physician* 2000; 61(4):1027-1032
2. Santilli JD, Santilli SM. Chronic critical limb ischemia: Diagnosis, treatment and prognosis. *Am Fam Physician* 1999; 59(7):1899-1908
3. Vogt FM, Goyen M, Debatin JF. Modern diagnostic concepts in dissection and aortic occlusion. *Radiologe* 2001; 41 (8):640-652
4. Furrer M, Schuler M, Leutenegger AF, Ruedi T. Acute Leriche syndrome in a previously healthy woman: Differential diagnosis of embolic occlusion. *Helv Chir Acta*. 1994; 60(6): 887-891
5. Genoni M, von Segesser LK, Laske A, Carrel T, Schonbeck M, Niederhauser U, Vogt P, Turina M. Occlusion of the distal aorta. *Helv Chir Acta*.1994; 60(5): 723-728
6. Julsrud ME. Leriche's syndrome. *J Am Podiatr Med Assoc* 1992; 82(4):196-201
7. Duff C, Simmen HP, Brunner U, Bauer E, Turina M. Gluteal necrosis after acute ischemia of the internal iliac arteries. *Vasa* 1990; 19(3):252-256
8. Elsharawy MA, Cheatle TR. Buttock claudication secondary to isolated internal iliac artery stenosis. *Eur J Vasc Endovasc Surg* 2000; 19(1):87-9