

CASE REPORT

## Ectopic thyroid and Hashimoto's thyroiditis arising from a thyroglossal duct cyst: a case report

Tiroglossal duktus kistinde ektopik tiroidit ve Hashimoto tiroiditi: Olgu sunumu

Üzeyir GÖK, M.D.,<sup>1</sup> Erol KELEŞ, M.D.,<sup>1</sup> Bengü ÇOBANOĞLU, M.D.,<sup>2</sup> Mücahit YILDIZ, M.D.,<sup>1</sup> Emir DÖNDER, M.D.<sup>3</sup>

A seventy-five-year-old male patient presented with a palpable smooth mass that moved upwards on swallowing, extending from the hyoid bone to the cricoid cartilage. Ultrasonography, scintigraphy, and thyroid hormone measurements showed the mass free from the thyroid gland. Following a diagnosis of infected thyroglossal duct cyst by fine needle aspiration biopsy, the mass was removed by surgery. Histopathologic diagnosis was Hashimoto's thyroiditis that developed from the ectopic thyroid tissue on the wall of thyroglossal duct cyst.

**Key Words:** Biopsy, needle; thyroglossal cyst/pathology/surgery; thyroid gland/pathology; thyroiditis, autoimmune/pathology/complications/surgery.

Yetmiş beş yaşında erkek hasta, boyun orta hattında, hyoid kemiğinden krikoid kartilaja kadar uzanan ve yutkunmakla yukarıya hareket eden kitle şikayetiyle başvurdu. Ultrasonografi, sintigrafi, ve tiroit hormon incelemeleri kitlenin tiroit dokusundan bağımsız olduğunu gösterdi. İnce iğne aspirasyon biyopsisi ile enfekte tiroglossal duktus kisti öntanısı kondu ve kitle ameliyatla çıkarıldı. Histopatolojik tanısı, tiroglossal duktus kisti duvarında ektopik tiroit dokusundan gelişen Hashimoto tiroiditi şeklinde belirlendi.

**Anahtar Sözcükler:** Biyopsi, iğne; tiroglossal duktus kisti/patoloji/cerrahi; tiroit bezi/patoloji; tiroidit, otoimmün/patoloji/komplikasyon/cerrahi.

Thyroglossal duct cysts and fistulas may occur at any place from the foramen cecum at the base of the tongue to the incisura angularis of the sternum. A palpable mass located in the midline of the neck, cranial to the isthmus of the thyroid gland, especially that moves upwards upon swallowing, is usually a thyroglossal duct cyst.<sup>[1]</sup> It is usually found in front of, or beneath, the hyoid bone as an asymptomatic mass. On its wall, there may be mucous glands and ectopic thyroid tissue. Similarly, ectopic thyroid tissue may be found at any place from the foramen cecum at the

base of the tongue to the pyramidal lobe of the thyroid.<sup>[2]</sup> This developmental abnormality is frequently encountered in childhood during the first five years of life, but may also be detected in adults.<sup>[3,4]</sup> Cysts presenting with intralingual or suprahyoid localizations may be associated with dysphagia, hoarseness, and altered voice.<sup>[5,6]</sup>

Hashimoto's thyroiditis is an autoimmune disorder frequently seen in females.<sup>[7]</sup> Although it usually has an insignificant clinical course, symptoms of hypothyroidism may be the initial manifestations in

◆ Departments of <sup>1</sup>Otolaryngology, <sup>2</sup>Pathology, and <sup>3</sup>Endocrinology, Medicine Faculty of Fırat University, Elazığ, Turkey.

◆ Received: April 18, 2002. Request for revision: August 29, 2002. Accepted for publication: October 5, 2002.

◆ Correspondence: Dr. Üzeyir Gök. Fırat Üniversitesi, Fırat Tıp Merkezi KBB Hastalıkları Kliniği, 23119 Elazığ, Turkey.  
Tel: +90 424 - 233 35 55 Fax: +90 424 - 238 80 96  
e-mail: uzeyirgok@yahoo.com

◆ Fırat Üniversitesi Tıp Fakültesi, <sup>1</sup>Kulak Burun Boğaz Hastalıkları Anabilim Dalı, <sup>2</sup>Patoloji Anabilim Dalı, <sup>3</sup>Dahiliye (Endokrinoloji) Anabilim Dalı, Elazığ.

◆ Dergiye geliş tarihi: 18 Nisan 2002. Düzeltme isteği: 29 Ağustos 2002. Yayın için kabul tarihi: 5 Ekim 2002.

◆ İletişim adresi: Dr. Üzeyir Gök. Fırat Üniversitesi, Fırat Tıp Merkezi KBB Hastalıkları Kliniği, 23119 Elazığ.  
Tel: 0424 - 233 35 55 Faks: 0424 - 238 80 96  
e-posta: uzeyirgok@yahoo.com

approximately 20% of patients, of which only 5% may have hyperthyroidism. Most commonly diffuse goiter and lobular goiter may be found on physical examination; on rare occasions, only one nodule is detected.<sup>[1,7]</sup>

In this report, we present a case of Hashimoto's thyroiditis originating from the thyroid tissue on the wall of a thyroglossal duct cyst. Interestingly, the thyroid gland was found normal at its usual location.

### CASE REPORT

A seventy-five-year-old male patient was referred to our outpatient clinic in January, 2001. He described a small mass in the middle of his neck for the past 10 years, which enlarged with upper respiratory tract infections and returned to its original size following recovery from the infection. However, there had been a progressive enlargement of the mass after the last infection. Physical examination showed a palpable smooth mass (6x5x4 cm in size) of rubber-like consistency, that moved upwards on swallowing. It extended from the hyoid bone to the cricoid cartilage (Fig. 1). Hemoglobin, hematocrit, and the erythrocyte sedimentation rate were measured as 16.2 gr/dl, 46.7%, and 10 mm/h, respectively. There were no clinical or laboratory signs suggesting hypo- or hyperthyroidism. Serum levels of total T4, free T3, free T4, and TSH were within normal ranges. Serum antithyroid microsomal antibody (240 U/ml) and antithyroglobulin antibody (200 U/ml) titers were significantly increased. Ultrasonographic examination revealed a mass in the midline of the neck with cystic and solid structures. The thyroid gland appeared normal. The mass was completely free from the thyroid gland. Scintigraphy with Tc 99m (3mCi) showed a normal thyroid gland, but an increased uptake of the cystic mass suggesting ectopic thyroid tissue. Fine-needle aspiration biopsy was performed. Cytological examination showed leukocytes and necrotic cells which were small and dysplastic. The number of leukocytes was significantly increased and inflammation was prominent. Histopathologic diagnosis was made as thyroglossal duct cyst.

Total extirpation of the mass was planned. Intraoperatively, the mass was dissected from the surrounding tissues. The thyroid gland was intact; the cyst was attached to the corpus of the hyoid bone and had a ductus extending to the base of the tongue. The corpus of the hyoid bone was removed and the duc-

tus was dissected. The mass was removed after placing a bag suture (Fig. 2).

Histopathologic examination of the specimen showed a thin capsule formed by a layer of cubic epithelium. Below this capsule were thyroid follicles. There were scattered lymphoid follicles with germinal centers consisting of Hurthle cells (Fig. 3). A diagnosis of Hashimoto's thyroiditis was made, which developed from the ectopic thyroid tissue on the wall of thyroglossal duct cyst.

Serum antithyroid microsomal antibody and antithyroglobulin antibody titers fell within normal ranges postoperatively.

### DISCUSSION

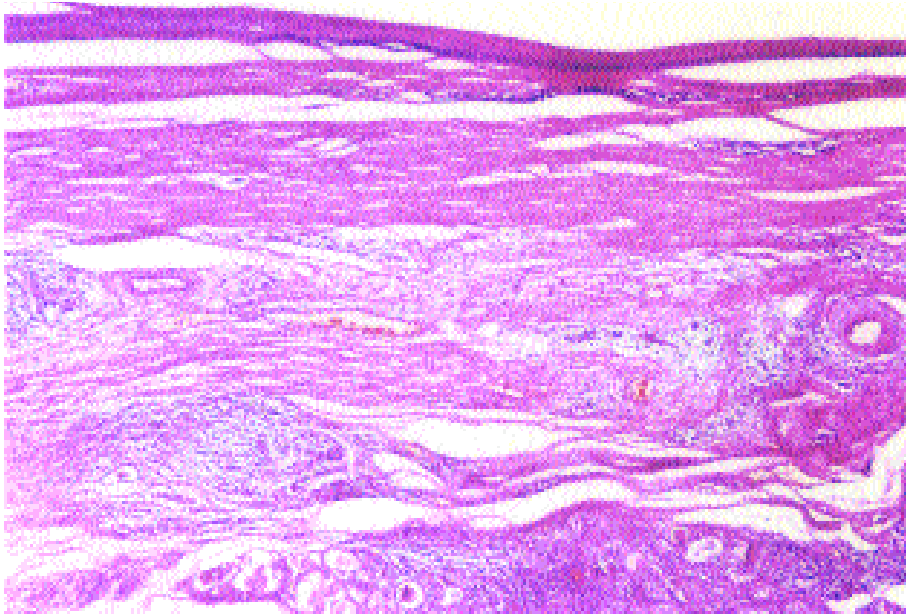
Thyroglossal duct cysts are usually found adjoining the hyoid bone (75%) as asymptomatic masses.<sup>[5]</sup> If the foramen cecum is patent, then fluid or inflam-

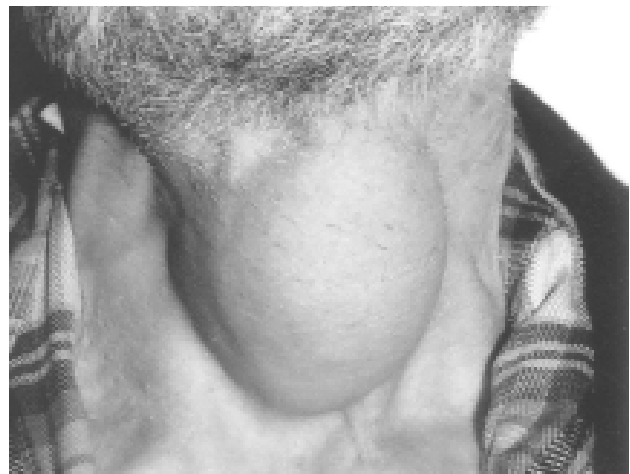

Fig. 1 - Preoperative appearance of the mass.

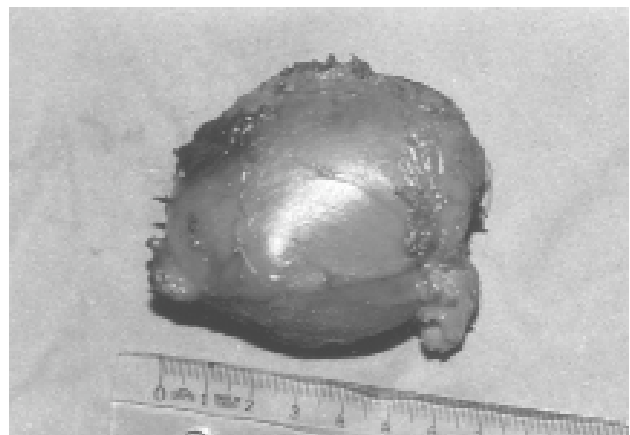

Fig. 2 - The appearance of the mass after surgical removal.



*Fig. 3 - Lymphoid follicles with active germinal center, accumulated Hurthle cells on the surface of the thyroglossal duct wall, and thyroid tissue beneath the wall (H-E x 4).*

matory cells in the cyst gain access to the oropharynx. Infection is associated with 50% of these cysts, being the main reason for patient presentation.<sup>[8]</sup> An infected thyroglossal duct cyst was also considered in the initial diagnosis of our patient with a swollen mass in the midline of the neck, moving upwards on swallowing. Differential diagnosis should include pyramidal lobe of the thyroid gland, thyroid adenoma, aberrant thyroid tissue, branchial cyst, lipoma, dermoid cyst, and hemangioma.<sup>[9,10]</sup>

Hashimoto's thyroiditis is an autoimmune disorder and a diffuse disease of the thyroid gland. It presents as a chronic inflammatory disease of the thyroid in which cytotoxic T-lymphocytes and antithyroid antibodies play a prominent role.<sup>[7,11]</sup> Clinical findings are not significant in many patients. In our case, the patient was euthyroid and clinical findings were not remarkable.

The hallmark of the disease is increased antithyroglobulin antibody and antithyroid microsomal antibody levels in the serum, which are detected in approximately 90% to 100% of patients with Hashimoto's thyroiditis.<sup>[7,11]</sup> In our case, a substantial increase in these antibodies were detected.

Ectopic thyroid tissue may be found anywhere along the embryologic thyroglossal duct. Our literature search revealed two cases of Hashimoto's thyroiditis that developed from the ectopic thyroid tissue

of the thyroglossal duct cyst.<sup>[1]</sup> In our patient, physical examination and scintigraphy of the thyroid gland were normal. However, increased uptake by the cystic mass indicated the presence of an ectopic thyroid tissue of the thyroglossal duct cyst.

Although rare, thyroid tissues on the wall of thyroglossal duct may lead to malignant transformation of thyroglossal duct cysts.<sup>[4,12,13]</sup> Considering the patient's age and rapid enlargement of the lesion, a diagnosis of thyroglossal duct carcinoma was also included in the differential diagnosis.

In conclusion, in the presence of a thyroglossal duct cyst, symptoms, findings, and laboratory parameters may indicate Hashimoto's thyroiditis.

#### REFERENCES

1. Nootboom GC, van der Vijver JC. A thyroglossal duct node as presenting symptom of Hashimoto's thyroiditis: a report of two cases. *Neth J Med* 1992;40:23-6.
2. Henry JF. Surgical anatomy and embryology of the thyroid and parathyroid glands and recurrent and external laryngeal nerves. In: Clark OH, Duh QY, editors. *Textbook of endocrine surgery*. 1st ed. Philadelphia: W.B Saunders; 1997. p. 8-14.
3. Katz AD, Hachigian M. Thyroglossal duct cysts. A thirty year experience with emphasis on occurrence in older patients. *Am J Surg* 1988;155:741-4.
4. Fernandez JF, Ordonez NG, Schultz PN, Samaan NA, Hickey RC. Thyroglossal duct carcinoma. *Surgery* 1991; 110:928-35.
5. Allard RH. The thyroglossal cyst. *Head Neck Surg* 1982; 5:134-6.

6. Bilgen C, Kirazli T, Kesimli H, Yavuzer A. Lingual troide transhyoid yaklaşım. Kulak Burun Bogaz İhtis Derg 2001;8:238-41.
7. Lida F, Sugeno A. Thyroiditis: Acute, subacute, Hashimoto's and Riedel's. Textbook of endocrine surgery. 1st ed. Philadelphia: W.B Saunders; 1997. p. 33-8.
8. Bennett KG, Organ CH Jr, Williams GR. Is the treatment for thyroglossal duct cysts too extensive? Am J Surg 1986;152:602-5.
9. Knight PJ, Hamoudi AB, Vassy LE. The diagnosis and treatment of midline neck masses in children. Surgery 1983;93:603-11.
10. Özünlü A, Önder T, Köse T, Dündar A. Ektopik tiroid dokusu (iki olgu nedeniyle). KBB Bülteni 1995;2:85-7.
11. Singer PA. Thyroiditis. Acute, subacute, and chronic. Med Clin North Am 1991;75:61-77.
12. Prasad ML, Rangaswamy M, Kumar N, Shukla NK. Papillary carcinoma of a thyroglossal duct remnant with Hashimoto's thyroiditis. Ear Nose Throat J 1990; 69:358-60.
13. Yıldız K, Köksal H, Özoran Y, Muhtar H, Telatar M. Papillary carcinoma in a thyroglossal duct remnant with normal thyroid gland. J Laryngol Otol 1993;107: 1174-6.