

CASE REPORT

Nasal septal cyst: a case report

Nazal septal kist: Olgu sunumu

Hakan CINCIK, M.D.,¹ Atila GÜNGÖR, M.D.,¹ Hakan MUTLU, M.D.,² Engin ÇEKİN, M.D.¹

Nasal septal cyst is a rare complication seen after submucous resection of the nasal septum. A 25-year-old male patient presented with a complaint of nasal obstruction four years after submucous resection. Physical examination revealed a grey mass obstructing both nasal cavities and the nasal airway. Magnetic resonance imaging showed a nasal septal cyst filling the nasal cavity. Following aspiration of the cyst content, endoscopic examination was performed and perforation of the lower part of the nasal septum was noted. Under local anesthesia, superior, posterior, and anterior parts of the cyst and the left wall of the septum were endoscopically released and prepared to be used as a flap. It was sutured on the lower part of the septal perforation. No recurrence was seen during a follow-up of 18 months.

Key Words: Nasal septum; cyst; submucous resection; nasal obstruction.

Nazal septal kist, submuköz rezeksiyon ameliyatı sonrası nadir görülen bir komplikasyondur. Dört yıl önce submuköz rezeksiyon ameliyatı geçiren 25 yaşında erkek hasta, burunda tıkanıklık yakınmasıyla başvurdu. Fizik muayenesinde her iki nazal kavite ve hava yolunu tıkayan gri renkli kitle görüldü. Manyetik rezonans görüntüleme nazal kaviteyi dolduran nazal septal kist saptandı. Öncelikle kist içeriği aspire edilerek endoskopik muayene yapıldı ve septumun alt kısmında perforasyon olduğu görüldü. Lokal anesteziyle, endoskopik olarak kistin ve septumun sol duvarı ön, arka ve üstten kesilerek serbestleştirildi ve flep olarak hazırlanarak septal perforasyonun alt kısmına dikildi. Hastanın 18 aylık izlemi sırasında kist rekürrensi gözlenmedi.

Anahtar Sözcükler: Nazal septum; kist; submuköz rezeksiyon; nazal obstrüksiyon.

Deformity of the nasal septum occurs in more than 20% of the population and contributes to restricted nasal airflow in 25% of these individuals.^[1] In the early 1900s, Freer and Killian independently popularized the practice of submucous resection (SMR).^[2] Septal surgery is still being performed regularly in rhinology practice. The usual complica-

tions of SMR are septal hematoma, septal abscess, infection, epistaxis, septal perforation and nasoseptal deformity.^[3]

Nasal septal cyst (NSC) is a rare complication of SMR.^[4] There is a limited knowledge about NSC in the literature. In this report we present a case with NSC four years after SMR.

◆ Departments of ¹Otolaryngology and ²Radiology, Gülhane Military Medical School Haydarpaşa Training Hospital (GATA Haydarpaşa Eğitim Hastanesi) Kulak Burun Boğaz Hastalıkları Kliniği, ²Radyoloji Kliniği), İstanbul, Turkey.

◆ Received - May 26, 2004 (Dergiye geliş tarihi - 26 Mayıs 2004). Request for revision - July 29, 2004 (Düzeltilme isteği - 29 Temmuz 2004). Accepted for publication - November 24, 2005 (Yayın için kabul tarihi - 24 Ekim 2005).

◆ Correspondence (İletişim adresi): Dr. Hakan Cıncık. GATA Haydarpaşa Eğitim Hastanesi Kulak Burun Boğaz Hastalıkları Kliniği, 34668 İstanbul, Turkey. Tel: +90 216 - 542 25 96 Fax (Faks): +90 216 - 348 78 80 e-mail (e-posta): hcincik@ttnet.net.tr

CASE REPORT

A 25 years old male was admitted to our clinic with a complaint of bilateral nasal obstruction. History revealed that the patient underwent SMR operation in a medical center four years ago. He mentioned that an anterior nasal packing was inserted into both of his nasal cavities and kept for 48 hours. Epistaxis occurred two days after taking out nasal packing. The patient was managed again with anterior nasal packing. His nasal obstruction developed gradually.

Rhinologic examination revealed saddle nose deformity and a grey mass completely obstructing both nasal cavities and the nasal airway. MRI revealed a 4x4x3 cm mass with low signal intensity on T1-weighted images and high signal intensity on T2-weighted images similar to fluid density and compatible with large nasal septal cyst. The cyst filled the entire anterior nasal cavity and expanded on middle, inferior turbinates and ethmoid sinus. The cyst had straight border, homogeneous dense content and 4x4x3 cm in size (Fig. 1a-c). Needle aspiration of 20 ml brown mucoid material was performed to reduce the pressure of the cyst and allow diagnostic endoscopy. Endoscopy revealed nasal septal perforation involving lower part of the septum. Routine bacteriologic cultures were negative.

Under local anesthesia, a left-sided Killian-type mucosal incision was made and the remaining mucoid content was evacuated. The septal cartilage had been resorbed completely. Anterior, superior and posterior portions of the left septum and adjacent cyst wall were freed and turned down. It was trimmed and sutured on the lower part of the septal perforation. We did not dissect between septum and cyst due to severe adhesion and very thin wall. Anterior nasal pack was not inserted because bleeding did not occur. Histopathologic examination revealed a cyst wall lined with respiratory epithelium.

Endoscopic examination revealed closed septal perforation and no cyst recurrence after eighteen months. There was only a synechia between the nasal septum and the right inferior turbinate. We incised the synechia and placed silicon sheet between them. Computed tomography (CT) scan (Fig. 2) demonstrated no recurrence. We recommended a rhinoplasty operation for treatment of saddle nose deformity but the patient did not want to another operation.

DISCUSSION

In rhinology practice, postoperative cystic complications are rare including nasal dorsal cyst after

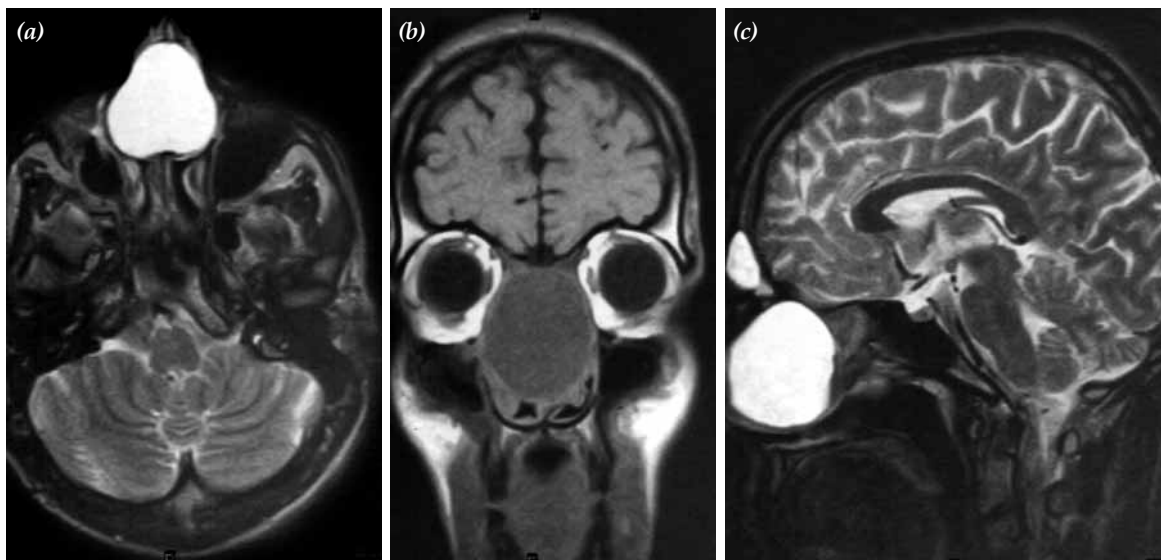


Fig. 1 - MR images in a 25-year-old patient who had large nasal septal cyst. (a) Axial T2-weighted turbo spin-echo MR image shows hyperintense signal in the nasal septum. (b) Coronal T1-weighted spin-echo MR image shows hypointense signal in the nasal septum. The nasal cavity completely filled up with cyst and expanded on turbinates and ethmoid sinus. (c) Sagittal T2-weighted turbo spin-echo shows hyperintense signal in the nasal septum. The cyst has straight border, homogeneous content and 4x4x3 cm in size.

rhinoplasty,^[5-7] maxillary cheek cyst after surgical intervention in the maxillary sinus^[8] and nasal septal cyst after SMR.^[4]

Nasal dorsal cyst formation is a rare complication. These cysts are due to entrapment of mucosal remnants in the subcutaneous space and appear several days to several years after rhinoplasty. McGregor et al.,^[9] theorized these cysts were caused by herniation of the nasal mucosa when the patient blew her nose. The cause of the complication is unknown; however, entrapment of nasal mucosa and subsequent growth through osteotomy sites and then an accumulation of secretion are thought to be the basis for formation of these masses.^[5,6]

Chiang et al.,^[4] believe that formation of the dorsal nasal cyst is similar to that of NSC. The NSC is probably caused by entrapment of free nasal mucosal remnants or inward folding of septal nasal mucosa during SMR. They explain that with two theories why the cyst could not cause any symptoms until 20 years after SMR. The first suggestion is that chronic rhinitis may stimulate the mucosal epithelium of postoperative septal space to undergo cystic degeneration. The second possibility is that blocked septal mucosa may go on making secretion and subsequently slowly accumulation of this causes cyst formation and expansion.

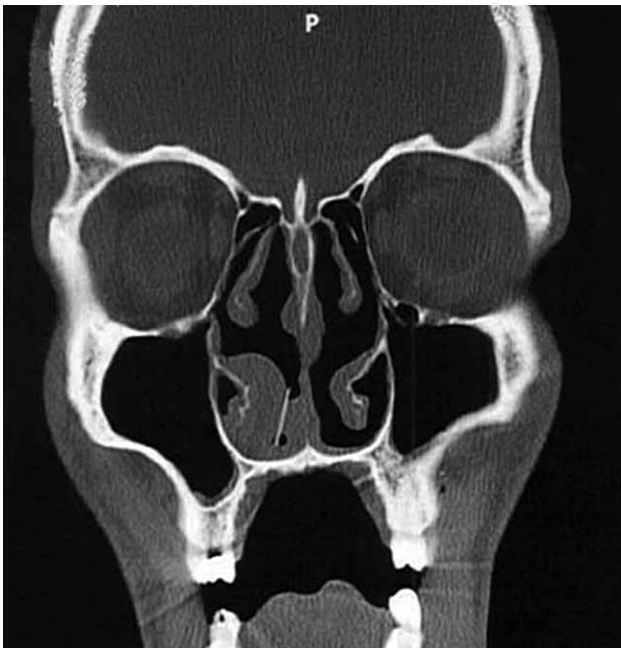

Fig. 2 - CT image, postoperative appearance, 18 months later.

Chiang et al.,^[4] believe that characteristic of NSC is also similar to that of cheek cyst.^[4] Postoperative maxillary cheek cyst develops as a delayed complication many years after surgical intervention in the maxillary sinus. Kaneshiro et al.^[8] reported 71 such cysts. The cysts occurred most frequently ten to 30 years after radical operations. The most common symptoms were swelling or pain of the cheek and the mucogingival fold of the maxilla. Most of them had a thin wall, lined with ciliated columnar epithelium.

Complications associated with septal surgery may originate in incomplete analysis of the anatomical structures of the nose and nasal function tests. Complications can arise from technical failures during the procedures of septal surgery starting from the incision to the reconstruction of the septum. Classical complications can be caused by infections in the postoperative period. Postoperative and late complications may also arise from damage to the septal soft and hard tissues. Septal surgery complications may often interfere with nasal function and cosmetics, but sometimes affect general health.^[10]

In our case, the cyst obstructed both nasal cavities and expanded to the middle and inferior turbinates and ethmoid sinus gradually in 4 years. Walls of the septal cyst were lined with respiratory ciliated columnar epithelium. Septum had a perforation under the cyst. Septal perforation may have probably occurred because free mucosa in the inferior part of the septum folded inward. These findings support the theory that cyst was caused by folding of septal mucosa inward and continued secretion.

Nasal septal abscess, nasal polyposis, septal mucocel, Schwannoma and pleomorphic adenoma of the nasal septum should be considered for the differential diagnosis. A computed tomography scan clearly depicts the relationship of the lesion to the surrounding bony structures; erosion is more common with large mass of septum. Magnetic resonance imaging (MR) is superior to CT in differentiating a tumor from inflammatory changes and normal tissues; furthermore, intracranial extension can be better delineated.^[11] The cyst is clearly differentiated from other pathologies by the CT; therefore, MR would not have added any information relevant to the therapeutic planning. In our case we used MR because we thought it was a solid mass.

Chiang et al.^[4] reported that these cysts may be treated with lateral rhinotomy to achieve a better exposure of the nasal septum than the endonasal approach due to severe adhesion between cyst and septum mucosa and avoidance of septal perforation.^[4]

Because of the patient had the septal perforation and the cosmetic deformity, we preferred endonasal surgery with endoscopy; therefore, we did not want to make another scar on patient's face. We repaired septal perforation with septum mucosa together with adjacent cyst wall. Thus, a scar of lateral rhinotomy was prevented and septal perforation was closed.

Septal surgery is a common procedure nowadays. In order to prevent its complications, the operation decision should be given after complete analysis of the anatomical structures of the nose and nasal function. Furthermore, procedures of septal surgery should be performed appropriately. To avoid NSC, mucosal lining should be kept intact. The incised or free septal mucosa should be sutured end-to-end or be prevented folding inward. All free mucosal remnants, blood clot and necrotic tissue must be removed. Patients should be followed regularly to avoid cosmetic deformity such as saddle nose.

REFERENCES

1. Blaugrund SM. Nasal obstruction. The nasal septum and concha bullosa. *Otolaryngol Clin North Am* 1989;22:291-306.
2. Brain D. The nasal septum. In: Mackay IS, Bull TR, editors. *Scott-brown's otolaryngology*. Vol 4. 6th ed. Boston: Butterworth-Heinemann; 1997. p. 11, 1-27.
3. Low WK, Willatt DJ. Submucous resection for deviated nasal septum: a critical appraisal. *Singapore Med J* 1992;33:617-9.
4. Chiang CH, Juan KH, Kuo WR, Tai CF, Wu JR. Nasal septal cyst--a case report. *Kaohsiung J Med Sci* 1996;12:256-9.
5. Harley EH, Erdman JP. Dorsal nasal cyst formation. A rare complication of cosmetic rhinoplasty. *Arch Otolaryngol Head Neck Surg* 1990;116:105-6.
6. Zijlker TD, Vuyk HD. Nasal dorsal cyst after rhinoplasty. *Rhinology* 1993;31:89-91.
7. Kotzur A, Gubisch W. Mucous cyst--a postrhinoplasty complication: outcome and prevention. *Plast Reconstr Surg* 1997;100:520-4.
8. Kaneshiro S, Nakajima T, Yoshikawa Y, Iwasaki H, Tokiwa N. The postoperative maxillary cyst: report of 71 cases. *J Oral Surg* 1981;39:191-8.
9. McGregor MW, O'Connor GB, Saffier S. Complications of rhinoplasty. I. Skin and subcutaneous tissues. *J Int Coll Surg* 1958;30:179-85.
10. Schwab JA, Pirsig W. Complications of septal surgery. *Facial Plast Surg* 1997;13:3-14.
11. Dublin AB, Dedo HH, Bridger WH. Intranasal schwannoma: magnetic resonance and computed tomography appearance. *Am J Otolaryngol* 1995;16:251-4.