

CASE REPORT

An unusual foreign body: a ball bearing in the posterior ethmoid sinus

Posterior etmoid sinüste alışılmadık bir yabancı cisim: Bilye

Arif ŞANLI, M.D., Mehmet EKEN, M.D., Sedat AYDIN, M.D., Ömer TAŞDEMİR, M.D.

Globe perforation was detected in an 18-year-old male patient having total vision loss in the left eye following a car accident. The middle meatus could not be evaluated by sinonasal endoscopy because of edema. Computed tomography showed a foreign body in the left posterior ethmoid sinus, with a trajectory coursing from the globe to the lamina papyracea, and the posterior ethmoid sinus. Endoscopic sinus surgery was performed including a left uncinectomy, anterior and posterior ethmoidectomies, and the foreign body was removed from the posterior ethmoid sinus using an ethmoid forceps. It turned out to be a ball bearing. After three months of follow-up, the patient had no evidence for rhinologic sequelae.

Key Words: Endoscopy; ethmoid sinus; foreign body.

Araç dışı trafik kazası nedeniyle sol gözünde görmede total kayıp olan 18 yaşındaki erkek hastada glob perforasyonu saptandı. Sinonazal endoskopide ödem nedeniyle orta meatus değerlendirilemedi. Bilgisayarlı tomografide sol posterior etmoid sinüste yabancı cisim görüldü. Yabancı cismin yolunun glob, lamina paprisea ve posterior etmoid sinüs olduğu izlendi. Endoskopik sinüs cerrahisinde sol unsinektomi sonrasında anterior ve posterior etmoidektomi yapıldı. Sol posterior etmoid sinüsteki yabancı cisim forseps yardımıyla çıkartıldı. Cismin arabalardaki rulmanların bilyelerinden olduğu anlaşıldı. Yapılan üç aylık kontrolde rinolojik herhangi bir sekel bulunmadı.

Anahtar Sözcükler: Endoskopi; etmoid sinüs; yabancı cisim.

Penetrating facial injuries are not infrequent. The maxillary and ethmoidal sinuses and orbita are particularly at risk.^[1] Although foreign bodies in the ethmoid and sphenoid sinuses are rare, bullets, and metals penetrate through the medial canthus or through the orbit.^[2,3] However; there is no report of a ball bearing as a transorbital foreign body lodged in the posterior ethmoid sinuses in the literature. We describe an unusual case of an adult who suffered an external orbital injury from a ball bearing that penetrated the orbit, lamina papyracea and posterior eth-

moid sinuses after a car accident. Endoscopic sinus surgery was performed to extract the ball bearing after localization with computed tomography (CT).

CASE REPORT

An 18-year-old male patient was referred to our center following a car accident. On presentation, he reported no light perception in the left eye and complained of a slight headache. He reported brief epistaxis at the time of injury, but denied clear rhinorrhea. On physical examination, he was otherwise

◆ Department of Otolaryngology (2nd), Kartal Training and Research Hospital (Kartal Eğitim ve Araştırma Hastanesi 2. Kulak Burun Boğaz Hastalıkları Kliniği), İstanbul, Turkey.

◆ Received - February 28, 2005 (Dergiye geliş tarihi - 28 Şubat 2005). Request for revision - October 18, 2005 (Düzeltilme isteği - 18 Ekim 2005). Accepted for publication - January 1, 2006 (Yayın için kabul tarihi - 1 Ocak 2006).

◆ Correspondence (İletişim adresi): Dr. Mehmet Eken. Üsküdar Cad., Konak Apt., No: 39/11 34862 Kartal, İstanbul, Turkey.
Tel: +90 216 - 389 65 64 Fax (Faks): +90 216 - 575 34 68 e-mail (e-posta): memedeken@yahoo.com

neurologically intact. Sinonasal endoscopy revealed moderate edema of the middle meatus but no purulence and no evidence of cerebrospinal fluid leak. We didn't see foreign body because of edema. A computed tomography scan demonstrated the foreign body lodged in the left posterior ethmoid sinuses (Fig. 1). The trajectory of the foreign body was identified coursing through the globe, lamina papyracea, and posterior ethmoid sinuses. He was taken to the operating room for repair of the perforated globe by the ophthalmologists. Three weeks later, endoscopic sinus surgery including a left uncinectomy, anterior and posterior ethmoidectomies were performed and the foreign body was removed from the posterior ethmoid sinuses with ethmoid forceps (Fig. 2). The patient tolerated the procedure well and was discharged two weeks after the procedure. After three months of follow-up, the patient had no evidence of rhinologic sequelae.

DISCUSSION

In evaluating craniofacial foreign bodies, it is prudent to consider the potential for an airway emergency, as well as associated ophthalmologic, vascular, cranial nerve and intracranial injuries. After stabilizing the patient and establishing that the foreign body does not reside in the upper airway, ophthalmologic consultation is obtained when there is risk to the orbit. Neurosurgical consultation is sought for a cerebrospinal fluid leak or obvious intracranial involvement. In the present case, globe perforation was obtained after the ophthalmologic consultation and the patient underwent operation for repairing the globe.

Computed tomography examination should be performed before surgery to evaluate the spatial relationship between foreign bodies and surrounding organs and the severity of tissue damage.^[4,5] In our case, the CT scan demonstrated the perforated globe and the ball bearing lodged in the left posterior ethmoid sinuses.

With the advent of endoscopic surgery, removal endoscopically has become the approach of choice for the majority of cases of sinus foreign bodies.^[3,6,7] Endoscopy allows for better evaluation of the size and location of the foreign body as well as relation to adjacent structures. It is important to achieve control of the structures surrounding the object prior to its removal. We also used an endoscopic approach while removing the ball bearing.

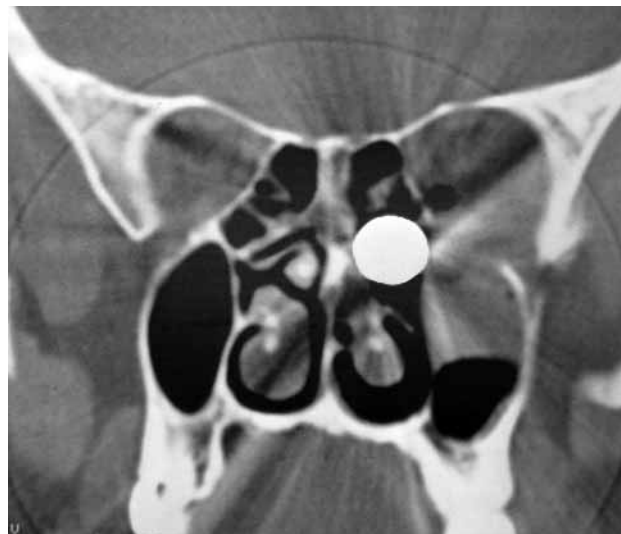

Fig. 1 - Coronal computed tomography scan showing the round foreign body in the left posterior ethmoidal sinuses.




Fig. 2 - The ball bearing after removal.

In conclusion, ophthalmologic and neurosurgical consultations should be done after a craniofacial foreign body injury. The location of most foreign bodies is best evaluated by a CT scan. Endoscopic techniques are the preferred methods of removal in most cases.

REFERENCES

1. Lee D, Nash M, Turk J, Har-El G. Low-velocity gunshot wounds to the paranasal sinuses. *Otolaryngol Head Neck Surg* 1997;116:372-8.
2. Mladina R. Endoscopic sinus surgery: a metallic foreign body at the sphenothmoidal junction. *J Laryngol Otol* 1992;106:998-9.
3. Dimitriou C, Karavelis A, Triaridis K, Antoniadis C.

An unusual foreign body: a ball bearing in the posterior ethmoid sinus

- Foreign body in the sphenoid sinus. *J Craniomaxillofac Surg* 1992;20:228-9.
4. Fallon MJ, Plante DM, Brown LW. Wooden transnasal intracranial penetration: an unusual presentation. *J Emerg Med* 1992;10:439-43.
 5. Rawlinson JN, Russell T, Coakham HB, Byrnes DP. Transnasal hypophysectomy-an unusual sporting injury. *Surg Neurol* 1988;30:311-5.
 6. Bhattacharyya N, Wenokur RK. Endoscopic management of a chronic ethmoid and sphenoid sinus foreign body. *Otolaryngol Head Neck Surg* 1998;118:687-90.
 7. Connolly AA, White P. How I do it: transantral endoscopic removal of maxillary sinus foreign body. *J Otolaryngol* 1995;24:73-4.