

A “Modified-flying wing” procedure for the treatment of saddle nose and supratip pathologies

Semer burun ve supratip deformitelerinin tedavisinde “Modifiye uçan kanat” yönteminin kullanılması

Hülida Rifat Özakpınar, M.D.,¹ Serdar Gökrem, M.D.²

¹Department of Plastic and Reconstructive Surgery, Dışkapı Yıldırım Beyazıt Training and Research Hospital, Ankara, Turkey;

²Department of Plastic and Reconstructive Surgery, Ankara Training and Research Hospital, Ankara, Turkey

Objectives: In this report, we present the usage of a “modified flying wing” procedure for different indications such as correction of primary supratip depression and saddle nose deformity due to prior septal surgery or prior trauma, and also for prevention of possible supratip deformity.

Patients and Methods: Between April 2004 and January 2008, the “modified flying wing” procedure was used in a total of 11 patients; for the correction of primary supratip depression deformities in three patients, for the saddle nose deformities due to prior trauma or septal surgery in four patients, and for the prevention of future supratip deformity in four patients (3 males, 8 females; mean age 25.3 years; range 19 to 35 years). The “modified-flying wing” procedure was performed as described by Jugo. Hump removal and medial or lateral osteotomy were considered based on patient status. In all patients a symmetric, balanced nose was achieved with an adequately projected tip and an esthetically satisfactory dorsum extending from the brows to the tip of the nose. No patient required a secondary rhinoplasty.

Results: In all patients the postoperative periods were without any complication and the long-term results were satisfactory.

Conclusion: Using a “modified flying wing” procedure for the correction of saddle nose deformity avoids some disadvantages of autografts, such as the tendency of the autograft to warp and curl. Use of this procedure for primary rhinoplasty patients with a risk of developing future supratip deformity prevents this deformity. This combination approach in selected primary rhinoplasty cases provides an esthetically pleasing nose while preventing some complications of classical reduction rhinoplasty. We performed this procedure in 11 patients with good long-term functional and esthetic results.

Key Words: Nasal tip surgery; rhinoplasty; seadle nose; supratip deformity.

Amaç: Bu çalışmada “modifiye uçan kanat” işleminin, olası supratip deformitelerinin önlenmesi ve birincil supratip deformitesinin düzeltilmesi veya daha önce geçirilmiş septoplasti ameliyatı nedeni ile ya da travma sonrası oluşan semer burun deformiteleri gibi farklı endikasyonlarla kullanımı sunuldu.

Hastalar ve Yöntemler: Nisan 2004 - Ocak 2008 tarihleri arasında primer supratip deformitesinin önlenmesi için üç hastada, geçirilmiş travma ya da septal cerrahi kaynaklı semer burun deformiteleri için dört hastada ve supratip deformitesinin önlenmesi için dört hastada olmak üzere toplam 11 hastada (3 erkek, 8 kadın; ort. yaş 25.3 yıl; dağılım 19-35 yıl) “modifiye uçan kanat” yöntemi uygulandı. “Modifiye uçan kanat” işlemi Jugo’nun tanımladığı şekilde uygulandı. Hastaların durumuna göre hump rezeksiyonu ve mediyal ya da lateral osteotomi uygulandı. Bütün hastalarda yeterli şekilde burun ucu ve kaşlardan burun ucuna kadar estetik açıdan tatmin edici bir burun sırtıyla simetrik ve dengeli bir burun elde edildi. Hiçbir hastada ikinci bir rinoplasti gerçekleştirilmesi gerekmedi.

Bulgular: Bütün hastalarımızın ameliyat sonrası dönemi komplikasyonsuz ve uzun dönem takiplerinde sonuçlar tatmin edici idi.

Sonuç: Semer burun deformitesinin düzeltilmesinde “modifiye uçan kanat” tekniği kullanılması otogreftlere ilişkin, otogreftlerde eğrilme ve bükülme meydana gelmesi eğilimi gibi, dezavantajları ortadan kaldırır. Bu işlemin ileride supratip deformitesi meydana gelmesi riski altında olan primer rinoplasti olgularında kullanılması bu deformiteyi önler. Bu kombinasyon yaklaşımı, seçilmiş primer rinoplasti olgularında, klasik redüksiyon rinoplastisinin bazı komplikasyonlarını önlerken, estetik açıdan tatmin edici bir burun sağlar. Bu işlemi uyguladığımız 11 hastada uzun dönemde iyi fonksiyonel ve estetik sonuçlar elde ettik.

Anahtar Sözcükler: Burun ucu cerrahisi; rinoplasti; semer burun; supratip deformite.

The "Flying wing" procedure, which is classically used in the treatment of moderately severe saddle nose deformities, has also been used for anterior nasal depressions and for the esthetic correction of certain flattened nasal tips.^[1] The saddle nose deformity results from a depression caused by a decrease in the structural support of the cartilaginous or bony framework deep within the nasal soft tissue envelope. Collapse of the middle vault, in relation to the tip and dorsum, results in a characteristic saddle nose deformity, which presents significant reconstructive difficulties.^[2] A network of bony and cartilaginous structures connected to each other by dense fibrous tissue and lined internally by a flexible mucoperichondrium maintains nasal structural integrity. The septal cartilage firmly interlocks with the nasal bones and the bony septum to form a support wall for the middle vault and the nasal tip.^[3]

Various pathologic conditions can lead to a saddle nose deformity, but trauma and prior surgical procedures are the most frequent causes. Nasal trauma resulting in mechanical distortion of the septum or after hematoma formation may lead to necrosis of the cartilaginous septum and loss of support. Surgical disruption of septal attachments to the nasal floor, bony septum and nasal bones, and exaggerated resection of septal cartilage may result in a saddling of the nasal dorsum. These effects may be seen in the early postoperative period or in the months following the procedure.^[4,5]

Daniel and Brenner classified saddle nose in a detailed classification system in 2006 (Table 1). According to their classification, saddle nose deformities occurred as six different types based on clinical findings and pathophysiological processes.^[6-8] Also termed the pseudo-saddle, a type 0 deformity represents a relative depression of the cartilaginous dorsum relative to the bony dorsum. These depressions may arise naturally or as a result of over-resection of the cartilaginous middle vault or over-augmentation of the bony dorsum. Type 3 to type 5 deformities needs more vigorous graft reconstruction techniques in order to restore anatomic and esthetic functions.

PATIENTS AND METHODS

Patients

Rhinoplasty candidates who had primary supratip depressions, saddle nose deformities due to prior

trauma or septal surgery, or who had a high a risk of developing future supratip deformity were selected.

Between April 2004 and January 2008, a "Modified-flying wing" procedure was used for the correction of primary supratip depression deformities in three patients, for saddle nose deformities due to prior trauma or septal surgery in four patients, and for prevention of future supratip deformity in four patients. Follow-up period ranged from 12 to 24 months (Table 2).

Surgical technique

The "Modified-flying wing" procedure was performed as described by Jugo. The lateral crura of the alar cartilages were incised, taking care not to extend the incisions beyond the domes. A flap was created from the cephalic portion of the lateral crus of the alar cartilage, leaving the caudal portion intact. The cartilage flap remained attached at the level of the original domal segment of the middle crura. It was rotated cranially to wrap, and then sutured to the other side of the flap. Cephalic portions of the lateral crura of the alar cartilages were fully freed from the underlying mucosa and rotated superiorly and medially. As we performed an open rhinoplasty approach, pedicled flaps of the cephalic portions of the lateral crura were transfixed in the sagittal plane and following separation of upper lateral cartilages and medial crura, placed on the dorsum of the nasal septum. The upper laterals were sutured to the newly formed cartilaginous dorsum, or a new bridge was created using conchal cartilage. Permanent sutures were placed to fix the transposed cartilages firmly into their new position.^[6]

Case 1– Correction of primary supratip depression: Type 0 primary supratip deformity "Pseudo saddle" without any prior surgery.

Table 1. Daniel and Brenner 2006 saddle nose classification^[6]

| | |
|------------------|--------------------------------------|
| Type 0 Deformity | Pseudo saddle |
| Type 1 Deformity | Minor-cosmetic concealment |
| Type 2 Deformity | Moderate-cartilage vault restoration |
| Type 3 Deformity | Composite-reconstruction |
| Type 4 Deformity | Structural-reconstruction |
| Type 5 Deformity | Catastrophic-major reconstruction |

Table 2. Patients distribution according to their age, gender, pathologies and treatment modalities

| Case | Age/gender | Preoperative pathology | Treatment postoperative follow-up |
|------|------------|-------------------------------|---|
| 1 | 27/F | Saddle nose after septoplasty | Modified-flying wing procedure-tip rhinoplasty/24 months |
| 2 | 19/F | Primary saddle nose | Modified-flying wing procedure/24 months |
| 3 | 29/M | Traumatic saddle nose | Modified-flying wing procedure-combined with open rhinoplasty/18 months |
| 4 | 21/F | Supratip deformity | Modified-flying wing procedure/18 months |
| 5 | 32/F | Saddle nose after septoplasty | Modified-flying wing procedure/18 months |
| 6 | 26/M | Supratip deformity | Modified-flying wing procedure/12 months |
| 7 | 23/F | Supratip deformity | Modified-flying wing procedure/12 months |
| 8 | 19/F | Primary rhinoplasty | Modified-flying wing procedure/24 months |
| 9 | 35/M | Saddle nose after septoplasty | Modified-flying wing procedure/18 months |
| 10 | 27/F | Primary rhinoplasty | Modified-flying wing procedure/24 months |
| 11 | 21/F | Primary rhinoplasty | Modified-flying wing procedure/12 months |

Tip projection was increased using techniques described by Tebbets and the "Modified-flying wing" procedure was performed to get an esthetically pleasing dorsum. In this case, there was no hump removal and no lateral osteotomies were performed (Figure 1).

Case 2– Correction of type 1 saddle nose deformity due to prior septal surgery: Tip projection was increased using techniques described by Tebbets and the "Modified-flying wing" procedure was performed to get an esthetically pleasing dorsum. In this case, there was no hump removal, but lateral osteotomies were performed (Figure 2).

Case 3– Correction of type 1 saddle nose deformity due to prior septal surgery: Tip projection was increased using techniques described by Tebbets and the "Modified-flying wing" procedure was performed to get an esthetically pleasing dorsum. In this case, there was minimal hump removal and median and lateral osteotomies were performed (Figure 3).

Case 4– Correction of type 1 saddle nose deformity due to prior trauma: Tip projection was increased using techniques described by Tebbets and the "Modified-flying wing" procedure was performed to get an esthetically pleasing dorsum. In this case, there was minimal hump removal and median and lateral osteotomies were performed (Figure 4).

Case 5– Tip projection was increased using techniques described by Tebbets. After hump removal (Figure 5), the "Modified-flying wing" procedure was performed to fill the dead space to prevent potential supratip deformity, which would

be seen as a result of contraction of inadequate nasal soft tissue cover. Later formal median and lateral osteotomies were performed.

RESULTS

In all patients, a symmetric, balanced nose was achieved, with adequately projected tip and esthetically pleasing dorsum extending from brows to tip. No patient required a secondary rhinoplasty operation in the 12-24 months follow-up. No complications, such as low radix/low dorsum, narrow middle vault, supratip deformity, internal valvular obstruction, "inverted V" deformity, and inadequate tip projection were seen in any of the patients.

DISCUSSION

Depression deformity of the dorsum of the nose is termed "saddle nose", and commonly occurs due to trauma and to over-reduction of

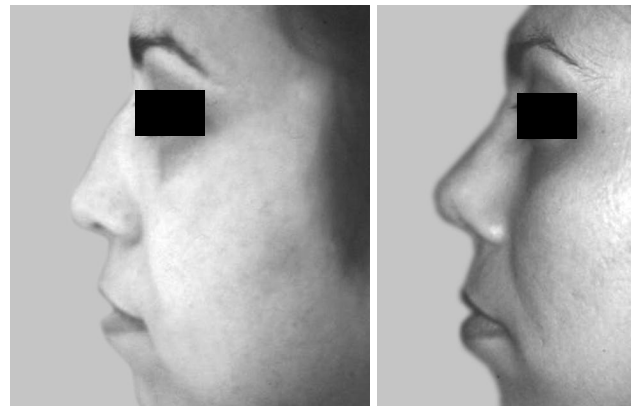


Figure 1. Preoperative and postoperative images of primary supratip deformity case.

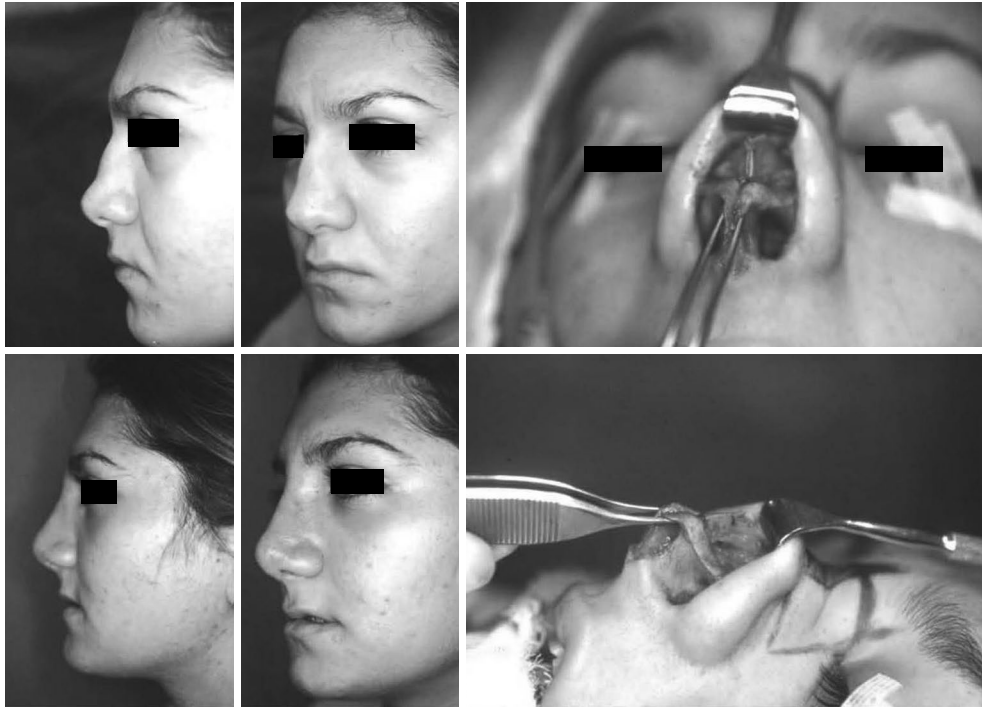

Figure 2. Saddle nose after septoplasty and correction with modified flying wing procedure.

the nasal dorsum during primary rhinoplasty.^[1] Disruption of the septal support wall results in middle vault depression and widening, columellar retrusion, tip over-rotation and deprojection and nasal shortening that characterize the saddle nose deformity. The "Flying wing" procedure has been known for a long time and has classically been used in the treatment of moderately severe saddle nose. This procedure, as modified by Jugo, is termed the "Modified-flying wing" procedure and has some advantages, such as reduction of cephalad bulbosity of the lateral crura and provision of a cartilage framework support in the supratip region, thus correcting saddle nose deformities.^[9]

In this report, we present the usage of the "Modified-flying wing" procedure with different indications, such as correction of primary supratip depression, type 0, type 1, and type 2 saddle nose deformities due to prior septal surgery or trauma. We also used this procedure to strengthen the middle vault and the nasal tip for firm interlocking with the septal cartilage.

Reconstruction of the saddle nose may involve the use of different augmentation materials, from autogenous bone and cartilage to alloplastic materials. The most important issues when considering the choice of reconstructive technique, besides the underlying pathology and expected result, includes long-term results, donor site morbidity,

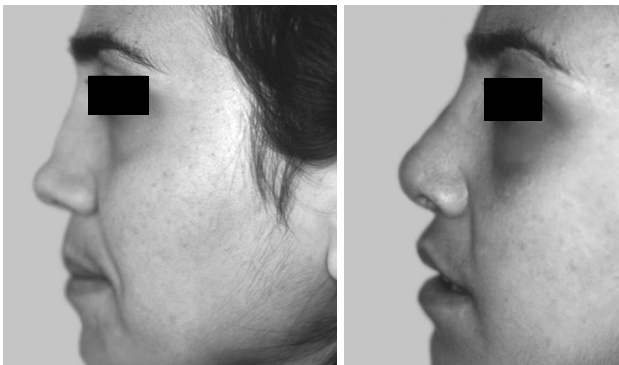


Figure 3. Saddle nose after septoplasty.

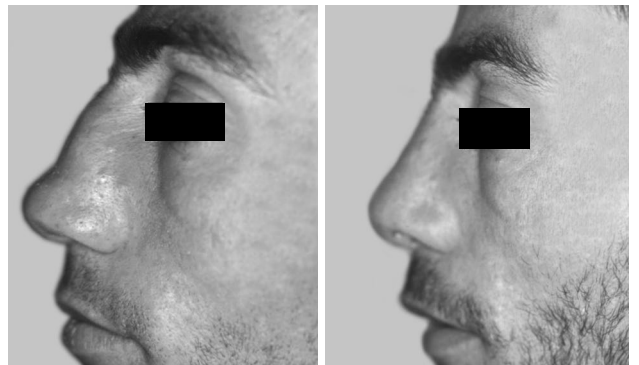


Figure 4. Traumatic saddle nose deformity.

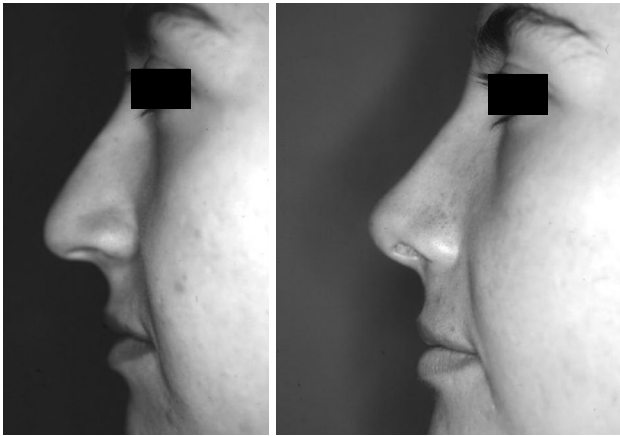


Figure 5. A primary rhinoplasty case in order to prevent supratip deformity.

and the risk of implant infection, implant exposition, and graft resorption.^[10]

Autograft usage as a filling material in saddle nose deformity avoids major disadvantages of alloplasts, such as susceptibility to local infection, extrusion and displacement of the material used, difficulty in fixing into position and also circumvents the drawbacks of the homograft's, such as risk of infection transmission and immunological concerns.^[1-7,9] Costal and conchal cartilage, calvarial bone,^[11] metatarsal bone graft,^[12] fascia lata, and temporalis fascia are all used as autografts. Bare, diced cartilage grafts from the septum, concha, or rib have been used, but are associated with the possibility of shifting, despite placement in a secure pocket of tissue, and with palpable irregularities, especially in thinner-skinned individuals.^[13]

Using the "Modified-flying wing" procedure for the correction of saddle nose deformity avoids some of the disadvantages of the autografts, such as the emerging problem of deficiency of septal cartilage in most saddle nose patients, the tendency of the autograft to warp and curl, later visibility and distortion associated with cartilage grafts, risk of donor site morbidity, and warping and curving of the costal cartilage.

Nasal augmentation with alloplastic materials has become popular especially in Asia.^[14,15] Due to their inert biologic properties, silicone implants remain widely used in dorsal augmentation. The fibrous capsule that surrounds these smooth implants does not integrate with the adjacent tissue and is therefore prone to shifting and buckling.^[16,17] A porous high-density polyethylene

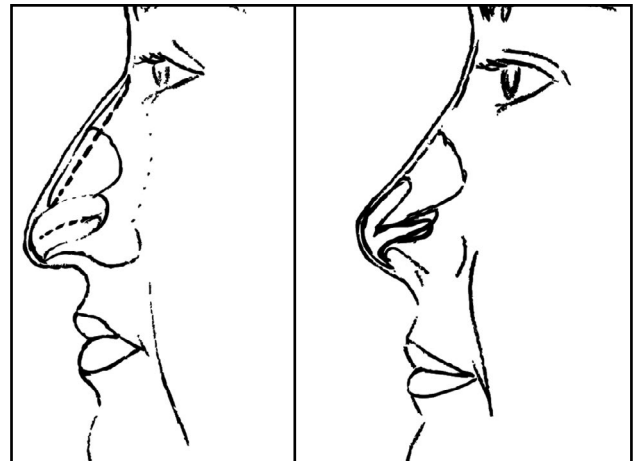

Figure 6. Schematic drawing of the procedure.

material that allows ingrowth of connective tissue and more complete integration of the implant into the soft tissue has been studied.^[18,19] Alloplastic materials have a risk of infection and chances of displacement and extrusion. Meticulous material handling, perioperative antibiotic instillation, and long-term follow-up can help limit the relatively high rates of infection, rejection, and fistula formation.^[20]

In a primary supratip depression, such as flattened tip cases that have normal radix-dorsum ratio, normal nasal width and normal tip projection, the usage of the "Modified-flying wing" procedure alone may provide an esthetically pleasing dorsum. The original procedure is modified by a transcartilaginous rather than a marginal approach, partial rather than total transfer of the lateral crus to preserve the alar ring, and resection as required at the junction of the two crura to allow transposition without deformation of the nostril aperture, as well as the possible association with suture-approximation of the domes in order to accentuate the projection of the nasal tip. Classically performed dorsal resection in reduction rhinoplasty procedures may place these patients at particular risk for unsatisfactory post-operative results.

This procedure may be indicated in secondary, dysmorphic, or simply unsightly flattened tips, whenever the preoperative assessment reveals a low profile of the nasal spine with even minor osteocartilaginous dysjunction associated with flattening of the tip, simultaneously resulting in the need for reinclusion for harmonization of the profile and the need to

shorten, elevate, and reduce the tip. It not only changes the bridge contour, but also alters the bony vault width, the middle vault and the internal valvular support, consequently exposing the patients with a normal radix to the risk of a low radix, thereby creating a technical dilemma.^[3,15] The "Modified-flying wing" procedure prevents these complications. According to the needs of patients, some maneuvers like hump removal, median and lateral osteotomies, or arrangement of the tip projection may be added. Also sliding of the cephalic portion of the lower lateral cartilage beneath the caudal alar cartilage in order to reshape and support nasal tip has been used by some authors.^[21]

An iatrogenic convexity located immediately cephalad to the nasal tip is described as a supratip deformity.^[22] This deformity still represents one of the most common postoperative deformities that require secondary rhinoplasty.^[22-26] Sheen^[27] suggested that most supratip deformities were actually the result of over-resection of the caudal dorsum. The primary cause of this deformity is widely accepted to be the scar tissue formed in response to the dead space created by over-resection.^[28-30] This deformity is seen especially in patients with thick skin and large sebaceous glands.

The "Modified-flying wing" procedure, when used on primary rhinoplasty patients who have a risk of developing future supratip deformity, supports the middle vault and provides a cartilage framework in the supratip region for nasal soft tissue cover to contract, thus preventing potential supratip deformity. In conclusion, this combination approach in selected primary rhinoplasty cases provides an esthetically pleasing nose and prevents some complications of classical reduction rhinoplasty.

REFERENCES

1. Beekhuis GJ. Saddle nose deformity: etiology, prevention, and treatment; augmentation rhinoplasty with polyamide. *Laryngoscope* 1974;84:2-42.
2. Lupo G. The history of aesthetic rhinoplasty: special emphasis on the saddle nose. *Aesthetic Plast Surg* 1997;21:309-27.
3. Tardy ME Jr, Schwartz M, Parras G. Saddle nose deformity: autogenous graft repair. *Facial Plast Surg* 1989;6:121-34.
4. Bilen BT, Kiliç H. Reconstruction of saddle nose deformity with three-dimensional costal cartilage graft. *J Craniofac Surg* 2007;18:511-5.
5. Andrade M, Fernandes VS, Boléo-Tomé JP. Saddle nose: our approach to the problem. *Aesthetic Plast Surg* 1999;23:403-6.
6. Daniel RK, Brenner KA. Saddle nose deformity: A new classification and treatment. *Facial Plast Surg Clin North Am* 2006;14:301-12.
7. Dyer WK 2nd, Beaty MM, Prabhat A. Architectural deficiencies of the nose: treatment of the saddle nose and short nose deformities. *Otolaryngol Clin North Am* 1999;32:89-112.
8. Kalogjera L, Bedeković V, Baudoin T, Ivkić M. Modified alar swing procedure in saddle nose correction. *Aesthetic Plast Surg* 2003;27:209-12.
9. Jugo SB. Modified Kazanjian flying wings procedure. In: Tos M, Thomsen J, Balle V, editors. *Rhinology-a state of the art*. Amsterdam: Kugler; 1995. p. 169-72.
10. Silver WE. Augmentation of the nasal dorsum. In: Krause CJ, editor. *Aesthetic facial surgery*. Philadelphia: JB Lippincott; 1991. p. 321-7.
11. Stuzin JM, Kawamoto HK. Saddle nasal deformity. *Clin Plast Surg* 1988;15:83-93.
12. Emsen IM. The use of metatarsal bone grafts in the treatment of saddle nose deformities. *Aesthetic Plast Surg* 2006;30:705-7.
13. Erol OO. The Turkish delight: a pliable graft for rhinoplasty. *Plast Reconstr Surg* 2000;105:2229-41.
14. Beekhuis GJ. Use of silicone-rubber in nasal reconstructive surgery. *Arch Otolaryngol* 1967;86:88-91.
15. Tham C, Lai YL, Weng CJ, Chen YR. Silicone augmentation rhinoplasty in an Oriental population. *Ann Plast Surg* 2005;54:1-5.
16. Romo T 3rd, Kwak ES. Nasal grafts and implants in revision rhinoplasty. *Facial Plast Surg Clin North Am* 2006;14:373-87.
17. Davis PK, Jones SM. The complications of silastic implants. Experience with 137 consecutive cases. *Br J Plast Surg* 1971;24:405-11.
18. Wellisz T. Clinical experience with the Medpor porous polyethylene implant. *Aesthetic Plast Surg* 1993;17:339-44.
19. Romo T 3rd, Sclafani AP, Sabini P. Reconstruction of the major saddle nose deformity using composite allo-implants. *Facial Plast Surg* 1998;14:151-7.
20. Bracaglia R, Fortunato R, Gentileschi S. Secondary rhinoplasty. *Aesthetic Plast Surg* 2005;29:230-9.
21. Ozmen S, Eryilmaz T, Sencan A, Cukurluoglu O, Uygur S, Ayhan S, et al. Sliding alar cartilage (SAC) flap: a new technique for nasal tip surgery. *Ann Plast Surg* 2009;63:480-5.
22. Constantian MB. Distant effects of dorsal and tip grafting in rhinoplasty. *Plast Reconstr Surg* 1992;90:405-18.
23. Constantian MB. The incompetent external nasal valve: pathophysiology and treatment in primary and secondary rhinoplasty. *Plast Reconstr Surg* 1994; 93:919-31.
24. Constantian MB. Primary rhinoplasty: basic techniques. In: Cohen M, editor. *Mastery of plastic and reconstructive surgery*. Boston: Little, Brown and Company; 1994. p. 1999-2020.
25. Parkes ML, Kanodia R, Machida BK. Revision rhinoplasty. An analysis of aesthetic deformities. *Arch Otolaryngol Head Neck Surg* 1992;118:695-701.
26. O'Connor GB, McGregor MW. Secondary rhinoplasties: their cause and prevention. *Plast Reconstr Surg*

- (1946) 1955;15:404-10.
27. Sheen JH. A new look at supratip deformity. *Ann Plast Surg* 1979;3:498-504.
 28. Swanepoel PF, Eisenberg I. Current concepts in cosmetic rhinoplasty. *S Afr Med J* 1981;60:536-44.
 29. Kamer FM, McQuown SA. Revision rhinoplasty. Analysis and treatment. *Arch Otolaryngol Head Neck Surg* 1988;114:257-66.
 30. Sheen JH, Sheen AP. *Aesthetic rhinoplasty*. 2nd ed. St. Louis: Mosby; 1987.