

Comparison of clinical and pathological staging in oral cavity cancers

Oral kavite kanserlerinde klinik ve patolojik evrelemenin karşılaştırılması

Ersoy Doğan, M.D.,¹ Sülen Sarioğlu, M.D.,² Emel Ada, M.D.,³ Hasan Oğuz Çetinayak, M.D.,⁴
Taner Kemal Erdağ, M.D.,¹ Mustafa Cenk Ecevit, M.D.,¹ Enis Alpin Güneri, M.D.,¹ Ahmet Ömer İkiz, M.D.¹

¹Department of Otolaryngology, Medicine Faculty of Dokuz Eylül University, İzmir, Turkey;

²Department of Pathology, Medicine Faculty of Dokuz Eylül University, İzmir, Turkey;

³Department of Radiology, Medicine Faculty of Dokuz Eylül University, İzmir, Turkey;

⁴Department of Radiation Oncology, Medicine Faculty of Dokuz Eylül University, İzmir, Turkey

Objectives: This study aims to compare the clinical and pathological TN stages of patients with oral cavity cancer and to identify the factors leading to staging discrepancies.

Patients and Methods: The medical records of 125 patients (77 males, 48 females; mean age 57 years; range 19 to 82 years) who underwent primary tumor resection and neck dissection simultaneously for oral cavity cancer were retrospectively analyzed. Clinical and pathological TN stages of all patients were compared. Sensitivity, specificity and predictive values of clinical staging were calculated.

Results: Computed tomography (CT) with contrast which was used to examine the cervical lymph node metastasis showed a sensitivity of 71.9%, a specificity of 75%, a positive predictive value of 70.6%, and a negative predictive value of 76.1%. The diagnostic accuracy of CT for detecting mandibular invasion was as follows: sensitivity, 92.6%; specificity, 97%; positive predictive value, 96.1%; and negative predictive value, 94.3%.

Conclusion: High correlation between clinical and pathological stages for assessment of mandibular invasion and neck metastasis supports the reliability of CT in our study. Diagnostic contribution of magnetic resonance imaging is necessary for assessment of extrinsic tongue muscle involvement; in cases of tongue cancer which are surrounded by induration on palpation and extending to the floor of the mouth.

Key Words: Cervical lymph node; clinical staging; extrinsic tongue muscle; mandible; oral cavity cancer; pathological staging.

Amaç: Bu çalışmada oral kavite kanseri olan hastalarda klinik ve patolojik TN evreleri karşılaştırıldı ve evreleme farklılıklarına yol açan faktörler belirlendi.

Hastalar ve Yöntemler: Çalışmada oral kavite kanseri nedeniyle primer tümör rezeksiyonu ve eş zamanlı boyun diseksiyonu yapılan 125 hastanın (77 erkek, 48 kadın; ort. yaş 57 yıl; dağılım 19-82 yıl) tıbbi kayıtları retrospektif olarak incelendi. Tüm hastaların klinik ve patolojik TN evreleri karşılaştırıldı. Klinik evrelemenin duyarlılığı, özgüllüğü ve prediktif değerleri hesaplandı.

Bulgular: Servikal lenf nodu metastazını incelemek için yapılan kontrastlı bilgisayarlı tomografide (BT), %71.9 duyarlılık, %75 özgüllük, %70.6 pozitif prediktif değer ve %76.1 negatif prediktif değer tespit edildi. Bilgisayarlı tomografinin mandibüler invazyonun tespitinde tanısal doğruluğu ise şöyledi: %92.6 duyarlılık; %97 özgüllük; %96.1 pozitif prediktif değer; %94.3 negatif prediktif değer.

Sonuç: Çalışmamızda mandibüler invazyon ve boyun metastazının değerlendirilmesinde klinik ve patolojik evreler arasındaki yüksek düzeydeki ilişki, BT'nin güvenilirliğini desteklemektedir. Palpasyonda endürasyon ile çevrili olan ve ağız tabanına doğru uzanan dil kanseri olgularında, ekstremsel dil kası tutulumunu değerlendirmek için manyetik rezonans görüntülemenin tanısal katkısına ihtiyaç vardır.

Anahtar Sözcükler: Servikal lenf nodu; klinik evreleme; ekstremsel dil kası; mandibula; oral kavite kanseri; patolojik evreleme.

Accurate clinical TNM (cTNM) staging is crucial for treatment planning in oral cavity cancers (OCCs). Clinical T staging (cT) based on the dimensions and extent of the primary tumor is essential for determining tumor resectability, planning of resection margins and surgical reconstruction; whereas clinical N (cN) staging based on the presence or absence of cervical metastatic lymphadenopathy is crucial for planning of neck dissection. Pathological T (pT) and pathological N (pN) staging performed after surgical resection of the primary tumor and neck dissection determines the necessity of adjuvant therapy. The most appropriate curative treatment with minimal morbidity can only be performed when there is a high correlation between clinical and pathological TN (cTN and pTN) stages.

According to the seventh edition of American Joint Committee on Cancer (AJCC) cancer staging manual, T stage of OCC is divided into four stages.^[1] The T₁ to T₃ stages are based on the greatest dimension of the tumor, whereas T_{4a} and T_{4b} stages are based on tumor extension into surrounding tissues regardless of primary tumor size. Precisely performed physical examination complemented with correct choice of radiological imaging techniques is necessary for increasing the accuracy of cT staging.^[2,3] Computed tomography (CT) and magnetic resonance imaging (MRI) are the standard modalities for evaluation of the primary tumor and neck status in patients with OCC. In general, CT with contrast is preferred for assessment of lymph node and cortical bone involvement; whereas MRI is preferred for evaluation of the deep tissue extent (floor of the mouth, extrinsic tongue muscle and the base of the tongue) of the primary tumor and medullary bone invasion.^[2-4]

The cN staging is carried out depending on whether or not a cervical metastatic lymphadenopathy is identified in the neck. In cases where a metastatic lymph node is present, it is staged as N₁, N_{2a}, N_{2b}, N_{2c} or N₃ on the basis of the dimension, number and unilateral or bilateral nature of the lymph node(s).^[1] The radiological features of metastatic lymphadenopathy are central necrosis, heterogeneous contrasting, irregular contours and peripheral soft tissue invasion in cases of extracapsular extension.^[2,5-7] Computed tomography with contrast is the most preferred imaging method for metastatic lymph node evaluation.^[7]

PATIENTS AND METHODS

The study was approved by the Ethical Committee for Non-Invasive Human Research at Dokuz Eylul University School of Medicine. Medical records of 125 patients (77 males, 48 females; mean age 57 years; range 19 to 82 years) who underwent primary tumor resection and simultaneous neck dissection for OCC at the Department of Otorhinolaryngology-Head and Neck Surgery of Dokuz Eylul University School of Medicine between June 1987 and November 2010 were retrospectively reviewed. Computed tomography was used in all 125 patients for cT and cN staging while MRI was used in 32 patients in addition to CT, especially in those patients with tongue and floor of the mouth cancer to evaluate the deep tissue extension of the tumor. Evaluation of the neck for possible lymphatic metastasis was done by both palpation and CT with contrast. Lymph nodes were considered metastatic if their maximum diameter was more than 10 mm, if central necrosis, heterogeneous contrasting, irregular contours and peripheral soft tissue invasion were present. In assessing the presence of mandibular invasion, axial and coronal CT with bone windows was used.

All patients were restaged according to 2010 AJCC criteria. Clinical TN stages determined by pre-surgical physical and radiological examinations were compared with pTN stages of histopathological examinations of post-surgical formalin fixed specimens and the sensitivity, specificity, positive and negative predictive values of clinical staging were calculated (Table 1 and 2).

RESULTS

The tumor localization was the tongue in 68 patients, the floor of the mouth in 20 patients, the retromolar trigone in 13 patients, the buccal mucosa in 11 patients, the alveolar ridge in 10 patients and the hard palate in three patients. Two factors leading to discrepancies between clinical N and pathological N staging were identified: clinically detected lymph nodes are not always found to be metastatic on pathological examination and occult metastases may be seen in patients clinically staged N₀. Three main factors that led to discrepancies between clinical T and pathological T staging were noted: reduction of the specimen size as a result of formalin fixation, false (+) or false (-) findings in the radiological assessment of mandibular invasion

Table 1. Comparison of clinical T and pathological T stages

	pT ₁	pT ₂	pT ₃	pT ₄	rPT ₀
cT ₁	22	–	–	–	1
cT ₂	19	29	–	2 ^a	–
cT ₃	–	6	11	3 ^b	–
cT ₄	–	2 ^c	–	25	–
rTx	–	–	–	–	2
rT ₁	–	–	–	–	1
rT ₄	–	–	–	2	–
Total	41	37	11	32	4

rTx, no evidence of tumor on preoperative examination; rT₁, recurrent T₁ tumor; rPT₀, no evidence of tumor on pathologic examination; a: two patients were staged as pT_{4a} due to extrinsic tongue muscle invasion; b: one patient was staged as pT_{4a} due to extrinsic tongue muscle invasion and two patients were staged as pT_{4a} due to mandibular invasion; c: one patient with floor of the mouth cancer was staged as cT₄ due to mandibular invasion radiologically, one patient with buccal mucosa cancer was staged as cT_{4a} due to upper alveolar ridge and hard palate invasions.

and undiagnosed extrinsic tongue muscle invasion in clinical staging.

Computed tomography with contrast used to examine the cervical lymph node metastasis showed a sensitivity of 71.9%, a specificity of 75%, a positive predictive value of 70.6%, and a negative predictive value of 76.1% (Table 3).

A total of 61 mandibulectomies (43 segmental and 18 marginal) were performed. Of the 43 patients who underwent segmental mandibulectomy, 17 patients had no sign of mandibular invasion radiologically nor was mandibular invasion detected in any of these patients on pathological examination. Computed tomography correctly revealed 25 of 26 cases with mandibular invasion. Of the 26 patients who were staged as cT₄ due to

Table 3. Sensitivity, specificity and predictive values of clinical staging in diagnosis of cervical lymph node metastasis

Clinical staging	Cervical lymph node metastasis	
	Pathological staging	
	N (+)	N (0)
N (+)	41	17
N (0)	16	51

Sensitivity 71.9%, Specificity 75%, Positive predictive value 70.6%, Negative predictive value 76.1%, Occult metastasis rate for T₁ and T₂ 18.3%, for T₃ and T₄ 37.5%.

Table 2. Comparison of clinical N and pathological N stages

	pN ₀	pN ₁	pN _{2a}	pN _{2b}	pN _{2c}
cN ₀	51	7	–	7	2
cN ₁	16	8	–	16	–
cN _{2a}	–	1	–	1	–
cN _{2b}	1	1	–	9	–
cN _{2c}	–	2	–	1	2
Total	68	19	–	34	4

mandibular invasion and underwent segmental mandibulectomy, pathological mandibular invasion was detected in 25 patients and in only one patient was mandibular invasion not detected on pathological examination. Computed tomography correctly excluded mandibular invasion in 33 of 35 cases without invasion. In all 18 patients who underwent marginal mandibulectomy, the procedure was performed to obtain free mucosal margins because of tumor proximity to the mandible and there was no sign of radiological mandibular invasion in any of these patients. However, in two of these 18 patients, mandibular invasion was detected on pathological examination and they were staged as pT₄. The diagnostic accuracy of CT for detecting mandibular invasion was as follows: sensitivity, 92.6%; specificity, 97%; positive predictive value, 96.1%; and negative predictive value, 94.3% (Table 4). Extrinsic tongue muscle invasion was detected on pathological examination in six of the 68 patients who underwent surgery for tongue carcinoma. Magnetic resonance imaging was performed in four of these six patients and demonstrated the extrinsic tongue muscle invasion in three patients.

Table 4. Sensitivity, specificity and predictive values of clinical staging in diagnosis of mandibular invasion

Clinical staging	Mandibular invasion	
	Pathological staging	
	Present	Absent
Present	25	1
Absent	2	33

Sensitivity 92.6%, Specificity 97%, Positive predictive value 96.1%, Negative predictive value 94.3%.

DISCUSSION

The first line treatment for OCC is surgery, mostly in the form of primary tumor resection and simultaneous neck dissection.^[8] Undesirable cosmetic deformities and unnecessary morbidity can be created with a much larger resection than required, and additional neck dissection may have a negative impact on patients' quality of life. On the other hand insufficient resection leading to surgical margin positivity or negligence of an indicated neck dissection may reduce patients' survival.^[9] For this reason, the scope of surgery in OCCs must be wide enough to provide a safe tumor resection while it must also be correctly focused in order to prevent over resection and minimize morbidity. In order to achieve these goals clinical staging of tumor has to be as accurate as possible.

The presence of lymph node metastasis which diminishes the rates of locoregional control of the disease and the survival of these patients is the most important prognostic factor for head and neck cancers.^[5,8,10,11] In OCCs, especially tongue and floor of the mouth cancers, the incidence of cervical lymph node metastases is relatively high when compared with other regions of the head and neck.^[11-13] Computed tomography with contrast is the most commonly used imaging modality for assessing the neck status in head and neck cancers.^[2,5,6] In our study, CT with contrast showed a sensitivity of 71.9%, a specificity of 75%, a positive predictive value of 70.6%, and a negative predictive value of 76.1% sensitivity; which is consistent with the literature.

Shrinking of the specimen due to fixation in formalin is a critical factor that leads to discrepancies between clinical and pathological T stages. In our study we observed that 19 cT₂ staged patients were staged as pT₁, and six patients staged as cT₃ were staged as pT₂. Clinical staging is more accurate than pathological staging in determining the T₁, T₂ and T₃ stages that are based on the primary tumor size, because up to 30% shrinkage of soft tissues may occur in the resected specimen when being preserved. Consequently, pT staging must be derived from the actual measurement of the unfixed tumor in the surgical specimen.^[1]

Mandibular infiltration that upstages the tumor to T_{4a} has to be radiologically evaluated and definitely taken into account during preoperative treatment planning of the OCCs.^[2-4,14,15] Currently,

the adopted opinion is to protect the mandibular integrity unless mandibular invasion is detected on clinical examination to avoid functional as well as cosmetic deformities. The type of mandibulectomy is selected according to the relationship of the tumor to the mandible.^[16,17] Segmental mandibulectomy is preferred only if mandibular invasion is detected radiologically. If the tumor is located in close proximity to the mandible without any invasion, marginal mandibulectomy is preferred in order to obtain negative surgical margins and protect the integrity of the mandible. False (-) results in the assessment of mandibular invasion can lead to insufficient resection and surgical margin positivity. On the other hand false (+) results can lead to undesirable functional and cosmetic deformities due to over resection of the mandible. Therefore, accurate diagnosis of mandibular invasion by clinical and radiological examination is crucial for safe tumor resection with minimal morbidity. In our study, there was one false-positive result and two false-negative results in the assessment of mandibular invasion and the diagnostic accuracy of CT for detecting mandibular invasion was as follows: sensitivity 92.6%; specificity 97%; positive predictive value 96.1%; and negative predictive value 94.3%.

Invasion of the extrinsic tongue muscles (genioglossus, hyoglossus, palatoglossus, styloglossus) upstages the tumor to T_{4a} regardless of primary tumor size.^[1] Computed tomography with contrast is sufficient for determining the T stages of OCCs that are limited to the mucosa and that do not display considerable deep infiltration; whereas in addition to CT, MRI is also required to evaluate deep muscular and soft tissue invasions for deeply infiltrating tumors especially when widespread induration surrounding the tumor is noticed.^[2,3,18,19]

Extrinsic tongue muscle invasion was detected pathologically in six of 68 patients who had surgery for tongue cancers. As MRI was not available in the early period of our study it was not used for the preoperative evaluation in two of these patients. One of these patients was staged as cT₂ and the other cT₃ according to the physical examination and CT findings. Pathological stages of these patients were pT_{4a} as a result of extrinsic tongue muscle invasion and surgical margin positivity was also present in both of these patients. Magnetic resonance

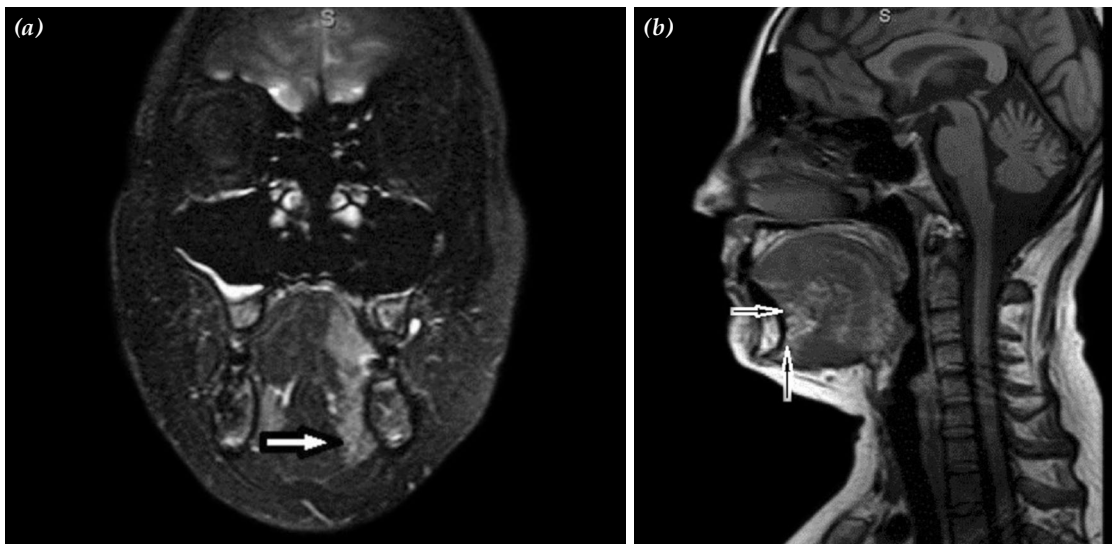


Figure 1. Magnetic resonance imaging of a patient with a 3.5x2 cm mass at the right side of the tongue staged as T₂ on clinical examination. (a) Coronal T₂ weighted magnetic resonance imaging revealed infiltration of genioglossus muscle (arrow) and the tumor was staged as cT₄. (b) Sagittal T₁ weighted magnetic resonance imaging also reveals the infiltration of genioglossus muscle (arrows).

imaging was performed in four of these six patients and correctly demonstrated the extrinsic tongue muscle invasion in three patients (Figure 1a and 1b). However MRI overlooked extrinsic tongue muscle invasion in one patient with a tongue cancer showing extensive peripheral induration on palpation and the patient was staged as cT₃. But pathological examination revealed the presence of extrinsic tongue muscle invasion and the tumor was upstaged to pT_{4a}. There was no false-positive result in the assessment of extrinsic tongue muscle invasion in our series. Our findings suggest the additional value of MRI in detecting extrinsic tongue muscle involvement for T₂ or T₃ tongue cancers infiltrating the floor of the mouth and surrounded by induration on palpation. Diagnosis of extrinsic tongue muscle invasion preoperatively provides safe surgical margins with wide resection and predicts the necessity of adjuvant therapy making it possible to give correct information to the patient about additional treatments beforehand.

In conclusion, mandibular invasion and extrinsic tongue muscle invasion are two important factors that upstage the tumor to T_{4a} regardless of size in staging of the OCCs. The results of our study show that CT is a reliable technique to demonstrate or rule out mandibular invasion due to its high sensitivity and specificity. On the other hand our results support the

additional contribution of MRI for evaluation of extrinsic tongue muscle invasion especially for infiltrating tumors that are surrounded with induration on palpation. However as our number of patients is small for this group of patients further investigations with MRI for extrinsic tongue involvement are still required.

Declaration of conflicting interests

The authors declared no conflicts of interest with respect to the authorship and/or publication of this article.

Funding

The authors received no financial support for the research and/or authorship of this article.

REFERENCES

1. Edge SB, Byrd DR, Compton CC, Fritz AG, Green FL, Trotti A, editors. AJCC Cancer Staging Manual. 7th ed. New York, NY: Springer; 2010.
2. Chong V. Oral cavity cancer. *Cancer Imaging* 2005;5 Spec No A:S49-52.
3. Abd El-Hafez YG, Chen CC, Ng SH, Lin CY, Wang HM, Chan SC, et al. Comparison of PET/CT and MRI for the detection of bone marrow invasion in patients with squamous cell carcinoma of the oral cavity. *Oral Oncol* 2011;47:288-95.
4. Bolzoni A, Cappiello J, Piazza C, Peretti G, Maroldi R, Farina D, et al. Diagnostic accuracy of magnetic resonance imaging in the assessment of mandibular involvement in oral-oropharyngeal squamous cell carcinoma: a prospective study. *Arch Otolaryngol Head Neck Surg* 2004;130:837-43.

5. Don DM, Anzai Y, Lufkin RB, Fu YS, Calcaterra TC. Evaluation of cervical lymph node metastases in squamous cell carcinoma of the head and neck. *Laryngoscope* 1995;105:669-74.
6. Castelijns JA, van den Brekel MW. Imaging of lymphadenopathy in the neck. *Eur Radiol* 2002;12:727-38.
7. Malard O, Toquet C, Jegoux F, Bordure P, Beauvillain de Montreuil C, Gayet-Delacroix M. Computed tomography in TN stage evaluation of oral cavity and oropharyngeal cancers. *Clin Imaging* 2004;28:360-7.
8. Ogawa T, Matsuura K, Shiga K, Tateda M, Katagiri K, Kato K, et al. Surgical treatment is recommended for advanced oral squamous cell carcinoma. *Tohoku J Exp Med* 2011;223:17-25.
9. Binahmed A, Nason RW, Abdoh AA. The clinical significance of the positive surgical margin in oral cancer. *Oral Oncol* 2007;43:780-4.
10. Pimenta Amaral TM, Da Silva Freire AR, Carvalho AL, Pinto CA, Kowalski LP. Predictive factors of occult metastasis and prognosis of clinical stages I and II squamous cell carcinoma of the tongue and floor of the mouth. *Oral Oncol* 2004;40:780-6.
11. Ferlito A, Silver CE, Rinaldo A. Elective management of the neck in oral cavity squamous carcinoma: current concepts supported by prospective studies. *Br J Oral Maxillofac Surg* 2009;47:5-9.
12. Liu TR, Chen FJ, Yang AK, Zhang GP, Song M, Liu WW, et al. Elective neck dissection in clinical stage I squamous cell carcinoma of the tongue: Does it improve regional control or survival time? *Oral Oncol* 2011;47:136-41.
13. Werning JW, Heard D, Pagano C, Khuder S. Elective management of the clinically negative neck by otolaryngologists in patients with oral tongue cancer. *Arch Otolaryngol Head Neck Surg* 2003;129:83-8.
14. Babin E, Desmots C, Hamon M, Bénateau H, Hitier M. PET/CT for assessing mandibular invasion by intraoral squamous cell carcinomas. *Clin Otolaryngol* 2008;33:47-51.
15. Mukherji SK, Isaacs DL, Creager A, Shockley W, Weissler M, Armao D. CT detection of mandibular invasion by squamous cell carcinoma of the oral cavity. *AJR Am J Roentgenol* 2001;177:237-43.
16. Brown JS, Kalavrezos N, D'Souza J, Lowe D, Magennis P, Woolgar JA. Factors that influence the method of mandibular resection in the management of oral squamous cell carcinoma. *Br J Oral Maxillofac Surg* 2002;40:275-84.
17. Imaizumi A, Yoshino N, Yamada I, Nagumo K, Amagasa T, Omura K, et al. A potential pitfall of MR imaging for assessing mandibular invasion of squamous cell carcinoma in the oral cavity. *AJNR Am J Neuroradiol* 2006;27:114-22.
18. Dammann F, Horger M, Mueller-Berg M, Schlemmer H, Claussen CD, Hoffman J, et al. Rational diagnosis of squamous cell carcinoma of the head and neck region: comparative evaluation of CT, MRI, and 18FDG PET. *AJR Am J Roentgenol* 2005;184:1326-31.
19. Trotta BM, Pease CS, Rasamny JJ, Raghavan P, Mukherjee S. Oral cavity and oropharyngeal squamous cell cancer: key imaging findings for staging and treatment planning. *Radiographics* 2011;31:339-54.