

Giant pleomorphic adenoma of the parotid gland

Parotis bezinde dev pleomorfik adenom

Mehmet Ali Çetin, M.D.,¹ Aykut İkinciogulları, M.D.,¹ Gökçe Saygı, M.D.,¹ Hatice Gül Hatipoğlu, M.D.,² Sabri Köseoğlu, M.D.,¹ Hüseyin Dere, M.D.¹

Departments of ¹Otolaryngology and ²Radiology, Ankara Numune Training and Research Hospital, Ankara, Turkey

Pleomorphic adenomas are the most common benign tumors of the salivary glands. These adenomas generally present without pain and are slowly enlarged. However, they can reach enormous sizes, because they are often neglected by the patient and due to late diagnosis and intervention because of fear of surgery or sociocultural factors. This may lead to functional, aesthetic and social problems. In this article, we present a 55-year-old female patient with a giant pleomorphic adenoma in size of 15x15x20 cm, who presented with the complaint of a mass enlarged and swollen for 20 years in her left neck and face and underwent a successful surgery.

Key Words: Giant; parotid gland; pleomorphic adenoma.

Tükürük bezlerinin en yaygın benign tümörü pleomorfik adenomlardır. Bu adenomlar, genellikle ağrısız seyrederek ve yavaş büyür. Ancak sıklıkla hasta tarafından kitlenin önemsenmemesi ve cerrahi korku veya sosyokültürel etmenlerden dolayı gecikmiş tanı ve girişim nedeniyle adenomlar dev boyutlara ulaşabilmektedir. Bu durum fonksiyonel, estetik ve sosyal sorunlar yaratabilmektedir. Bu yazıda, cerrahi ile başarılı bir şekilde tedavi edilen sol boyunda ve yüzde 20 yıldır var olan ve gittikçe büyüyen şişlik yakınması olan 55 yaşında kadın hastadaki 15x15x20 cm boyutundaki dev pleomorfik adenom olgusu sunuldu.

Anahtar Sözcükler: Dev; parotis bezi; pleomorfik adenom.

Pleomorphic adenomas are the most common benign tumors of the salivary glands and constitute a majority of parotid tumors. They generally appear as slowly enlarging painless masses. Untreated tumors can achieve different sizes and weights. Treatment is surgical excision with attention to preserve the facial nerve. In order to avoid pseudocapsule rupture and spread of tumor cells to the operating area, the mass has to be extracted with the surrounding tissues. We report a pleomorphic adenoma that presented as a giant mass on the left side of the neck and face.

CASE REPORT

A 55-year-old female presented with a giant painless mass on the left side of her face and neck. The patient had refused surgery for almost 20 years, and had no systemic disease. Physical examination revealed an irregular, painless, semi-mobile, solid mass covered by atrophic but vascularized skin. The lesion was in the parotid region extending from the auricle down to the neck (Figure 1). The mass was approximately 15x15x20 cm. There was no facial palsy and no pathologically-enlarged lymph nodes. Ultrasonography demonstrated a

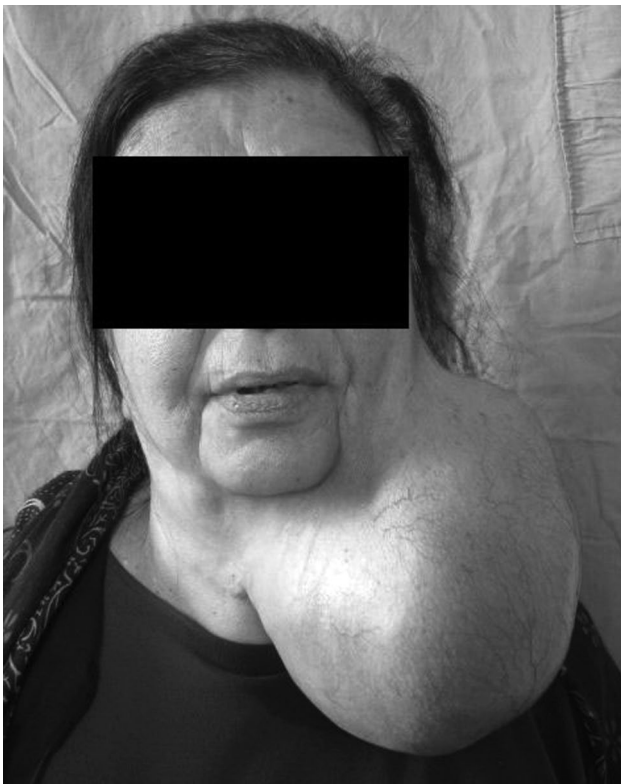

Figure 1. The giant mass lesion is originating from the left parotid gland extending down to the neck.

giant encapsulated mixed-echo mass lesion with cystic and solid components on the left side of the face and neck. Computed tomography showed an encapsulated heterogeneous density mass lesion measuring 17x14x12 cm. There was no invasion

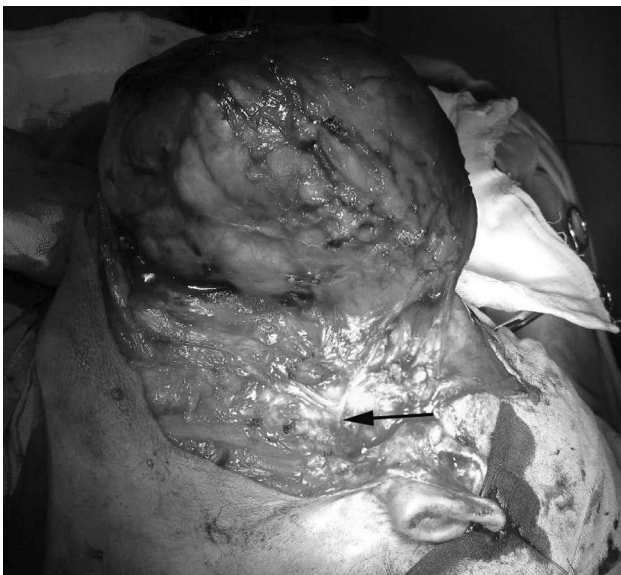

Figure 3. The image shows the facial nerve main truncus (black arrow) and its branches after shifting the mass anteriorly during operation.

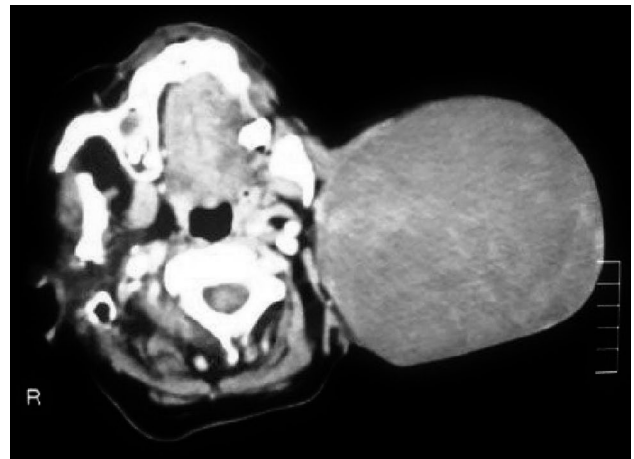


Figure 2. The computed tomography image with contrast demonstrates a heterogeneously enhancing solid, encapsulated mass with apparently regular edges. The lesion originates from superficial lobe of the parotid gland with exophytic extension laterally.

of vascular structures. The mass was lateral to the sternocleidomastoid muscle (SCM) and the interface with the surrounding soft tissue was preserved (Figure 2). Fine needle aspiration biopsy revealed a pleomorphic adenoma.

The mass was excised by superficial parotidectomy under general anesthesia with preservation of the main truncus and the branches of the facial nerve (Figure 3). The functions of the facial nerve were normal in the postoperative period. The mass was bordered by the SCM posteriorly and masseter muscle

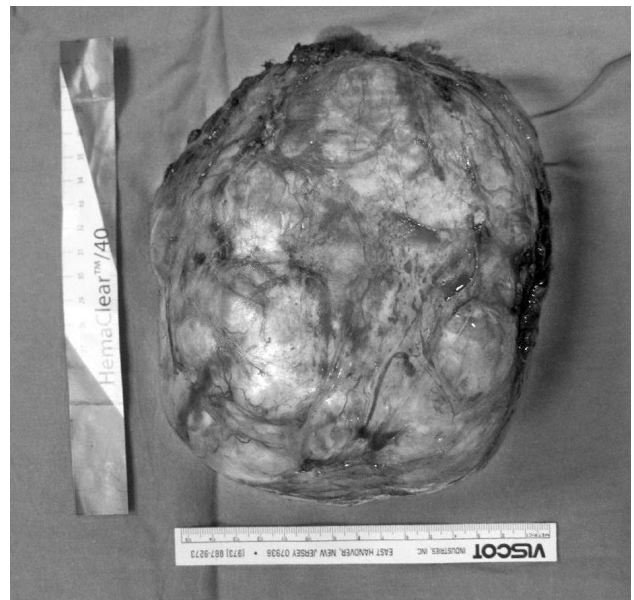

Figure 4. Macroscopically, the excised specimen is ovoid in shape. It measures 15x15x20 cm and weighs 1.6 kg.

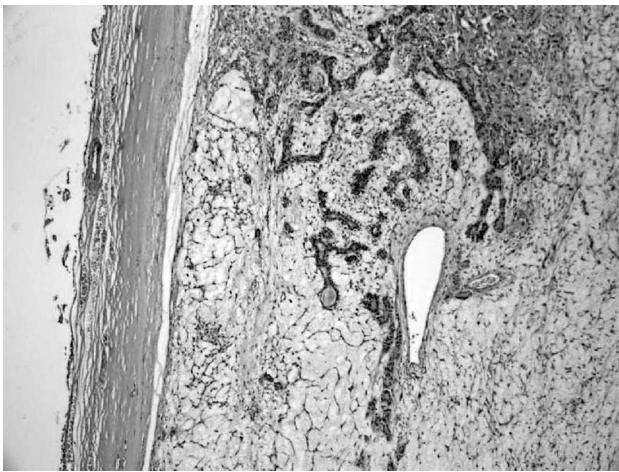


Figure 5. The histopathological specimen demonstrates atrophic salivary gland areas, myxoid stroma and hyalinization. Inside the myxoid stroma, myoepithelial cells, glandular and squamous metaplastic areas can be seen (H-E x 100).

anteriorly. The dimensions of the excised specimen were 15x15x20 cm and the weight was 1.6 kg (Figure 4). The histopathological specimen demonstrated atrophic salivary gland areas, myxoid stroma and hyalinization consistent with pleomorphic adenoma. Inside the myxoid stroma, myoepithelial cells, glandular and squamous metaplastic areas could be seen. There were no signs of malignant transformation (Figure 5).

DISCUSSION

The most common site of salivary gland tumors is the parotid gland.^[1] Eighty percent of parotid gland tumors are benign and 80% of these benign tumors are pleomorphic adenomas.^[2] They are also known as benign mixed tumors. They can occur at any age but are mostly seen in the fifth and sixth decades. The disease incidence is slightly more in females. They are generally slowly enlarging painless masses. Most of the cases originate from the superficial lobe, but they can rarely arise from the deep lobe of the parotid gland as well.^[3] There are several reasons for reaching enormous size at the time of diagnosis, among which are delayed medical care due to ignoring the mass, fear of operation and social causes. But

this delay may cause not only aesthetic and social, but functional problems as well.^[4] Long duration, age, localization in minor salivary glands are risk factors for the malignant transformation.^[5] Apart from anamnesis and physical examination, radiologic examinations such as ultrasonography, computed tomography and magnetic resonance imaging are the supporting methods for diagnosis. The final diagnosis is confirmed by presentation of the epithelial, myoepithelial and mesenchymal components histopathologically. The treatment of pleomorphic adenoma is wide excision of the mass with preservation of the facial nerve.^[6] In order to avoid rupture of the pseudocapsule and spread of tumor cells to the operation site, the mass has to be resected with surrounding tissue. In this case, delay in treatment because of operation fear gave rise to an enormous mass with functional, aesthetic and social problems.

In conclusion, according to modern concepts in medicine early diagnosis and management of the pleomorphic adenoma are advised. Otherwise, delays in treatment might cause functional, aesthetic and social problems. Most importantly, there is potential risk of malignant transformation.

REFERENCES

1. Honda T, Yamamoto Y, Isago T, Nakazawa H, Nozaki M, Hirayama T. Giant pleomorphic adenoma of the parotid gland with malignant transformation. *Ann Plast Surg* 2005;55:524-7.
2. Shaheen OH. Benign salivary tumors. In: Kerr AG, editor. *Scott Brown's otolaryngology*. 5th ed. London: Butterworth Publication; 1987. p. 356-9.
3. Morita N, Miyata K, Sakamoto T, Wada T. Pleomorphic adenoma in the parapharyngeal space: report of three cases. *J Oral Maxillofac Surg* 1995;53:605-10.
4. Nitassi S, Oujilal M, Boulaich M, Essakalli L, Kzadri M. Giant pleomorphic adenoma of the parotid gland. *Rev Stomatol Chir Maxillofac* 2009;110:350-2. Epub 2009. [Abstract]
5. Takahama A Jr, da Cruz Perez DE, Magrin J, de Almeida OP, Kowalski LP. Giant pleomorphic adenoma of the parotid gland. *Med Oral Patol Oral Cir Bucal* 2008;13:E58-60.
6. Yilmaz AD, Unlü E, Orbay H, Sensöz O. Giant pleomorphic adenoma of soft palate leading to obstruction of the nasopharyngeal port. *J Craniofac Surg* 2006;17:1001-4.