

## A case of an apocrine hidrocystoma treated by sublabial approach

Sublabial yaklaşım ile eksize edilmiş apokrin hidrokistomu olgusu

Halil Erdem Özel, M.D.,<sup>1</sup> Ayşegül Kaynar, M.D.<sup>2</sup>

<sup>1</sup>Department of Otolaryngology, İskenderun State Hospital, Hatay, Turkey;

<sup>2</sup>Department of Pathology, İskenderun State Hospital, Hatay, Turkey

Apocrine hidrocystomas are uncommon cystic proliferations of the apocrine secretory glands. Maxilla is an unexpected involvement site for these tumors. Our study represents the first case of an apocrine hidrocystoma of the maxilla excised by an intraoral (sublabial) approach, being the first to define the radiologic findings of apocrine hidrocystoma on this region. This case is an extremely rare type in terms of the unusual symptomatology, location and size of the tumor. In this article, clinical presentation, surgical findings, histopathological features and treatment of this rare lesion were discussed.

**Key Words:** Apocrine glands; hidrocystoma; maxillae; nasal obstruction; sweat gland neoplasms.

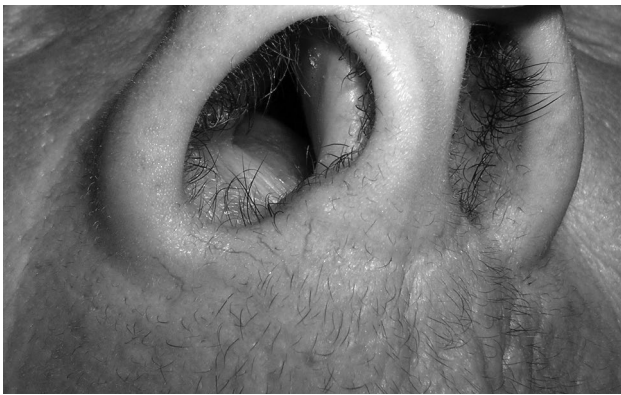Apokrin hidrokistomlar apokrin salgı bezlerinin nadir görülen kistik proliferasyonlarıdır. Maksilla bu tümörler için beklenmedik bir yerleşim yeridir. Çalışmamız maksillada yerleşen ve intraoral (sublabial) yaklaşım ile eksize edilen ilk apokrin hidrokistom olgusunun sunumu olup, bu bölgede yerleşen apokrin hidrokistomunun radyolojik bulgularını tanımlayan ilk çalışmadır. Bu olgu, tümörün sıradışı semptomatolojisi, konumu ve büyüklüğü açısından son derece nadir bir örnektir. Bu yazıda, bu nadir lezyonun klinik tablosu, cerrahi bulguları, histopatolojik özellikleri ve tedavisi irdelendi.

**Anahtar Sözcükler:** Apokrin bezler; hidrokistoma; maksilla; burun tıkanıklığı; ter bezi neoplazmları.

Apocrine hidrocystomas are uncommon, slow-growing benign cystic proliferations of the apocrine secretory glands. Although their pathophysiology remains unclear, the posited causative factor is congestion of a sweat duct resulting in a dilated cystic structure. They usually appear as asymptomatic solitary lesions in the head and neck region. A periorbital location, especially the inner canthus seems to be the favored site. Tumors described in several case reports are mostly less than 20 mm in diameter.<sup>[1,2]</sup> The maxilla is an

unexpected site and it is extremely rare for these benign cysts to develop in deep tissue.

Our study may represent the first case of a giant apocrine hidrocystoma of the maxilla excised by an intraoral (sublabial) approach. It may also be the first study to define the magnetic resonance imaging (MRI) and computed tomographic (CT) findings of the tumor in this region. The clinical presentation, surgical findings histopathological features and treatment of this rare lesion are discussed.



**Figure 1.** Preoperative photograph of the patient with a submucosal cystic mass under the right alar base.

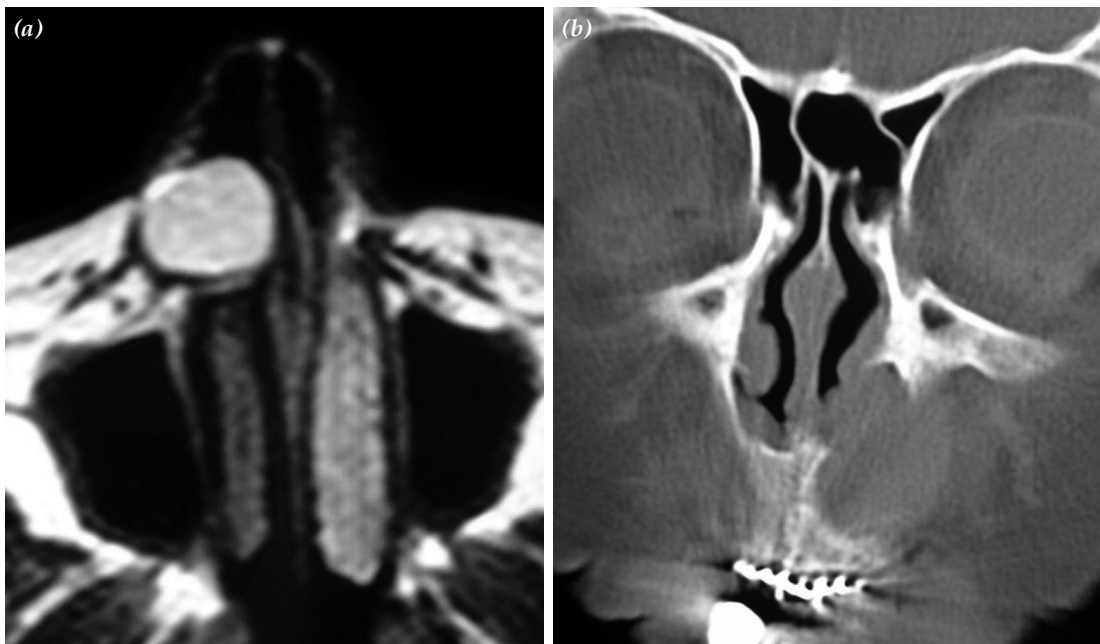
### CASE REPORT

A 70-year-old female presented with a gradual increase in nasal obstruction from the right nasal cavity for the last six months. The patient reported no pain and had not noticed swelling on her face. Anterior rhinoscopic examination revealed the presence of a spheric mass beneath the right alar base. The floor of right nasal vestibule was elevated, causing obstruction of the nasal passage. The overlying mucosa was intact (Figure 1). Intraoral examination revealed a pale mucosal swelling lateral to the midline. On palpation the lesion was elastic, well circumscribed, fluctuant, movable,

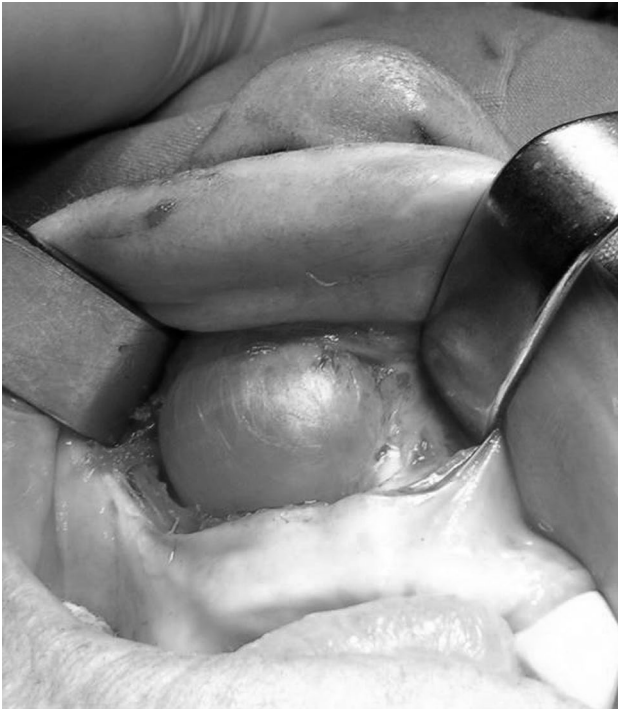painless and measured approximately 3 cm in diameter. A mild asymmetry of the face that was barely noticeable was present in this region. She has had diabetes mellitus for eight years, hypertension for 15 years, asthma for 20 years in her medical history.

Magnetic resonance imaging revealed a sharply demarcated cyst 3 cm in diameter, with homogeneous hypointensity on T<sub>1</sub>-weighted images and hyperintensity on T<sub>2</sub>-weighted images. The cyst wall was thin and uniform. Sedimentation levels were also evident on the MR study. In the posterior portion of the lesion, a slight hyperintense area on T<sub>1</sub>-weighted and a hypointense area on T<sub>2</sub>-weighted images was observed (Figure 2a). Postcontrast images showed no enhancement of the contents or of the wall of the cyst. Coronal CT scans of the paranasal sinuses demonstrated a partly dense lesion immediately anterior and inferior to the piriform apertures and underlying bony erosion of the nasal base of the maxillary alveolus (Figure 2b).

The lesion was completely excised under general anesthesia by an intraoral (sublabial) approach. The upper gingivolabial sulcus was incised along at the level of the right central incisor to the first premolar just below the piriform apertures. Dissection exposed a smooth,



**Figure 2.** (a) The axial T<sub>2</sub>-weighted magnetic resonance image showing a well-circumscribed cystic lesion with homogeneous hyperintensity. (b) The coronal computed tomography image showing a partly dense lesion and underlying bony erosion of the nasal base of the maxillary alveolus.



**Figure 3.** Perioperative photograph of the patient showing a smooth, well-circumscribed and translucent cyst.

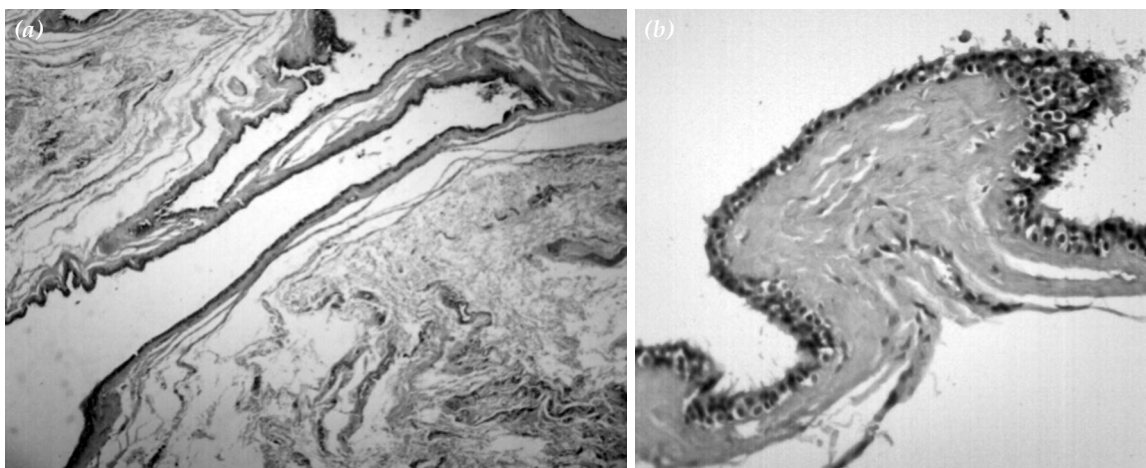
well-circumscribed, fluctuant and translucent cyst that was approximately 3 cm in diameter (Figure 3). No adhesion to the underlying bone was encountered. The lesion was easily released from the bone, skin and the undersurface of the nasal mucosa and removed intact. The lesion produced pressure erosion of the underlying bone and expanded toward the nasal base of the maxillary alveolus. A spheric cavity was left behind after extirpation almost the same size as the lesion. The wound was closed by primary intention. The cyst

wall was observed to be thin and uniform. When incised, the lesion collapsed and a yellowish viscous fluid was released from a single cystic cavity. The specimen was fixed in 10% buffered formalin and submitted for histopathologic diagnosis. The postoperative course was uneventful. No additional treatment was required. Postoperative follow-up at six months showed smooth healing of the wound without evidence of recurrence and the patient remained well without complaint of nasal obstruction.

Histopathological gross examination demonstrated a cystic structure of 3 cm in diameter, bright white in color and with a smooth inner surface. Microscopically, the lesion was characterised by multilocular cystic papillary projections (Figure 4a). The inner surface of the cyst and papillary projections were lined by secretory cells. The secretory cells were lined by an outer layer of myoepithelial cells parallel to the cyst wall. The secretory cells were involved with decapitations pointing of apocrine secretion (Figure 4b). A diagnosis of apocrine hidrocystoma was made based on this characteristic histological pattern.

## DISCUSSION

Hidrocystomas are rare, benign, cystic, adnexal tumors originating from the apocrine sweat glands. They can be either eccrine or apocrine. Apocrine hidrocystomas may annoy patients but usually remain asymptomatic. They occur most often in adults with no age or sex predilection. They often are smaller than 20 mm and most commonly located in the periorbital region.<sup>[1,2]</sup> Our study



**Figure 4.** (a) Photomicrograph showing multilocular cystic papillary projections (H-E x 20). (b) Photomicrograph showing secretory cells involving decapitations (H-E x 100).

presents a giant apocrine hidrocystoma of the maxilla causing nasal obstruction as the primary symptom. This case is an extremely rare type in terms of the unusual symptomatology, location and size of the tumor. Only one case having an apocrine hidrocystoma 2 cm in diameter on the nasolabial fold was described by Armstrong et al.<sup>[3]</sup> Our case is the first one excised by an intraoral (sublabial) approach.

Based on the clinical appearance and radiological findings the preliminary diagnosis in our case was a nasolabial cyst. Nasolabial cysts are rare, nonodontogenic, frequently asymptomatic developmental masses occurring inferior to the nasal alar region. The patient usually presents with a unilateral slowly enlarging asymptomatic swelling at the nasolabial fold. Cysts are typically located immediately anterior and inferior to the piriform apertures and underlying bony erosion of nasal base of the maxillary alveolus can be seen on CT.<sup>[4]</sup> Magnetic resonance imaging findings of the nasolabial cysts include a sharply marginated cyst with hypointensity on T1-weighted images and hyperintensity on T2-weighted images.<sup>[5]</sup> The CT and MRI scans in this study revealed that apocrine hidrocystoma in this area is comparable with nasolabial cyst in radiological aspects. It also presented in a similar manner to the more common nasolabial cyst. Apparently, differentiation between the nasolabial cyst and apocrine hidrocystoma in the nasolabial fold has to be verified by histological examination. The wall of the nasolabial cyst is lined by squamous, columnar or pseudostratified epithelium or a combination of these with scattered goblet cells. Whereas, an apocrine hidrocystoma consists of secretory cells showing the typical evidence of decapitation secretion, the pathognomonic finding of apocrine differentiation. In addition, fibrous connective tissue under the epithelium of the nasolabial cyst is attached to the surrounding muscle tissue. The histopathological differential diagnosis includes also eccrine hidrocystoma. Apocrine hidrocystomas are differentiated from eccrine hidrocystomas by the presence of decapitation secretion in ductal cells.

Hidrocystomas rarely exceed 20 mm.<sup>[1,2]</sup> We described an apocrine hidrocystoma that reached a relatively large 3 cm size located beneath the right alar base without causing significant cosmetic deformity. The patient had not noticed swelling

on her face but complained of a gradual increase in nasal obstruction as an unusual symptom. It is presumed for such benign cysts in this region that expansion into the nasal cavity rather than the face makes them more likely to be left untreated.

The treatment of apocrine hidrocystoma is described in several case reports. The majority of investigators assume that successful management requires excision with removal of the cyst wall to prevent recurrence.<sup>[2,3]</sup> However, information concerning of this tumor located in nasolabial region is not sufficient in literature. Only one case 2 cm in diameter in the nasolabial region excised via a Weber-Ferguson incision was described by Armstrong et al.<sup>[3]</sup> Our patient was treated by an sublabial approach. The lesion was easily released from the bone, skin and the undersurface of the nasal mucosa and they were removed intact. Although it was a giant tumor, the approach to the mass did not require an external incision. In our opinion, the intraoral approach seems to be an effective and sufficient treatment option for uncomplicated cases of apocrine hidrocystoma in this region.

In conclusion, our case of a giant apocrine hidrocystoma of the maxilla presented in a similar manner to the more common nasolabial cyst in radiological and clinical aspects. In this case, total excision by a narrow margin via a sublabial approach enabled complete resolution.

#### Declaration of conflicting interests

The authors declared no conflicts of interest with respect to the authorship and/or publication of this article.

#### Funding

The authors received no financial support for the research and/or authorship of this article.

#### REFERENCES

1. Anzai S, Goto M, Fujiwara S, Da T. Apocrine hidrocystoma: a case report and analysis of 167 Japanese cases. *Int J Dermatol* 2005;44:702-3.
2. Vashi N, Mandal R. Giant multi-loculated apocrine hidrocystomas. *Dermatol Online J* 2010;16:16.
3. Armstrong AP, Lavery KM, Hollingsworth T. Apocrine hidrocystoma: report of a case. *Br J Oral Maxillofac Surg* 1996;34:335-7.
4. Choi JH, Cho JH, Kang HJ, Chae SW, Lee SH, Hwang SJ, et al. Nasolabial cyst: a retrospective analysis of 18 cases. *Ear Nose Throat J* 2002;81:94-6.
5. Curé JK, Osguthorpe JD, Van Tassel P. MR of nasolabial cysts. *AJNR Am J Neuroradiol* 1996;17:585-8.