

Incidentally detected asymptomatic metal foreign bodies (two nails) in shoemaker's maxillary sinus

Bir kunduracının maksiler sinüsünde tesadüfen saptanan asemptomatik metal yabancı cisimler (iki çivi)

Murat Enöz, M.D.,¹ Fırat Selvi, M.D.,² Hasan Mete İnançlı, M.D.,³
Osman Sami Katırcıoğlu, M.D.,⁴ Muhammet Acar, M.D.⁵

¹Department of Otolaryngology, Special Yenibosna Safa Hospital, İstanbul, Turkey;

²Department of Oral and Maxillofacial Surgery, Faculty of Dentistry, İstanbul University, İstanbul, Turkey;

³Department of Otolaryngology, Ankara Oncology Training and Research Hospital, Ankara, Turkey;

⁴Department of Otolaryngology, İstanbul Medicine Faculty of İstanbul University, İstanbul, Turkey;

⁵Department of Radiology, Special Yenibosna Safa Hospital, İstanbul, Turkey

The diagnosis metal foreign bodies of maxillary sinus cannot be usually made in an acute setting and patients may present with chronic symptoms due to drainage and chronic irritation of the mucosa years later. Metal foreign bodies can be generally displaced to the maxillary sinus at the time of dental intervention. In this article, we report a very interesting case of 23-year-old male shoemaker with two metal foreign bodies (nails) which were non-related with any surgical intervention or trauma and found incidentally in the right maxillary sinus.

Key Words: Maxillary sinus; metal foreign body; nail; shoemaker.

Maksiller sinüsteki yabancı cisimlerin tanısı çoğunlukla ilk değerlendirme esnasında konulamaz ve hastalar yıllar sonra ortaya çıkan drenaj ve mukoza-daki kronik iritasyona bağlı semptomlar ile kendini gösterir. Metal yabancı cisimler genellikle dental girişimler esnasında maksiller sinüs içerisine kaçarak yerleşir. Bu yazıda, herhangi bir cerrahi girişim veya travmaya bağlı olmayan, tesadüfen sağ maksiller sinüs içerisinde iki adet metal yabancı cisim (çivi) saptanan 23 yaşındaki erkek ayakkabı işçisi olan çok ilginç olgu sunuldu.

Anahtar Sözcükler: Maksiller sinüs; metal yabancı cisim; çivi; ayakkabı işçisi.

Foreign bodies generally cause iatrogenic sinusitis by interrupting mucociliary clearance or causing a tissue reaction.^[1-3] The symptoms of iatrogenic chronic sinusitis due to foreign bodies are often nonspecific. The maxillary sinus is the most commonly affected among paranasal sinuses; other

sinuses can be affected with spreading infection ultimately causing pansinusitis.^[1-6] Metal foreign bodies in the maxillary sinus that may originate from dental intervention include amalgam,^[2] dental implants,^[2,3] dental burs^[6] and silver points.^[4] Other metal foreign bodies usually result from facial

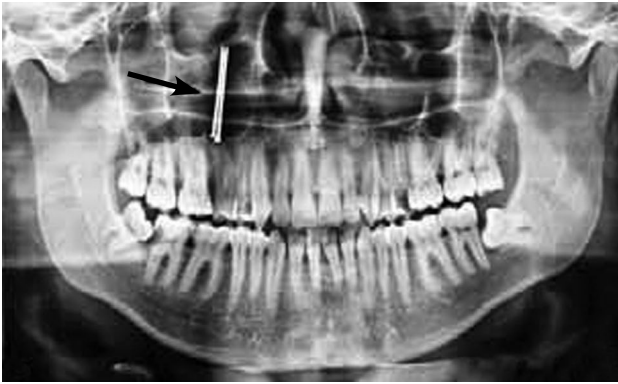

Figure 1. Metal foreign bodies (two nails) embedded behind anterior wall of right maxillary sinus seen on a paranasal digital X-ray (black arrow).

trauma.^[7] In addition, fungal infections or even cancer can be caused by such foreign bodies.^[8]

This is the first case in the literature of a shoemaker with asymptomatic maxillary sinus metal foreign bodies (two nails) unrelated to any surgical intervention or trauma.

CASE REPORT

A 23-year-old male was admitted to the Dentistry Department of Special Yenibosna Safa Hospital because of retromolar pain. He was referred to our Department of Otolaryngology Head and Neck Surgery because of metal foreign bodies on his panoramic radiograph (Figure 1). There was no recollection of any event, trauma or disease in

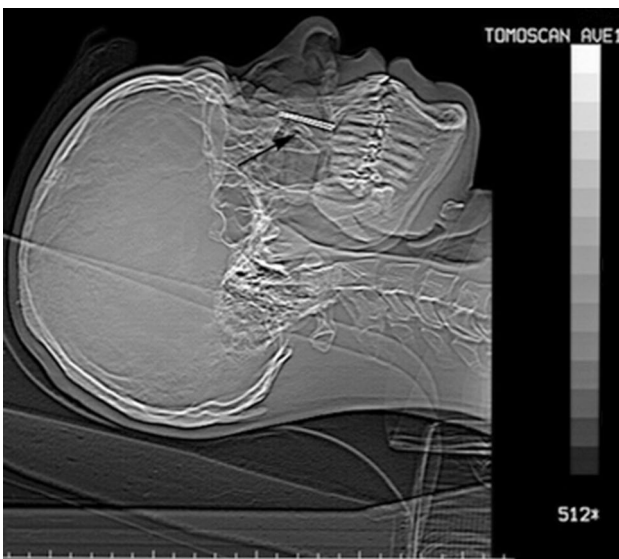


Figure 2. Metal foreign bodies (two nails) embedded behind anterior wall of right maxillary sinus seen on lateral cranial digital X-ray (black arrow).

his medical history. The left inferior turbinate was hypertrophic on rhinoscopic examination. Nasal endoscopic examination did not reveal any sign of sinusitis. Complete blood count was normal. A paranasal sinus X-ray revealed the presence of metal foreign bodies embedded behind the anterior wall of the right maxillary sinus, from the tooth root to the lower orbital wall (Figure 2-6). A previous consult was made with his dentist who suspected that the foreign bodies in the right maxillary sinus were two nails about 3 cm long, with the pointed ends facing upwards (Figure 1-6). The patient was forwarded to İstanbul University Faculty of Dentistry Department of Oral and Maxillofacial Surgery for further treatment and the removal of metal foreign bodies. The metal nails were removed with a transantral (Caldwell-Luc) approach under sedation anesthesia (Figure 7, 8). The postoperative three-month follow-up was uneventful.

DISCUSSION

The penetration into the maxillary sinus by metallic foreign bodies are usually due to trauma or dental intervention.^[1-6] The diagnosis in a patient with symptoms of unilateral chronic sinusitis can

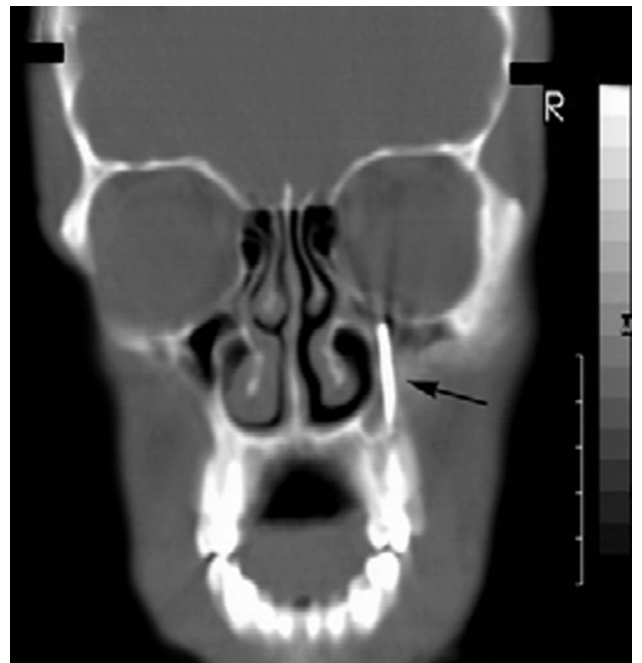


Figure 3. Metal foreign bodies (two nails) embedded behind anterior wall of right maxillary sinus, from the tooth root to the lower orbital wall seen on coronal section paranasal sinus computed tomography scan (black arrow). Left middle middle and inferior turbinates are seen as hypertrophic.

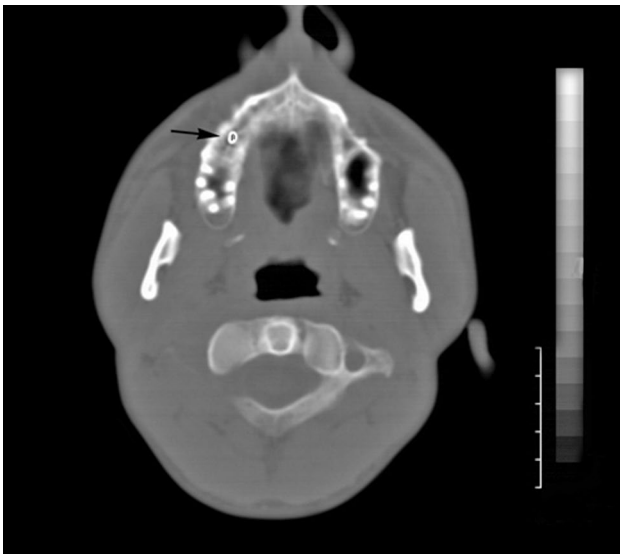


Figure 4. Metal foreign bodies (heads of two nails) in right posterior premolar tooth root seen on axial section paranasal sinus computed tomography scan (black arrow).

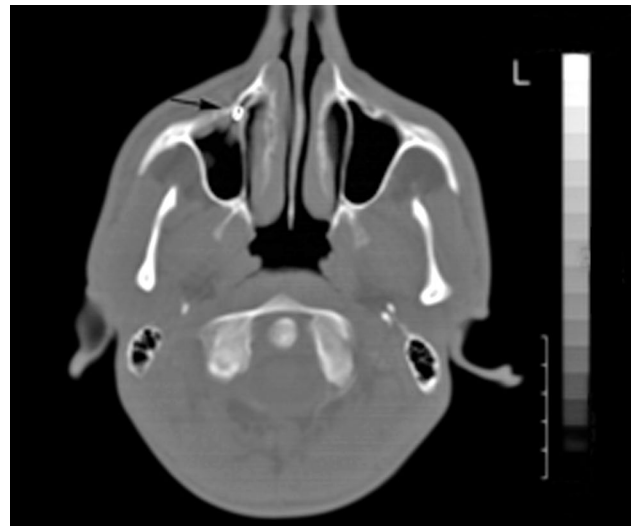


Figure 5. Metal foreign bodies (two nails) embedded behind anterior wall of right maxillary sinus and contact thickening of mucosa seen on axial paranasal sinus computed tomography scan (black arrow). Note hypertrophic left inferior turbinate.

be made by history, careful clinical examination and appropriate radiographs. Orthopantomogram together with the Waters' and lateral skull views are useful.^[9] However in our case, there is no suggestive history of foreign body or symptom of unilateral sinusitis. The involvement of other sinuses requires computed tomography scans to determine the presence of any foreign body.^[1-3,5,6] Functional endoscopic sinus surgery and/or Caldwell-Luc sinus exploration can provide more information.^[1-6]

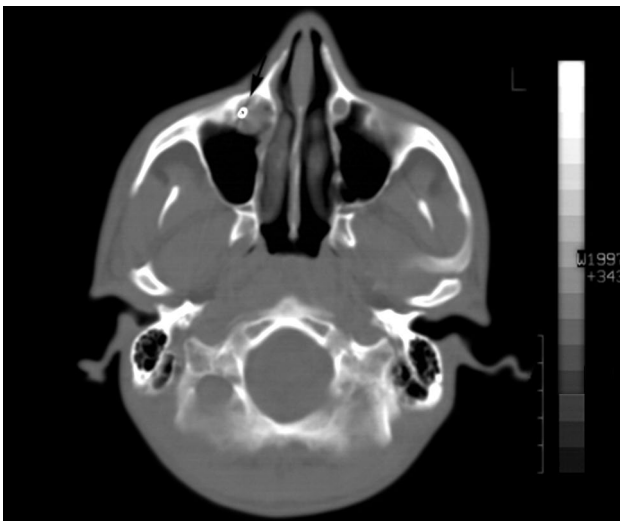


Figure 6. Metal foreign bodies (two nails) embedded behind anterior wall of right maxillary sinus and mucosal cyst are seen on an axial paranasal sinus computed tomography scan (black arrow).

The information about toxicologic points and features of amalgam,^[2,9] dental implants,^[2,3] dental burs^[6] and silver points^[4] can be found in the literature but we didn't find any information about metal nails used by shoe workers and their tissue toxicity or harmful effects. In our case, thickening of the sinus mucosa (Figure 5) and mucosal cyst (Figure 6) on its contact area were found on paranasal sinus computed tomography scan (PNSCT) despite absence of patient's complaints.

Surgical removal of metallic foreign bodies of dental origin or trauma is generally preferred because of mercury leakage, mucosal reaction,

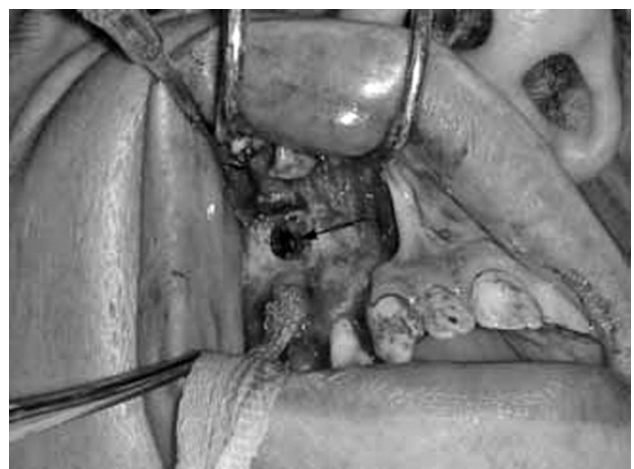

Figure 7. Metal nails behind right maxillary sinus anterior wall (black arrow).

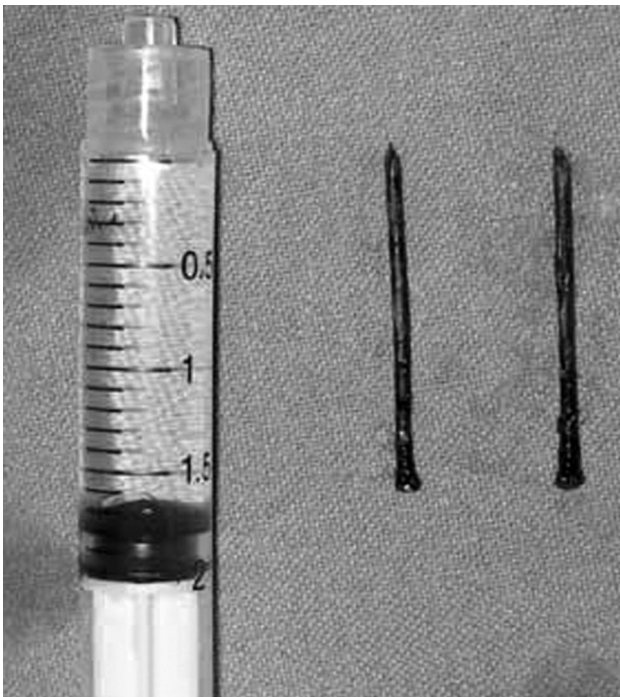


Figure 8. Nails and syringe (for size comparison).

sinusitis and spreading of infections resistant to conservative treatment.^[1-3,6-9]

In our case, a complete mechanism for entry of the foreign bodies could not be clearly understood as there was no history of trauma or dental intervention. They possibly entered the maxillary sinus when milk teeth were first shed as he first started to learn his trade at the age of six. Shoe workers in Turkey generally keep the nails with their lips to speed crash them. These habits of shoe workers may cause to entry of nails into the maxillary sinus from the roots of the teeth when his milk teeth were shed. Our search of the literature

did not reveal any other case of asymptomatic maxillary sinus metal nails.

This case highlights that nails in the maxillary sinus can be found incidentally in shoe workers and they may remain asymptomatic for many years.

Declaration of conflicting interests

The authors declared no conflicts of interest with respect to the authorship and/or publication of this article.

Funding

The authors received no financial support for the research and/or authorship of this article.

REFERENCES

1. Peric´ B, Macan D, Kobler P. Sinusitis caused by maxillary sinus foreign body. (Eng. Abs.). Acta Stomatol Croat 1995;29:185-8.
2. Scorticati MC, Raina G, Federico M. Cluster-like headache associated to a foreign body in the maxillary sinus. Neurology 2002;59:643-4.
3. Selvi F, Enoz M, Yazgin I, Cakarar S, Keskin C. Do asymptomatic foreign bodies in the maxillary sinus always need to be removed? B-ENT 2008;4:243-7.
4. El Charkawi HG, El Askary AS, Ragab A. Endoscopic removal of an implant from the maxillary sinus: a case report. Implant Dent 2005;14:30-5.
5. Abe K, Beppu K, Shinohara M, Oka M. An iatrogenic foreign body (dental bur) in the maxillary antrum: a report of two cases. Br Dent J 1992;173:63-5.
6. Fan VT, Korvi S. Sewing needle in the maxillary antrum. J Oral Maxillofac Surg 2002;60:334-6.
7. Kobayashi A. Asymptomatic aspergillosis of the maxillary sinus associated with foreign body of endodontic origin. Report of a case. Int J Oral Maxillofac Surg 1995;24:243-4.
8. Selmani Z, Ashammakhi N. Surgical treatment of amalgam fillings causing iatrogenic sinusitis. J Craniofac Surg 2006;17:363-5.