

**How to do it?****Nasıl yapılır?**

## Nasal reconstruction by modified bilobed forehead flap

### Modifiye bilobe alın flebi ile nazal rekonstrüksiyon

Ercan Akbay, M.D., Yaşar Çokkeser, M.D., Emre Karaoğlu, M.D.

*Department of Otolaryngology, Medical Faculty of Mustafa Kemal University, Hatay, Turkey*

Paramedian forehead flaps, which are supplied by supratrochlear artery and have structural compatibility with nasal skin, have been successfully used for nasal reconstruction for many years. However, removing this flap from midline as perpendicular to natural lines of forehead may lead to marked scar. A flap extending to lateral in parallel to natural lines of forehead results in ipsilateral elevation of eyebrow. In this article, we aimed to demonstrate a flap technique called as "modified bilobed forehead flap technique". In this technique, pedicle of the flap is supplied by supratrochlear artery at one side and the flap is removed at the contralateral side of the lesion using parallel incision to natural lines of forehead. Another flap with a half thickness of the original flap is removed from contralateral frontal region and interpolated to the site where the original flap is removed to prevent the asymmetrical elevation of eyebrow ipsilateral to flap removal. The aim of this technique is to utilize masking effect of natural lines of forehead, while the basic method is bilobed flap technique. Secondary benefits of this technique include forehead lifting and bilateral eyebrow lifting.

**Key Words:** Bilobed flap; forehead flap; nasal reconstruction; supratrochlear artery.

Supratroklear arterden beslenen ve yapı olarak burun cildiyle uyum gösteren paramedian alın flepleri, nazal rekonstrüksiyon amacıyla uzun yıllardır başarıyla kullanılmaktadır. Ancak, bu flebin alın çizgilerine dik olarak orta hattan kaldırılması belirgin bir skara neden olabilmektedir. Alın çizgilerine paralel olarak laterale uzanan bir flep ise, aynı tarafta kaşın asimetric olarak kalkmasıyla sonuçlanır. Bu yazıda "modifiye bilobe alın flebi tekniği" olarak adlandırılan bir flep tekniğini göstermeyi amaçladık. Bu teknikte flep sapı bir tarafın supratroklear arterinden beslenir ve lezyonun karşı tarafında alın çizgilerine paralel insizyonla kaldırılır. Flebin kaldırıldığı sahada kaşın asimetric olarak kalkmasını engellemek amacıyla, karşı frontal bölgeden ilk kaldırılan flebin yarısı kalınlığında bir başka flep ilk kaldırılan flebin yerine rotasyonel olarak çevrilir. Bu tekniğin temel amacı, alın çizgilerinin kamuflaj etkisini kullanmak; temel yöntemi ise, bilobe flep tekniğidir. Alnın gerilmesi ve kaşların iki taraflı kalkması ise bu tekniğin sekonder kazançlarıdır.

**Anahtar Sözcükler:** Bilobe flep; alın flebi; nazal rekonstrüksiyon; supratroklear arter.

Forehead flaps have long been successfully used in nasal reconstruction. These flaps are used in the reconstruction of large nasal defects due to their

good blood supply and structural compatibility to nasal skin.<sup>[1,2]</sup> Paramedian forehead flaps supplied by the supratrochlear artery are vertically raised

along the midline and interpolated to defective nasal areas. Removal of this flap in a manner that is perpendicular to natural forehead creases causes a remarkable scar. However, there is physical difficulty in the interpolation of a pediculated flap removed parallel to natural forehead creases at the midline. Again, a flap supplied by midline but extending laterally parallel to natural forehead creases will result in asymmetric elevation of the ipsilateral eyebrow. In this setting, we use a modified bilobed forehead flap.

### SURGICAL TECHNIQUE

The operation is performed under general or local anesthesia in adult patients. The pedicle of the flap used in nasal reconstruction is supplied by the supratrochlear artery in the same side as the lesion. It is raised by incising parallel to natural forehead creases at the contralateral side (Figure 1). Another flap half the thickness of the original flap is raised from the frontal region by parallel incision to natural forehead creases in order to prevent asymmetrical elevation of the contralateral eyebrow and to close the area with minimal tension (Figure 2 and 3). The area where the second flap is raised from is closed with primary sutures, while the lobe of the second flap is sutured to the area from where the original flap is raised (Figure 4). A satisfying result obtained in the postoperative period is shown (Figure 5). The supratrochlear artery is based in the original flap used in nasal reconstruction. The second lobe of the flap is supplied in relation to the first lobe. As the blood supply of the forehead and face is

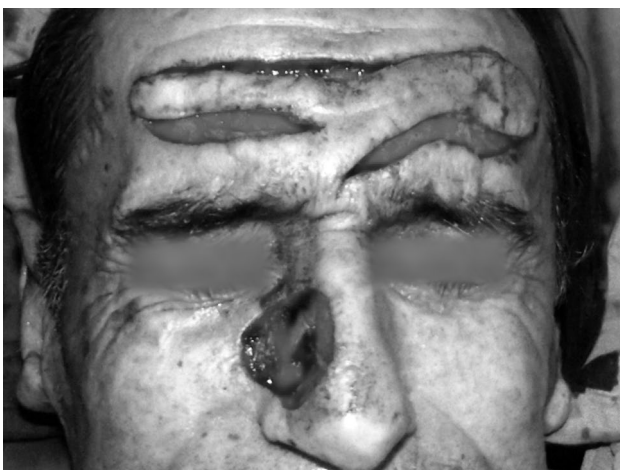sufficient, no flap necrosis was observed and the flap pedicle was excised after postoperative day 15.

### DISCUSSION

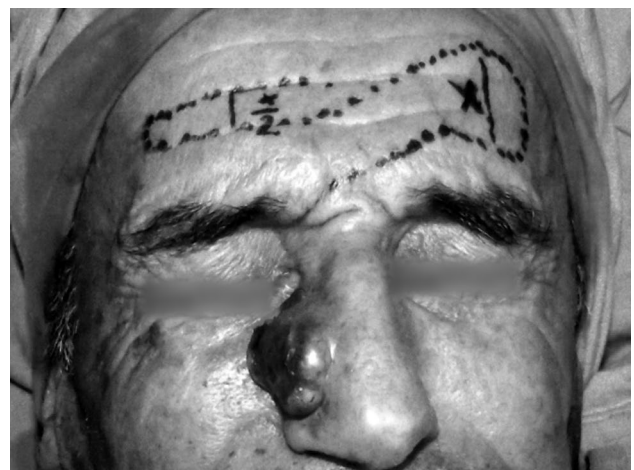
The nose is a complex organ which consists of mucosa and columnar epithelium inside, soft tissue, cartilage and skeletal structure in the middle layer and skin encompassing all the above-mentioned structures on the outer side.

Nasal tissue defects commonly result from trauma or resection of skin tumors. Several techniques have been defined in the reconstruction of nasal skin for years. Small defects are repaired by local or nasolabial flaps, while forehead flaps may be used in larger defects.<sup>[2,3]</sup> Paramedian forehead flaps achieve near-natural aesthetic and functional outcome in the reconstruction of large external and internal nasal defects.<sup>[4]</sup> In these flaps, the crucial point is the blood supply (supratrochlear artery and vein) and flap width.<sup>[5]</sup> Forehead flaps are interpolated to the nasal region with the supplying artery in one- or two-stage processes and the donor defect is primarily closed.<sup>[6]</sup>

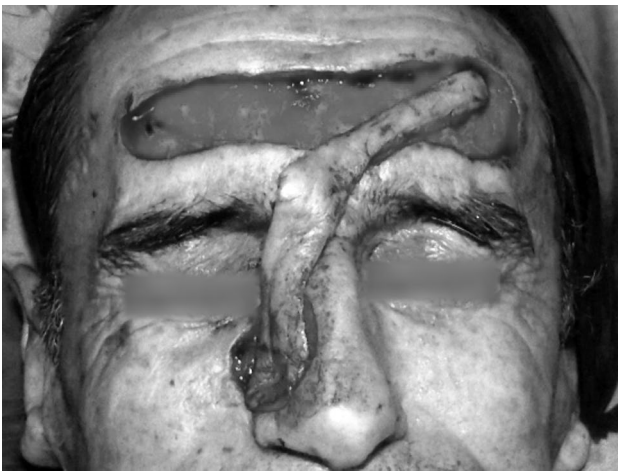The supratrochlear artery is the dominant blood source in current forehead flaps. Thus, it is essential to know and preserve the anatomy of the supratrochlear artery. It leaves the orbit approximately 2 cm lateral to midline. It has a profound course in orbital and frontal muscles, while it superficially travels in the corrugator muscle. Then, it penetrates the frontal muscle medial to the eyebrow and projects in a subcutaneous plane.<sup>[7]</sup> Although all of the forehead



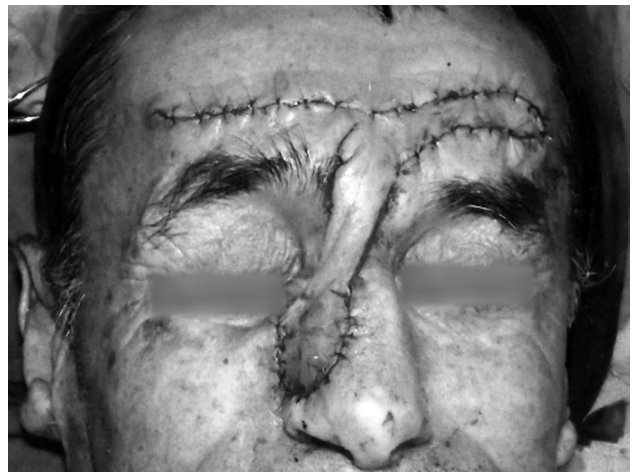**Figure 1.** Flap of interest is removed at the contralateral side of nasal defect by parallel incisions to natural forehead creases in a full-thickness manner.



**Figure 2.** Another flap is removed at the contralateral side half the thickness of the original flap to prevent asymmetrical elevation of eyebrows.



*Figure 3. Second flap is sutured to the area from where the original flap was raised.*



*Figure 4. Area is primarily sutured from where the second flap was raised, while it is sutured to the area from where the original flap was raised.*

paramedian flaps lie in the vertical plane, in the described modification using our technique, the flap handle with some part of the flap remains in the vertical plane. On the other hand the wings extending laterally remain transverse. Nourishment of these transverse wings is by random capillary circulation from the flap pedicle. Because of this reason this flap technique is named as a modification. Sufficient vascularity of the head and neck region provides flap wings with nutrition opportunity. As it would be seen from the postoperative image, good results and no flap necrosis were observed.

In flaps used for nasal reconstruction, to improve cosmetic success, defect and donor areas should have similar characteristics; flap thickness

should be compatible to the defect; and the donor area should be primarily closed. In the forehead, flap incision parallel to horizontal forehead creases provides more aesthetic outcomes, as it masks postoperative incision scars. In our technique, it is thought that these criteria can easily be met and a high level of cosmetic gain achieved.

In this technique, the pedicle of the flap is supplied by the supratrochlear artery and it is removed by parallel incisions to natural forehead creases at the contralateral side. Another flap half the thickness of the original flap is removed from the contralateral frontal region by parallel incision and the latter flap is sutured to the area from where the original flap was raised in order to prevent asymmetrical elevation of eyebrows.

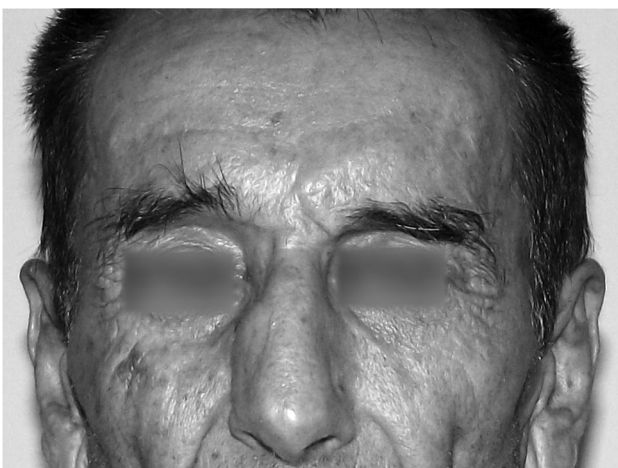
The primary aim of this technique is to utilize the masking effect of natural forehead creases and the basic technique is the bilobed flap principle. However, secondary gains are tightening of forehead and bilateral elevation of eyebrows. The bilobed forehead flap should be kept in mind when a forehead flap is preferred for nasal reconstruction.

#### **Declaration of conflicting interests**

The authors declared no conflicts of interest with respect to the authorship and/or publication of this article.

#### **Funding**

The authors received no financial support for the research and/or authorship of this article.



*Figure 5. At the end of the first year an acceptable result was obtained.*

### REFERENCES

1. Çakmak Ö, Özlüoğlu L. Burun rekonstrüksiyonunda paramedian alın flebi kullanımı. KBB ve BBC Dergisi 2000;8:139-42.
2. Alagöz MS, İşken T, Sen C, Onyedi M, İzmirli H, Yücel E. Three-dimensional nasal reconstruction using a prefabricated forehead flap: case report. Aesthetic Plast Surg 2008;32:166-71.
3. Barton FE, Byrid HS. Acquired deformities of the nose. In: McCarthy JG, editor. Plastic surgery. Philadelphia: Saunders; 1990. p. 1924-2008.
4. Viksraitis S, Maslauskas K, Bagdonas R. Reconstruction of nasal defect with the composite expanded forehead flap. Medicina (Kaunas) 2010;46:34-7.
5. Eskiizmir G, Hırçın Z, Ünlü HH. Paramedian alın flebi tasarımı için pratik bir metod: ön çalışma. Türkiye Klinikleri J Med Sci 2010;30:1210-3.
6. Fudem GM, Montilla RD, Vaughn CJ. Single-stage forehead flap in nasal reconstruction. Ann Plast Surg 2010;64:645-8.
7. Shumrick KA, Smith TL. The anatomic basis for the design of forehead flaps in nasal reconstruction. Arch Otolaryngol Head Neck Surg 1992;118:373-9.